



PATIENT

Norman Difeo

SPECIES

Canine

BREED

Dachshund

SEX

Neutered Male

AGE

11 Years 10 Months

WEIGHT

15.4 lbs

INTERPRETED BY

Eric Lindquist, DMV,
DABVP (CFM), Cert.
IVUSS

IMAGING PERFORMED BY

Kerri Becker

HOSPITAL NAME

Animal Paradise
Hospital

REFERRING VET

Dr. Elshafie

INVOICE

74695

DATE

4/22/26

PRESENTING CLINICAL SIGNS

Elev. liver and Ca values. HM 4/6. PT was dx w/ HDZ stage B2. On vetmedin, HDZ stable. AUS assessment of liver. HX UA calculi.

Abnormal PE/Chem/CBC/UA Results: BW from Jan 2026 alp-274 alt-158 ca-12.1 rbc-9.87 hgb-21

ULTRASONOGRAPHIC EXAMINATION OF THE HEART & ABDOMEN

CANINE CARDIAC PARAMETERS	MR VMAX (m/s)	TR VMAX (m/s)	LA/AO (M-Mode)	LA/AO (Heart Base; Swe)	FS (%)	EF (%)	EPSS (cm)
NORMAL PARAMETER	4.5-5.5	<2.7	1.3	Up to 1.6	28-40	40-100	<0.6
PATIENT	--	--	1.4	1.6	50	90	0.1
CANINE CARDIAC PARAMETERS	HR (BPM)	AV VMAX (m/s)	PV MAX (m/s)	BODY WEIGHT (lbs)	LAD LA MAX 4 Chamber	LVIDd Avg; 2D and m-mode short axis (cm)	LVIDs Avg; 2D and m-mode short axis (cm)
NORMAL PARAMETER	50-100	0.7-1.7	0.7-1.6				
PATIENT	80	1.7	0.7	15.4	3.3	3.2	--

Cardiac Presentation

The **left atrium** presented similar size as on the prior sonogram with mild left atrial enlargement. **Mitral** insufficiency noted. The **left ventricle** presented thicknesses with linear contour and was not dilated nor restricted. The **myocardium** presented normal echogenicity without subjective evidence of significant fibrotic or ischemic disease. **Contractility** of the ventricular walls was adequate and in normal range for this patient evidenced by the fractional shortening measurement and subjective evaluation of the different regions of the myocardium. The **left ventricular outflow** tract demonstrated normal laminar flow and subjective structural integrity. The **right atrium** and auricle revealed normal size, structure and content. No evidence of masses was noted. **Tricuspid** valvular assessment demonstrated adequate linear morphology and kinesis. The **right ventricle** was of normal size (1/3 diameter of LV), chordae structure, myocardial echogenicity and thickness. **Pulmonary outflow** tract assessment revealed normal valve structure, laminar flow, and diameter (approx. 1:1 pa/ao ratio). No visible **pericardial** or free pleura fluid was noted. The cranial **mediastinum and pericardial and extra-cardiac regions** were free of masses in the visible window.

Urinary System

The **urinary bladder** revealed multiple small calculi, non-obstructive. The bladder was otherwise unremarkable.

The **kidneys** revealed largely normal size and structure, corticomedullary definition and ratio (cortex 1/3 of medulla) were essentially maintained with some age-related loss of curvilinear patterns regarding the capsule and C/M junction. The cortices presented largely uniform texture with some increased



PATIENT

Norman Difeo

echogenicity expected for his age patient. Medullary structure differed distinctly from that of the cortex and no evidence of pelvic dilation was present. Calculi noted in both kidneys. The right kidney measured 4.91 cm. The left kidney measured 4.74 cm.

SPECIES

Canine

Adrenal Glands

Both **adrenal glands** were visualized and recognized as having normal shape, size, position and echogenicity for this breed. The phrenic vasculature, glandular echogenicity and detail were unremarkable. Capsule, cortex, and medullary definition were normal for this age patient. Right measured 1.38 cm x 0.77 cm at the cranial pole and 0.52 cm at the caudal pole. Left measured 2.05 cm x 0.54 cm at the cranial pole and 0.66 cm at the caudal pole.

BREED

Dachshund

SEX

Neutered Male

Spleen

The **spleen** presented a smooth homogeneous parenchyma hyperechoic to liver and renal cortical parenchyma. The capsule was smooth without noticeable expansion or deviation from within the spleen or adjacent pathology. The splenic vasculature demonstrated normal volume without signs of congestion or thrombosis. No sonographic evidence of acute or chronic inflammatory, neoplastic, or infarctual changes were noted.

AGE

11 Years 10 Months

WEIGHT

15.4 lbs

Liver

The **liver** images submitted revealed subjectively normal liver size, contour, and structure. Parenchymal echogenicity was naturally coarse and hypoechoic to the spleen. Vascular and biliary tracts were of normal volume with no evidence of congestion. The gallbladder presented acceptably thin walls with primarily anechoic content. The cystic and common bile ducts were normal. No pathological hepatic lymphadenopathy was evident. No overt structural evidence of inflammatory, infiltrative or regenerative pathology was evident.

INTERPRETED BY

Eric Lindquist, DMV,
DABVP (CFM), Cert.
IVUSS

Gastrointestinal

Examination of the **gastrointestinal tract** revealed a stomach and intestine free of stasis, of normal wall thickness, acceptable curvilinear mural detail, and peristaltic activity. Small and large intestine demonstrated normal luminal chyme and stool consistency respectively. No obstructive or overt infiltrative disease was noted. No associated abnormal lymphatic activity was noted.

IMAGING PERFORMED BY

Kerri Becker

Pancreas

The base and limbs of the **pancreas** were observed to be largely isoechoic to surrounding omental fat. Pancreatic duct and capsular contour were acceptably normal and parenchyma respected normal curvilinear patterns. No overt evidence of active inflammatory or neoplastic disease was noted.

HOSPITAL NAME

Animal Paradise
Hospital

REFERRING VET

Dr. Elshafie

ULTRASONOGRAPHIC FINDINGS

- Mild persistent left atrial enlargement, fairly stable B2 valvular disease.
- Bladder and renal calculi, non-obstructive.

INVOICE

74695

INTERPRETATION OF THE FINDINGS & FURTHER RECOMMENDATIONS

DATE

4/22/26

Recommend adding ACE inhibitor at 0.5 mg/kg SID progressing to BID and continuing Pimobendan. There is mild anesthetic risk in this patient.



PATIENT

Norman Difeo

The patient is likely passing calculi from the kidneys to the bladder. Full urinary workup warranted with cystostomy, stone analysis and culture. However, the patient will likely pass calculi periodically from the kidneys to the bladder. These are likely calcium oxalate calculi.

SPECIES

Canine

BREED

Dachshund

SEX

Neutered Male

AGE

11 Years 10 Months

WEIGHT

15.4 lbs

INTERPRETED BY

Eric Lindquist, DMV,
DABVP (CFM), Cert.
IVUSS

IMAGING PERFORMED BY

Kerri Becker

HOSPITAL NAME

Animal Paradise
Hospital

REFERRING VET

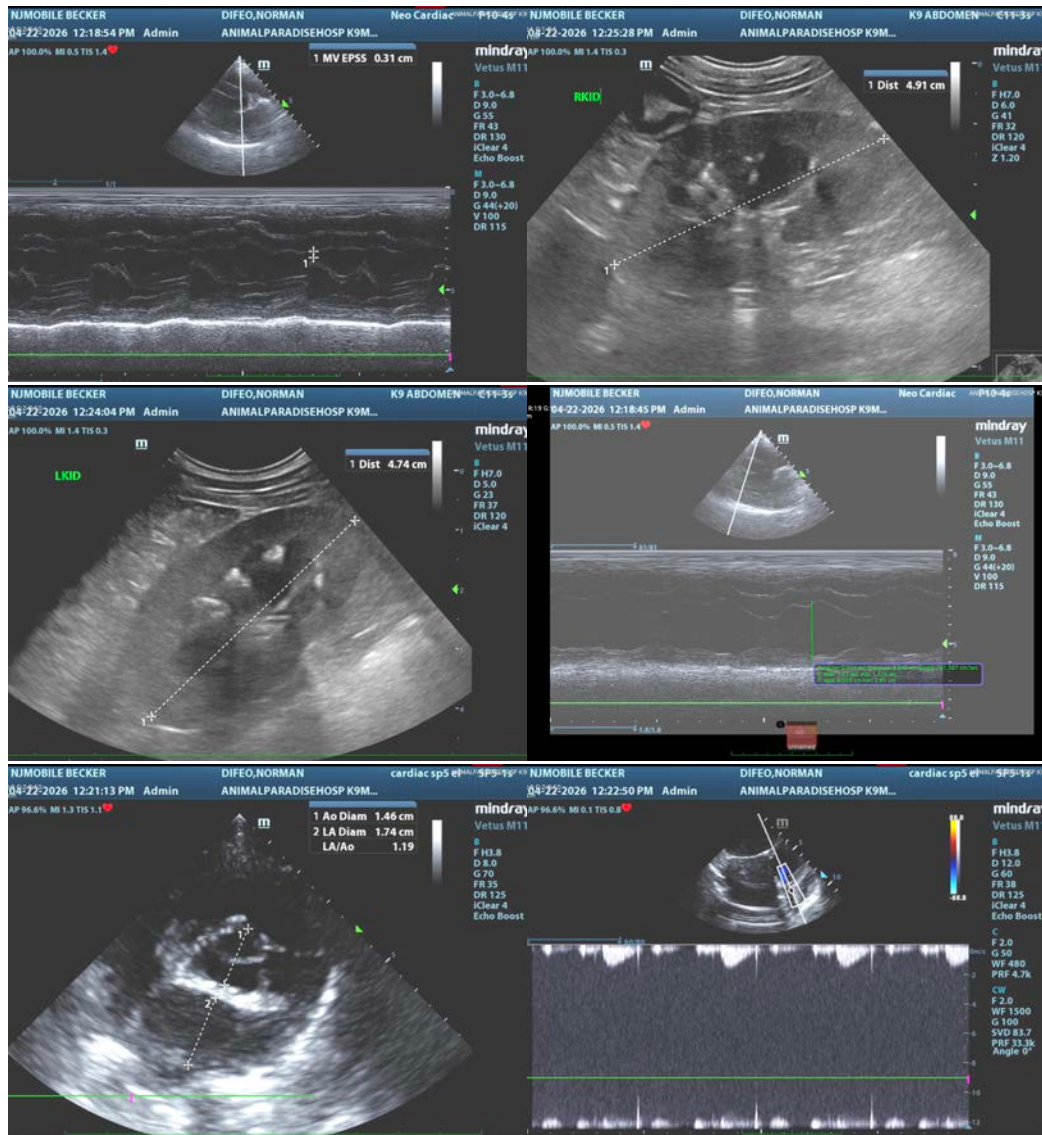
Dr. Elshafie

INVOICE

74695

DATE

4/22/26





PATIENT

Norman Difeo

SPECIES

Canine

BREED

Dachshund

SEX

Neutered Male

AGE

11 Years 10 Months

WEIGHT

15.4 lbs

INTERPRETED BY

Eric Lindquist, DMV,
 DABVP (CFM), Cert.
 IVUSS

IMAGING PERFORMED BY

Kerri Becker

HOSPITAL NAME

Animal Paradise
 Hospital

REFERRING VET

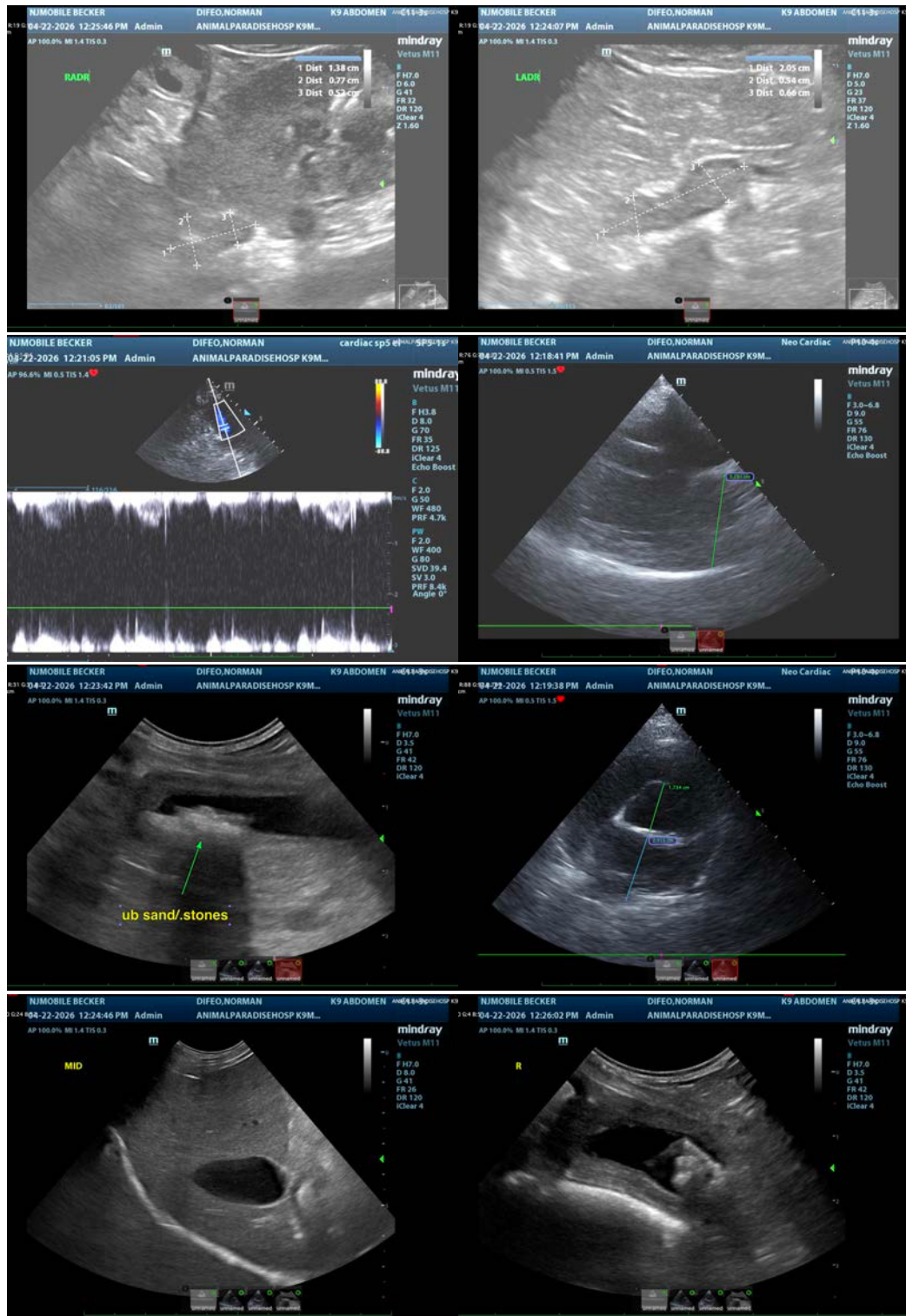
Dr. Elshafie

INVOICE

74695

DATE

4/22/26





PATIENT

Norman Difeo

The information and recommendations provided are based on the images presented by the referring veterinarian/sonographer. No evaluation can be communicated regarding pathology that was not visible in the image/video clips provided.

SPECIES

Canine

Thank you for this referral. If the clinical or image interpretation does not parallel your findings or if I can be of any further assistance please contact me.

BREED

Dachshund

Eric Lindquist, DMV, DABVP(CFM), Cert. IVUSS,
CEO, Owner, Founder -- SonoPath.com
info@SonoPath.com

SEX

Neutered Male

AGE

11 Years 10 Months

WEIGHT

15.4 lbs

INTERPRETED BY

Eric Lindquist, DMV,
DABVP (CFM), Cert.
IVUSS

IMAGING PERFORMED BY

Kerri Becker

HOSPITAL NAME

Animal Paradise
Hospital

REFERRING VET

Dr. Elshafie

INVOICE

74695

DATE

4/22/26