



PATIENT

Hemi VonGlahn

SPECIES

Canine

BREED

Labrador Retriever

SEX

Neutered Male

AGE

11 Years 8 Months

WEIGHT

76 lbs

INTERPRETED BY

Eric Lindquist, DMV,
DABVP (CFM), Cert.
IVUSS

IMAGING PERFORMED BY

Chloe Lowe, CVT

HOSPITAL NAME

Andover Animal
Hospital

REFERRING VET

Dr. Kotb

INVOICE

74700

DATE

4/22/26

PRESENTING CLINICAL SIGNS

Repeatable abdominal pain on palpation and signs of discomfort at home. Random urinary incontinence. Strong flinch / pain response to palpation of mid/caudal abdomen on PE.

Abnormal PE/Chem/CBC/UA Results: Pending

ULTRASONOGRAPHIC EXAMINATION OF THE ABDOMEN

Urinary System

The **urinary bladder**, trigone, and pelvic urethra presented normal thicknesses and normal tone. The ureters were not visible which is normal. No uroliths or sediment were visualized and anechoic urine was present. No evidence of inflammatory or neoplastic changes were noted. Ureteral papillae were normal. The pelvic urethra was imaged 2.0 cm beyond the cystourethral junction.

The **kidneys** revealed largely normal size and structure, corticomedullary definition and ratio (cortex 1/3 of medulla) were essentially maintained with some age-related loss of curvilinear patterns regarding the capsule and C/M junction. The cortices presented largely uniform texture with some increased echogenicity expected for his age patient. Medullary structure differed distinctly from that of the cortex and no evidence of pelvic dilation was present. Left kidney measured 5.1 cm. Right kidney measured 5.6 cm.

Adrenal Glands

The **right adrenal gland** was visualized and recognized as having normal shape, size, position and echogenicity for this breed. The phrenic vasculature, glandular echogenicity and detail were unremarkable. Capsule, cortex, and medullary definition were normal for this age patient. The right adrenal gland measured 2.64 cm x 1.6 cm at the cranial pole and 0.59 cm at the caudal pole.

The **left adrenal gland** presented slight swelling at the cranial pole. The left adrenal gland measured 9.48 cm x 0.95 cm at the cranial pole and 0.56 cm at the caudal pole.

Spleen

The **spleen** presented a smooth homogeneous parenchyma hyperechoic to liver and renal cortical parenchyma. The capsule was smooth without noticeable expansion or deviation from within the spleen or adjacent pathology. The splenic vasculature demonstrated normal volume without signs of congestion or thrombosis. No sonographic evidence of acute or chronic inflammatory, neoplastic, or infarctual changes were noted.

Liver

The **liver** images from right and left intercostal as well as subcostal views revealed subjectively normal liver size, contour, and structure. Some age-related parenchymal remodeling was noted but likely not clinically significant at this time. Vascular and biliary tracts were of normal volume and no evidence of congestion was noted. The gallbladder presented some dependent debris with essentially normal contour. The cystic and common bile ducts were normal. No overt evidence of active inflammatory, infiltrative or regenerative pathology was noted but should be paired with current or past LE elevations regarding any clinical significance to this presentation. The hepatic lymph nodes were unremarkable.



PATIENT

Hemi VonGlahn

SPECIES

Canine

BREED

Labrador Retriever

SEX

Neutered Male

AGE

11 Years 8 Months

WEIGHT

76 lbs

INTERPRETED BY

Eric Lindquist, DMV,
 DABVP (CFM), Cert.
 IVUSS

IMAGING PERFORMED BY

Chloe Lowe, CVT

HOSPITAL NAME

Andover Animal
 Hospital

REFERRING VET

Dr. Kotb

INVOICE

74700

DATE

4/22/26

Gastrointestinal

Examination of the **gastrointestinal tract** revealed a stomach and intestine free of stasis, of normal wall thickness, acceptable curvilinear mural detail, and peristaltic activity. Small and large intestine demonstrated normal luminal chyme and stool consistency respectively. No obstructive or overt infiltrative disease was noted. No associated abnormal lymphatic activity was noted.

Pancreas

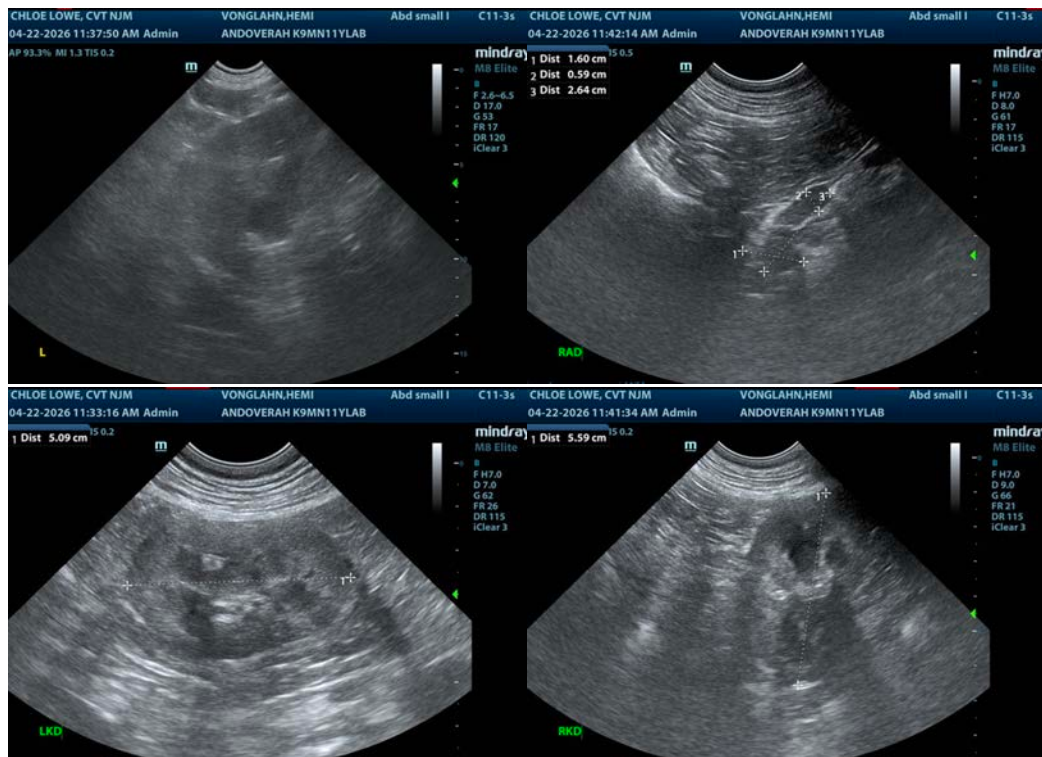
The base and limbs of the **pancreas** were observed to be largely isoechoic to surrounding omental fat. Pancreatic duct and capsular contour were acceptably normal and parenchyma respected normal curvilinear patterns. No overt evidence of active inflammatory or neoplastic disease was noted.

ULTRASONOGRAPHIC FINDINGS

- Slightly swollen left adrenal gland.
- Age related renal and hepatic changes.

INTERPRETATION OF THE FINDINGS & FURTHER RECOMMENDATIONS

Age related abdominal changes. There is no evidence of visceral disease responsible for any abdominal pain. Referred back pain should be considered as a potential.





PATIENT

Hemi VonGlahn

SPECIES

Canine

BREED

Labrador Retriever

SEX

Neutered Male

AGE

11 Years 8 Months

WEIGHT

76 lbs

INTERPRETED BY

Eric Lindquist, DMV,
DABVP (CFM), Cert.
IVUSS

IMAGING PERFORMED BY

Chloe Lowe, CVT

HOSPITAL NAME

Andover Animal
Hospital

REFERRING VET

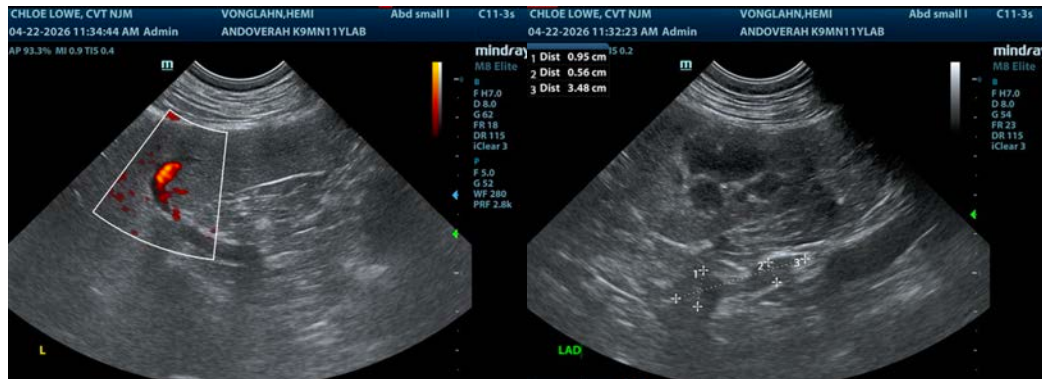
Dr. Kotb

INVOICE

74700

DATE

4/22/26



The information and recommendations provided are based on the images presented by the referring veterinarian/sonographer. No evaluation can be communicated regarding pathology that was not visible in the image/video clips provided.

Thank you for this referral. If the clinical or image interpretation does not parallel your findings or if I can be of any further assistance please contact me.

Eric Lindquist, DMV, DABVP(CFM), Cert. IVUSS,
CEO, Owner, Founder -- SonoPath.com
info@SonoPath.com