



PATIENT

Toby Marabello

PRESENTING CLINICAL SIGNS

History: Not provided.

SPECIES

Canine

ULTRASONOGRAPHIC EXAMINATION OF THE ABDOMEN

Urinary System

BREED

Bernese Moutain Dog

The **urinary bladder**, trigone, and pelvic urethra presented normal thicknesses and normal tone. The ureters were not visible which is normal. No uroliths or sediment were visualized, and anechoic urine was present. No evidence of inflammatory or neoplastic changes were noted. Ureteral papillae were normal.

SEX

Male

The **kidneys** revealed normal size and structure, corticomedullary definition and ratio for this age. The cortices presented largely uniform texture with normal echogenic relationship to liver and spleen. Medullary structure differed distinctly from the cortex and no evidence of pelvic dilation was present. The capsules were acceptably uniform without significant irregularities. The left kidney measured 7.8 cm in length. The right kidney measured 7.8 cm in length.

AGE

3 Years

Adrenal Glands

WEIGHT

109.5 pounds

Both **adrenal glands** were visualized and recognized as having normal shape, size, position and echogenicity for this breed. The phrenic vasculature, glandular echogenicity and detail were unremarkable. Capsule, cortex, and medullary definition were normal for this age patient. The left adrenal gland measured 3.37 cm x 0.50 cm width. The right adrenal gland measured 2.6 cm x 1.3 cm width at the cranial pole and 0.60 cm width at the caudal pole.

INTERPRETED BY

Eric Lindquist, DMV,
 DABVP(CFM), Cert.
 IVUSS

Spleen

The **spleen** in this patient was uniform, yet volume contracted. Hydration status should be assessed.

IMAGING PERFORMED BY

Eric Lindquist, DMV,
 DABVP(CFM), Cert.
 IVUSS

Liver

The **liver** images submitted revealed subjectively normal liver size, contour, and structure. Parenchymal echogenicity was naturally coarse and hypoechoic to the spleen. Vascular and biliary tracts were of normal volume with no evidence of congestion. The gallbladder presented acceptably thin walls with primarily anechoic content. The cystic and common bile ducts were normal. No pathological hepatic lymphadenopathy was evident. No overt structural evidence of inflammatory, infiltrative or regenerative pathology was evident.

HOSPITAL NAME

Butler Vet Hospital

Gastrointestinal

REFERRING VET

Dr. Garro

The **stomach** was severely over distended. A 4.6 cm proximal jejunal or mid-small intestinal foreign body was present with stasis. Some reactive mesentery was noted for an extension of approximately 5.0 cm to 8.0 cm with focally thickened bowel. The intestine that is obstructed does not appear very healthy. Regional peritonitis is initiating. The distal small intestine was unremarkable.

INVOICE

15267

Pancreas

DATE

04/21/26

The base and limbs of the **pancreas** were observed to be largely isoechoic to surrounding omental fat. Pancreatic duct and capsular contour were acceptably normal and parenchyma respected normal curvilinear patterns. No overt evidence of active inflammatory or neoplastic disease was noted.



PATIENT

Toby Marabello

SPECIES

Canine

BREED

Bernese Moutain Dog

SEX

Male

AGE

3 Years

WEIGHT

109.5 pounds

INTERPRETED BY

Eric Lindquist, DMV,
DABVP(CFM), Cert.
IVUSS

IMAGING PERFORMED BY

Eric Lindquist, DMV,
DABVP(CFM), Cert.
IVUSS

HOSPITAL NAME

Butler Vet Hospital

REFERRING VET

Dr. Garro

INVOICE

15267

DATE

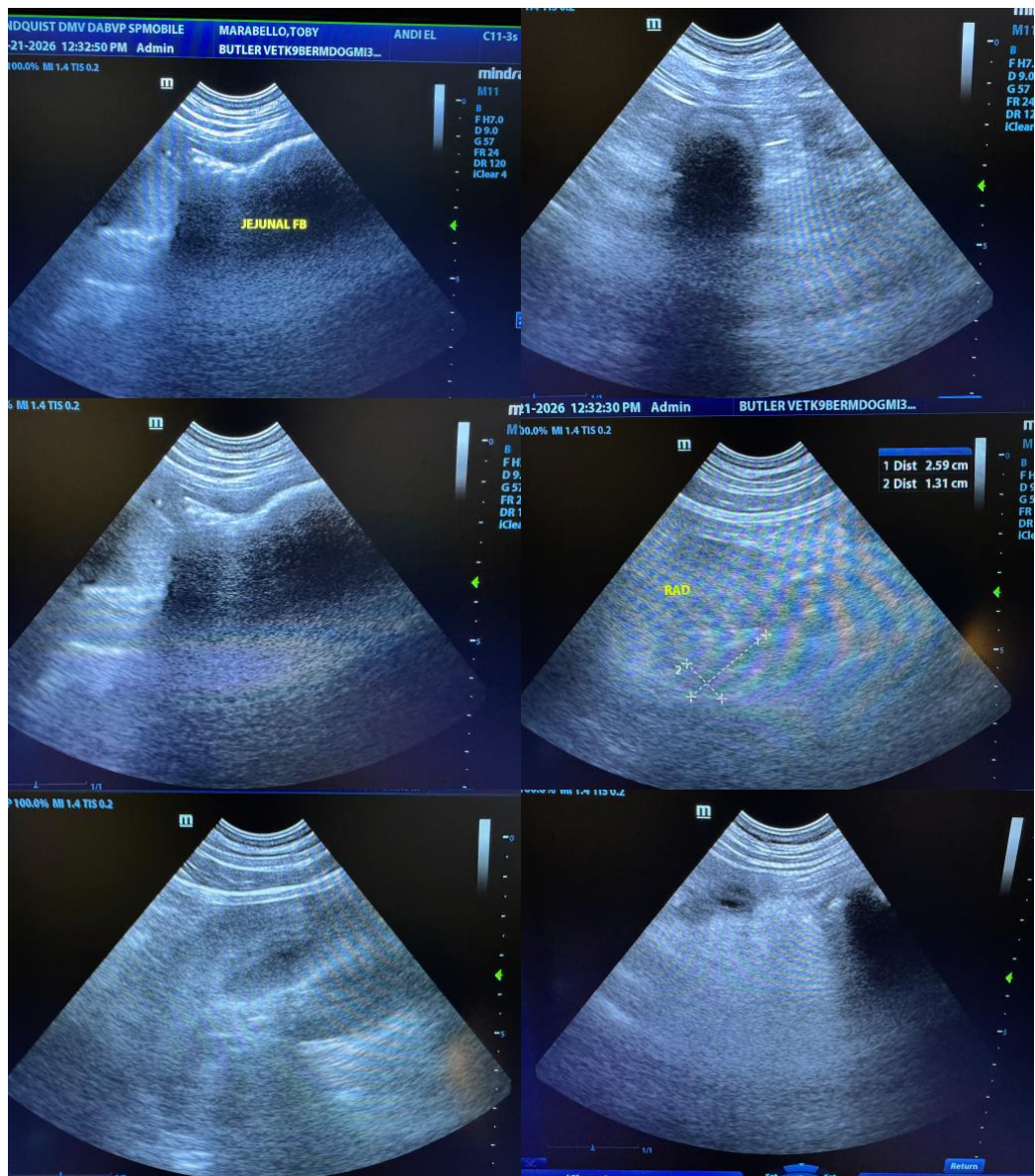
04/21/26

ULTRASONOGRAPHIC FINDINGS

- Intestinal foreign body obstruction with unhealthy bowel and regional emerging peritonitis.
- Volume contracted spleen.

INTERPRETATION OF THE FINDINGS & FURTHER RECOMMENDATIONS

Foreign body removal and intestinal resection and anastomosis strongly recommended in this patient with intestinal biopsy. Abdominal lavage may be necessary depending on how quickly the surgical intervention can occur.





PATIENT

Toby Marabello

SPECIES

Canine

BREED

Bernese Moutain Dog

SEX

Male

AGE

3 Years

WEIGHT

109.5 pounds

INTERPRETED BY

Eric Lindquist, DMV,
 DABVP(CFM), Cert.
 IVUSS

IMAGING PERFORMED BY

Eric Lindquist, DMV,
 DABVP(CFM), Cert.
 IVUSS

HOSPITAL NAME

Butler Vet Hospital

REFERRING VET

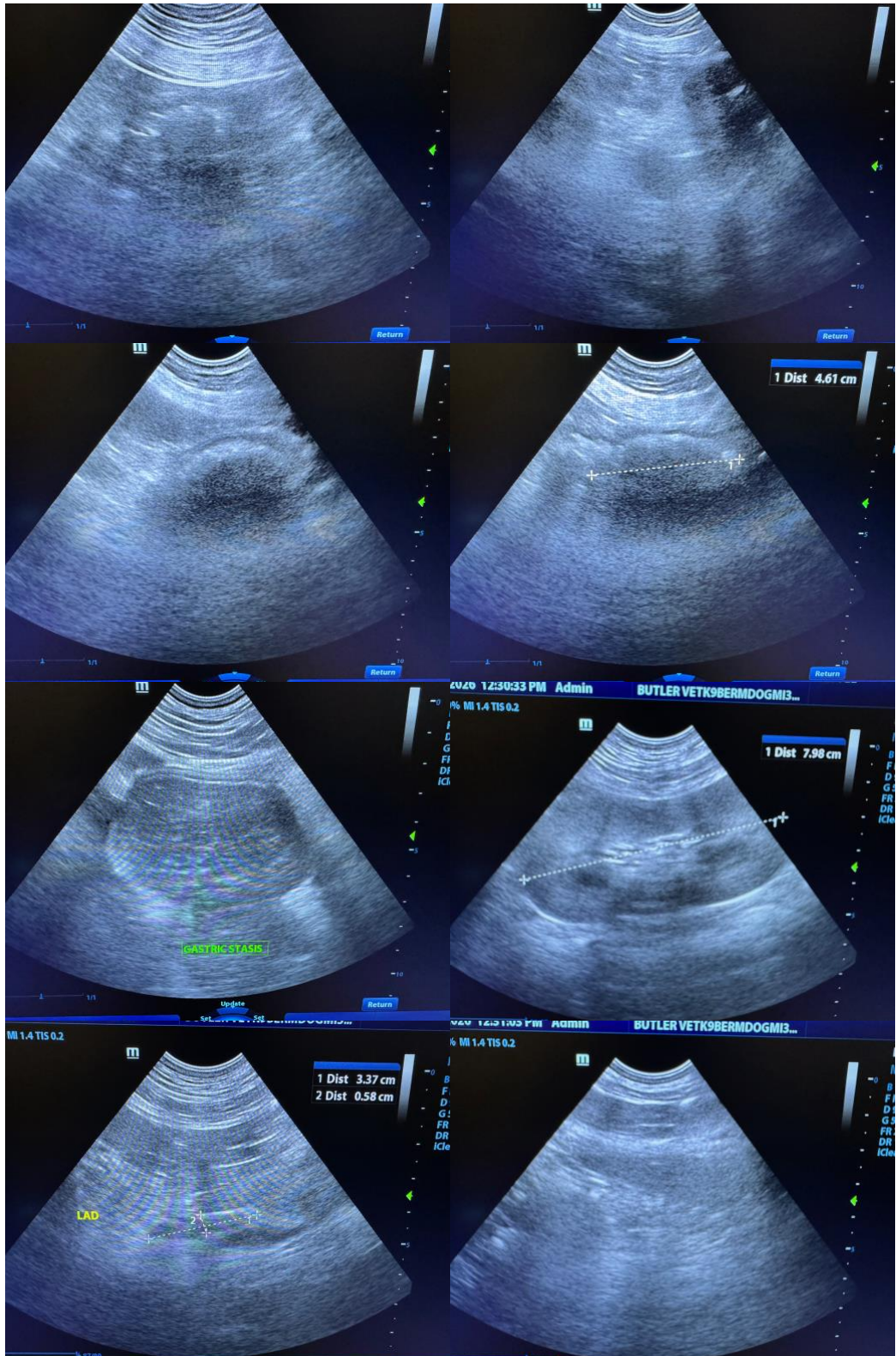
Dr. Garro

INVOICE

15267

DATE

04/21/26





PATIENT

Toby Marabello

The information and recommendations provided are based on the images presented by the referring veterinarian/sonographer. No evaluation can be communicated regarding pathology that was not visible in the image/video clips provided.

SPECIES

Canine

Thank you for this referral. If the clinical or image interpretation does not parallel your findings or if I can be of any further assistance, please contact me.

BREED

Bernese Moutain Dog

Eric Lindquist, DMV, DABVP(CFM), Cert. IVUSS,

CEO, Owner, Founder -- SonoPath.com

info@SonoPath.com

SEX

Male

AGE

3 Years

WEIGHT

109.5 pounds

INTERPRETED BY

Eric Lindquist, DMV,
DABVP(CFM), Cert.
IVUSS

**IMAGING
PERFORMED BY**

Eric Lindquist, DMV,
DABVP(CFM), Cert.
IVUSS

HOSPITAL NAME

Butler Vet Hospital

REFERRING VET

Dr. Garro

INVOICE

15267

DATE

04/21/26