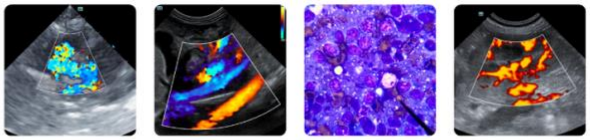

PATIENT
Jane Hildebrant

SPECIES
Feline

BREED
DLH

SEX
Spayed Female

AGE
13 Years

WEIGHT
9.7 Pounds

INTERPRETED BY
Eric Lindquist, DMV, DABVP (CFM), Cert. IVUSS

IMAGING PERFORMED BY
Danielle Shemanski, DVM, MA

HOSPITAL NAME
Western New York VS

REFERRING VET
Bella DeGelorm, DVM

INVOICE
36668

DATE
4/21/26

PRESENTING CLINICAL SIGNS

RDVM REASON FOR REFERRAL: Pulmonary edema without heart murmur, no improvement with Lasix. Seen 2/16/26 for difficulty breathing for a few weeks and some weight loss; crackles heard in left lung and chest rads showed mild fluid build up on the left; started on Lasix 12.5mg SID, but no improvement; seen again 4/13; louder crackles on the left; elevated TP, but otherwise nonspecific findings on BW; concerned for some type of cancer; instructed O to increase Lasix to 12.5mg BID; to start pred if no improvement on BID Lasix.

CLINICAL SIGNS: PE & Procedure (2026-04-21) Severely matted; required shaving. Dyspneic with handling/abdominal pressure. Recovered in oxygen (5 min). No sedation needed. Auscultation: No murmur; congested lungs/crackles. Breathing: Expiratory effort, ~50 bpm. Ultrasound Findings: Hemodynamically unstable. Probe pressure and patient position other than forelimbs slightly elevated increases respiratory effort.

MEDICATIONS: Lasix 12.5mg BID; Prednisolone 5mg starting 4/17 (tapering course)

Abnormal PE/Chem/CBC/UA Results: April 13, 2026: CBC: HGB 17.5 g/dL HIGH MCHC 36.3 g/dL HIGH Blood Chem: AMY 1161 U/L HIGH Glu 190 mg/dL HIGH K+ 3.5 mmol/L LOW TP 9.3 g/dL HIGH Glob 6.0 g/dL HIGH Hemolysis 1+ Lipemia 1+

** Abdominal and cardiac/thoracic images were submitted.

ULTRASONOGRAPHIC EXAMINATION OF THE ABDOMEN

Urinary System

The **urinary bladder**, trigone, and pelvic urethra presented normal thicknesses and normal tone. The ureters were not visible which is normal. No uroliths or sediment were visualized and anechoic urine was present. No evidence of inflammatory or neoplastic changes were noted. Ureteral papillae were normal.

The **kidneys** revealed largely normal size and structure, corticomedullary definition and ratio (cortex 1/3 of medulla) were essentially maintained with some mild age-related loss of curvilinear patterns regarding the capsule and C/M junction. The cortices presented largely uniform texture with some increased echogenicity expected for this age patient. Medullary structure differed distinctly from that of the cortex, and no evidence of pelvic dilation was present. The left kidney measured 2.96 cm. The right kidney measured 4.23 cm. Pinpoint mineralizations were noted in the right kidney.

Adrenal Glands

The **left adrenal gland** was visualized and recognized as having normal shape, size, position and echogenicity for this breed. The phrenic vasculature, glandular echogenicity and detail were unremarkable. Capsule, cortex, and medullary definition were normal for this age patient. The left adrenal gland measured 0.6 cm.

The region of the **right adrenal gland** was visualized, no evidence of pathology.

Spleen

The **spleen** in this patient was uniform, yet volume contracted. Hydration status should be assessed.

Liver

PATIENT

Jane Hildebrant

SPECIES

Feline

BREED

DLH

SEX

Spayed Female

AGE

13 Years

WEIGHT

9.7 Pounds

INTERPRETED BY

Eric Lindquist, DMV, DABVP (CFM), Cert. IVUSS

IMAGING PERFORMED BY

Danielle Shemanski, DVM, MA

HOSPITAL NAME

Western New York VS

REFERRING VET

Bella DeGelorm, DVM

INVOICE

36668

DATE

4/21/26

The **liver** images submitted revealed subjectively normal liver size, contour, and structure. Parenchymal echogenicity was naturally coarse and hypoechoic to the spleen. Vascular and biliary tracts were of normal volume with no evidence of congestion. The gallbladder presented acceptably thin walls with primarily anechoic content. The cystic and common bile ducts were normal. No pathological hepatic lymphadenopathy was evident. No overt structural evidence of inflammatory, infiltrative or regenerative pathology was evident.

Gastrointestinal

Examination of the **gastrointestinal tract** revealed a stomach and intestine free of stasis, of normal wall thickness, acceptable curvilinear mural detail, and peristaltic activity. Small and large intestine demonstrated normal luminal chyme and stool consistency respectively. No obstructive or overt infiltrative disease was noted. No associated abnormal lymphatic activity was noted.

Pancreas

The base and limbs of the **pancreas** were observed to be largely isoechoic to surrounding omental fat. Pancreatic duct and capsular contour were acceptably normal and parenchyma respected normal curvilinear patterns. No overt evidence of active inflammatory or neoplastic disease was noted.

Other

A rapid view of the **heart** revealed volume contraction. No evidence of cardiac disease was noted. No pleural effusion was noted in the thorax; however, a large amount of thoracic fat was present.

ULTRASONOGRAPHIC FINDINGS

- Unremarkable geriatric abdomen
- Volume contracted spleen
- Age-related renal changes with pinpoint mineralizations
- Excessive thoracic fat
- Volume contracted heart

INTERPRETATION OF THE FINDINGS & FURTHER RECOMMENDATIONS

No evidence of neoplasia. The prednisone may be suppressing a more significant presentation yet sonographically the changes are benign and consistent with age related abdominal changes. Recommend reducing the Lasix in this patient and volume expansion is warranted.

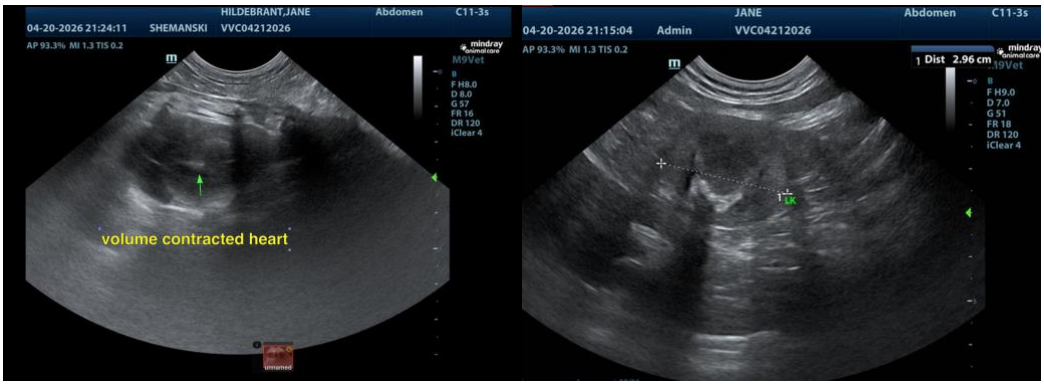

PATIENT

Jane Hildebrant

SPECIES

Feline

BREED

DLH

SEX

Spayed Female

AGE

13 Years

WEIGHT

9.7 Pounds

INTERPRETED BY

Eric Lindquist, DMV, DABVP (CFM), Cert. IVUSS

IMAGING PERFORMED BY

Danielle Shemanski, DVM, MA

HOSPITAL NAME

Western New York VS

REFERRING VET

Bella DeGelorm, DVM

INVOICE

36668

DATE

4/21/26

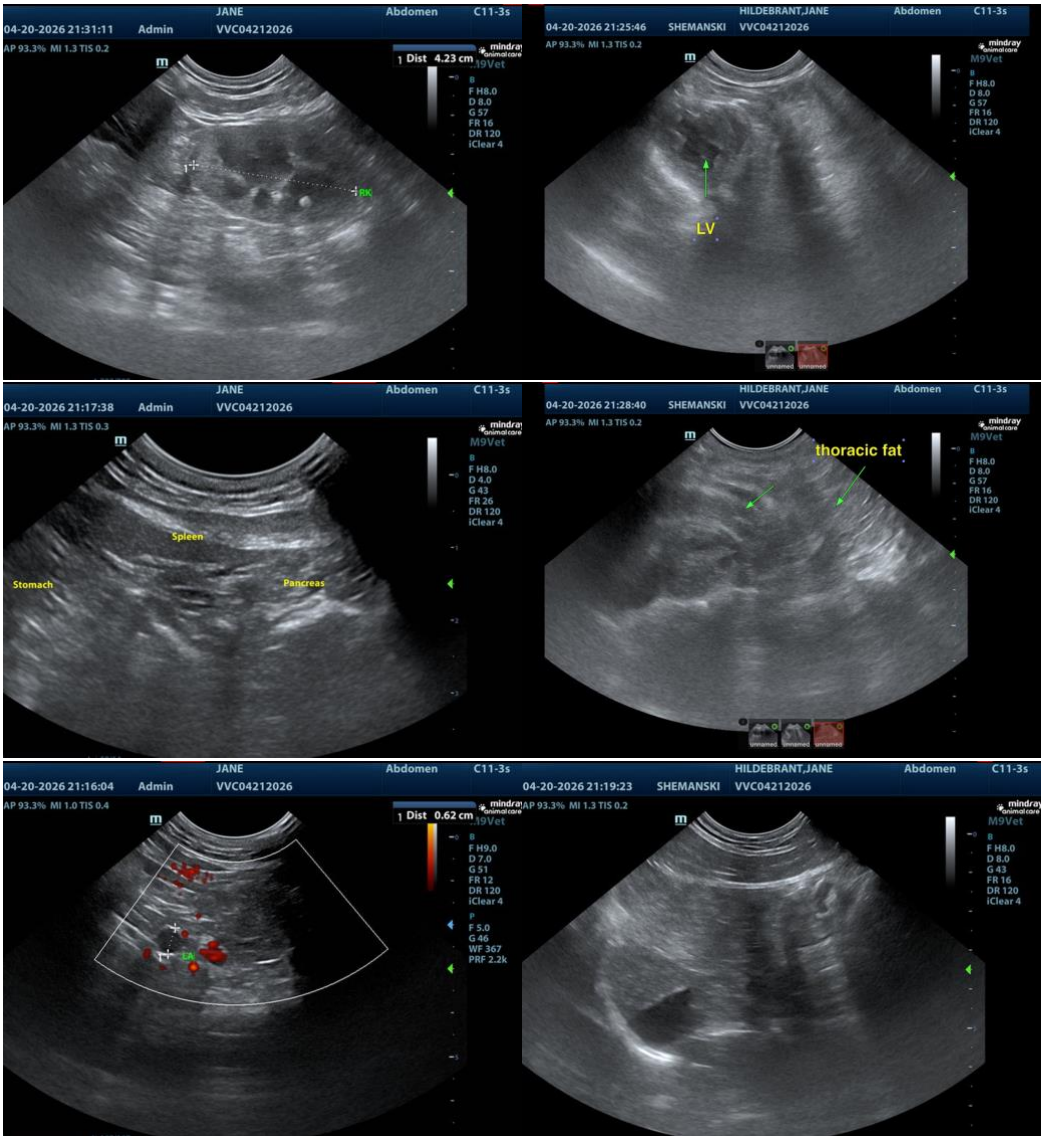

The information and recommendations provided are based on the images presented by the referring veterinarian/sonographer. No evaluation can be communicated regarding pathology that was not visible in the image/video clips provided.

Thank you for this referral. If the clinical or image interpretation does not parallel your findings or if I can be of any further assistance please contact me.

Eric Lindquist, DMV, DABVP(CFM), Cert. IVUSS,
CEO, Owner, Founder -- SonoPath.com
info@SonoPath.com