



PATIENT

Boomer Aust

SPECIES

Canine

BREED

Pitbull Mix

SEX

Neutered male

AGE

9 years

WEIGHT

62 lbs

INTERPRETED BY

Eric Lindquist, DMV
DABVP, Cert. IVUSS

IMAGING PERFORMED BY

Dr. Petrone

HOSPITAL NAME

Long Branch AH

REFERRING VET

Dr. Petrone

INVOICE

74701

DATE

4/21/26

PRESENTING CLINICAL SIGNS

History: Patient presented for urinating large amounts of urine. Owner unsure if polydipsia. Otherwise clinically normal. USG: 1.017, 1.021, one reading of 1.007. CBC/chem/T4-WNL

ULTRASONOGRAPHIC EXAMINATION OF THE ABDOMEN

Urinary System

The **urinary bladder**, trigone, and pelvic urethra presented normal thicknesses and normal tone. The ureters were not visible which is normal. No uroliths or sediment were visualized and anechoic urine was present. No evidence of inflammatory or neoplastic changes was noted. Ureteral papillae were normal.

The **kidneys** revealed largely normal size and structure, corticomedullary definition and ratio (cortex 1/3 of medulla) were essentially maintained with some age-related loss of curvilinear patterns regarding the capsule and C/M junction. The cortices presented largely uniform texture with some increased echogenicity expected for this age patient. Medullary structure differed distinctly from that of the cortex and no evidence of pelvic dilation was present. The right kidney measured 6.5 cm. The left kidney measured 7.2 cm.

The residual prostate measured 1.0 cm.

Adrenal Glands

The left **adrenal gland** was visualized and recognized as having normal shape, size, position and echogenicity for this breed. The phrenic vasculature, glandular echogenicity and detail were unremarkable. Capsule, cortex, and medullary definition were normal for this age patient. The left adrenal gland measured 0.4 cm at the cranial pole and 0.5 cm at the caudal pole. The **right adrenal gland** was not visualized.

Spleen

The **spleen** was mildly enlarged and uniform.

Liver

The **liver** images submitted revealed subjectively normal liver size, contour, and structure. Parenchymal echogenicity was naturally coarse and hypoechoic to the spleen. Vascular and biliary tracts were of normal volume with no evidence of congestion. The gallbladder presented acceptably thin walls with primarily anechoic content. The cystic and common bile ducts were normal. No pathological hepatic lymphadenopathy was evident. No overt structural evidence of inflammatory, infiltrative or regenerative pathology was evident.



PATIENT

Boomer Aust

SPECIES

Canine

BREED

Pitbull Mix

SEX

Neutered male

AGE

9 years

WEIGHT

62 lbs

INTERPRETED BY

Eric Lindquist, DMV
DABVP, Cert. IVUSS

Gastrointestinal

Examination of the **gastrointestinal tract** revealed a stomach and intestine free of stasis, of normal wall thickness, acceptable curvilinear mural detail, and peristaltic activity. Small and large intestine demonstrated normal luminal chyme and stool consistency respectively. No obstructive or overt infiltrative disease was noted. No associated abnormal lymphatic activity was noted.

Pancreas

The base and limbs of the **pancreas** were observed to be largely isoechoic to surrounding omental fat. Pancreatic duct and capsular contour were acceptably normal and parenchyma respected normal curvilinear patterns. No overt evidence of active inflammatory or neoplastic disease was noted.

ULTRASONOGRAPHIC FINDINGS

Structurally unremarkable abdomen.

Mild reactive spleen, no evidence of significant disease.

INTERPRETATION OF THE FINDINGS & FURTHER RECOMMENDATIONS

FNA of the spleen could be considered if weight loss is an issue.

IMAGING PERFORMED BY

Dr. Petrone

HOSPITAL NAME

Long Branch AH

REFERRING VET

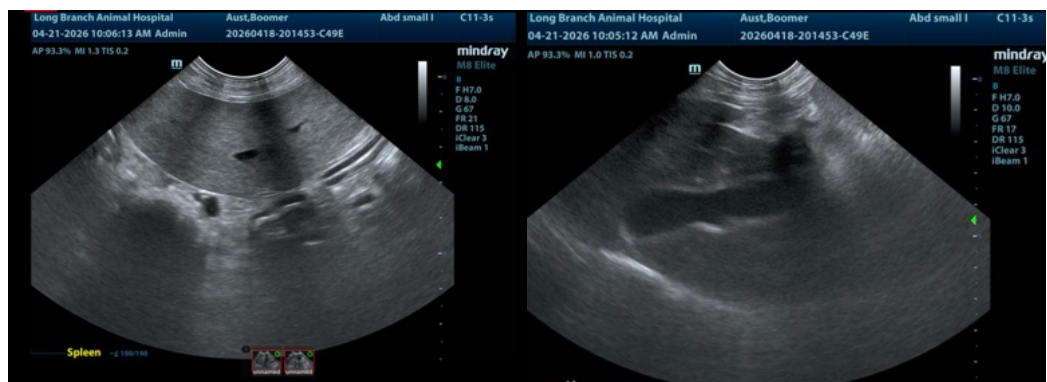
Dr. Petrone

INVOICE

74701

DATE

4/21/26





PATIENT

Boomer Aust

SPECIES

Canine

BREED

Pitbull Mix

SEX

Neutered male

AGE

9 years

WEIGHT

62 lbs

INTERPRETED BY

Eric Lindquist, DMV
DABVP, Cert. IVUSS

IMAGING PERFORMED BY

Dr. Petrone

HOSPITAL NAME

Long Branch AH

REFERRING VET

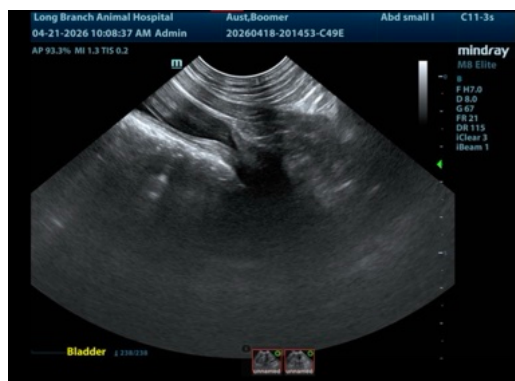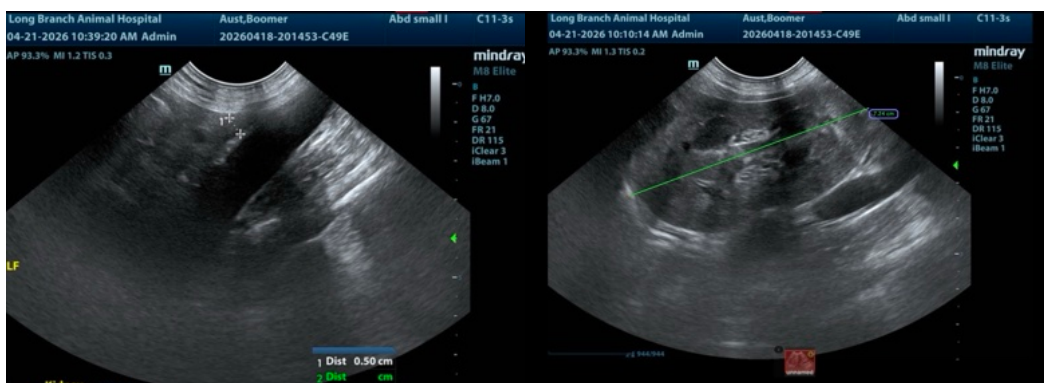
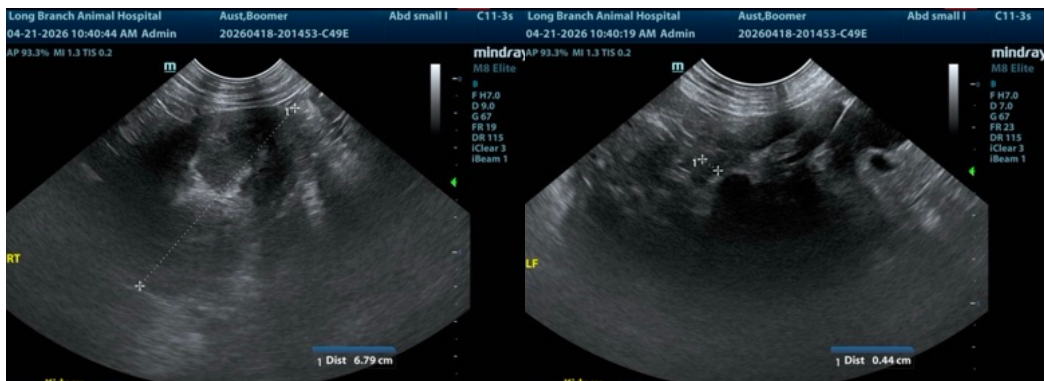
Dr. Petrone

INVOICE

74701

DATE

4/21/26



The information and recommendations provided are based on the images presented by the referring veterinarian/sonographer. No evaluation can be communicated regarding pathology that was not visible in the image/video clips provided.

Thank you for this referral. If the clinical or image interpretation does not parallel your findings or if I can be of any further assistance please contact me.

Eric Lindquist, DMV, DABVP (CFM), Cert. IVUSS, CEO of SonoPath.com

info@SonoPath.com