



PATIENT

Bailey Butler

SPECIES

Canine

BREED

Mixed Breed

SEX

Spayed Female

AGE

13 Years 2 Months

WEIGHT

69 pounds

INTERPRETED BY

Eric Lindquist, DMV,
DABVP(CFM), Cert.
IVUSS

IMAGING PERFORMED BY

Eric Lindquist, DMV,
DABVP(CFM), Cert.
IVUSS

HOSPITAL NAME

Greenwood Lakes
Animal Hospital

REFERRING VET

Dr. Streng

INVOICE

15297

DATE

04/21/26

PRESENTING CLINICAL SIGNS

Persistently elevated liver enzymes.

Labs: ALT 266 ALP 865

ULTRASONOGRAPHIC EXAMINATION OF THE ABDOMEN

Urinary System

The **urinary bladder**, trigone, and pelvic urethra presented normal thicknesses and normal tone. The ureters were not visible which is normal. No uroliths or sediment were visualized, and anechoic urine was present. No evidence of inflammatory or neoplastic changes were noted. Ureteral papillae were normal.

The **kidneys** revealed largely normal size and structure, corticomedullary definition and ratio (cortex 1/3 of medulla) were essentially maintained with some mild/moderate age-related loss of curvilinear patterns regarding the capsule and C/M junction. The cortices presented largely uniform texture with some increased echogenicity expected for his age patient. Medullary structure differed distinctly from that of the cortex and no evidence of pelvic dilation was present. The left kidney measured 6.56 cm in length. The right kidney measured 6.5 cm in length.

Adrenal Glands

The **adrenal glands** appeared moderately enlarged and swollen. No evidence of focal capsular expansion or invasion into the phrenic veins was noted. No overt suspicion of neoplasia was noted. This is considered likely a hyperplastic change associated with stress or adrenal endocrinopathy (PDH). If isosthenuria is persistently present and the patient morphologically suggests Cushing's disease then ACTH testing would be indicated. The left adrenal gland measured 2.74 cm x 1.08 cm width at the caudal pole and 0.89 cm width at the cranial pole. The right adrenal gland measured 1.63 cm width at the cranial pole and 1.15 cm width at the caudal pole.

Spleen

The **spleen** was largely smooth with mild heterogeneous parenchymal changes while maintaining normal echogenic relationship to the liver and kidney. These changes are consistent with normal age-related alteration. The capsule was smooth without noticeable impingement from within the spleen or from pathology in the adjacent abdomen. The splenic vasculature demonstrated normal volume without signs of congestion or significant contraction. No evidence of active acute or chronic inflammatory, neoplastic, or infarctual changes was noted.

Liver

The **liver** revealed multifocal nodular changes with remodeling with a hyperechoic macronodular change/nondisruptive mass measuring 4.5 cm in the left cranial liver with nodular changes elsewhere and irregular contour, most consistent with pronounced nodular hyperplasia or potential emerging cirrhosis. The gallbladder and common bile duct were unremarkable.

Gastrointestinal

The **stomach** presented minor mucosal hypertrophy without loss of mural detail. Anechoic fluid filled lumen noted, most consistent with gastritis or non-specific GI upset. The small intestine and colon



PATIENT

Bailey Butler

SPECIES

Canine

BREED

Mixed Breed

SEX

Spayed Female

AGE

13 Years 2 Months

WEIGHT

69 pounds

INTERPRETED BY

Eric Lindquist, DMV,
DABVP(CFM), Cert.
IVUSS

IMAGING PERFORMED BY

Eric Lindquist, DMV,
DABVP(CFM), Cert.
IVUSS

HOSPITAL NAME

Greenwood Lakes
Animal Hospital

REFERRING VET

Dr. Streng

INVOICE

15297

DATE

04/21/26

were unremarkable with normal uniform curvilinear patterns. No loss of mural detail and unremarkable lumen.

Pancreas

The base and limbs of the **pancreas** were observed to be largely isoechoic to surrounding omental fat. Pancreatic duct and capsular contour were acceptably normal and parenchyma respected normal curvilinear patterns. No overt evidence of active inflammatory or neoplastic disease was noted.

ULTRASONOGRAPHIC FINDINGS

- Bilateral adrenal hypertrophy
- Pronounced nodular liver changes- likely hyperplasia, potential cirrhosis, mild potential for neoplasia.
- Age-related renal changes.
- Gastric hypertrophy.
- Age-related splenic changes.

INTERPRETATION OF THE FINDINGS & FURTHER RECOMMENDATIONS

Bile acid profile and ultrasound guided FNA of the various nodular changes is indicated. If urine specific gravity is less than 1.020, workup for Cushing's/PDH is indicated.

Efficient & Accurate Cushing's Work up-Lindquist

Notes regarding Cushing's Clinical Presentations:

Nearly all Cushing's dogs have SAP elevations and true PU/PD (USG < 1.025) and most are polyphagic. Cushing's dogs are > 6 years and usually > 9 years old, usually have poor skin coats, body scores > 3/5, and are usually sedentary animals.

Its important to remember that Cushing's dogs usually look and play the part and other diseases cause false + stress related cortisol spikes. On rare occasion a Cushing's dog will not follow the rules but this is truly an exception.

Potential Cushing's patient workups can be costly and frustrating if not definitive and, in my experience, the non-definitive patient usually has something else going on that may be contributing to some of the clinical signs a Cushing's dog will have, especially SAP elevations or PU/PD. Based on this prelude of information I came up with the following algorithm in the spirit of diagnostic efficiency.

The following suggested protocol is based on current available literature on Cushing's disease and extensive clinical-sonographic experience evaluation + Cushing's and False + LDDST & ACTH stim. cases in order to maximize the efficiency of a Cushing's workup in practice.

Screen first, workup second

1) **UA:** Repeatable (2-3 urine samples) Urine specific gravity & urine cortisol/creatinine ratio (UCCR): If **repeatable USG < 10.20 and + UCCR** move to next step 2.

Note: UA is inexpensive and easy to obtain and if UA criteria is not met for Cushing's then resources can be spent into other more pertinent diagnostics or left on hold until the UA criteria is met in emerging Cushing's cases.

2) **Sonogram:** Does the patient **have concurrent disease** clinically or sonographically as non-Cushing's illness will influence the potential false + LDDST or even ACTH stim. The sonogram gives a global



PATIENT

Bailey Butler

SPECIES

Canine

BREED

Mixed Breed

SEX

Spayed Female

AGE

13 Years 2 Months

WEIGHT

69 pounds

INTERPRETED BY

Eric Lindquist, DMV,
DABVP(CFM), Cert.
IVUSS

IMAGING PERFORMED BY

Eric Lindquist, DMV,
DABVP(CFM), Cert.
IVUSS

HOSPITAL NAME

Greenwood Lakes
Animal Hospital

REFERRING VET

Dr. Streng

INVOICE

15297

DATE

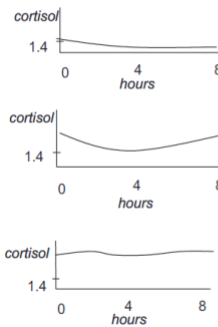
04/21/26

perspective of the internal health of the patient to be considered in the Cushing's workup as an assessment of concurrent disease. Is there a concurrent neoplastic process, UTI pancreatitis, mucocele....? Are the adrenals enlarged (Cushing's-PDH, stress, age related or breed variant), or atrophied (Iatrogenic Cushing's or adrenal burnout), have asymmetric enlargement (Adrenal tumor, hyperplasia, adenoma, age related variant), or is there vascular invasion (Invasive pheo with false + UA criteria or adenocarcinoma or phrenic thrombosis)? The sonogram answers these questions proactively.

Address & treat concurrent disease first before performing Cushing's testing or testing will be artificially altered increasing false negatives and positives.

3) **LDDST** (0.01 D-Sodium phosphate mg/kg IV *with precise dosing*****) (Better screening test but plagued with false + but considered more specific than ACTH stim) Use if there is potential early Cushing's or if adrenal asymmetry present on sonogram suspecting tumor. Use LDDST in cats at a higher dose (0.1 mg/kg IV). **Interpretation LDDST:** Look at 8-hour post first: If > 1.4 = Cushing's. Then look at 4-hour: if > 1.4 or > 50% baseline = Cushing's. 4-hour do then 8-hour spike most consistent with PDH. Flat line high constant curve without dip more consistent with tumor but can be PDH. See attached graph.

LDDS



Normal dogs

PDH

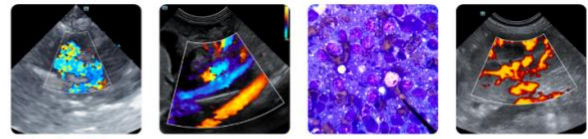
Adrenal Tumor
35% PDH

Courtesy: Rebecca Berg DACVIM, DECVIM

4) **ACTH stim.** (Better confirming test but can have false +) Use if the patient "looks" Cushingoid or if bilateral adrenal enlargement is present, or high normal width on sonogram, or if iatrogenic Cushing's suspected (Cortisone Tx in past). ACTH stim is better for diagnosis of Addisons, Iatrogenic Cushing's, and Cushing's therapy monitoring but problematic with initial Cushing's diagnosis. First dx LDDST is suggested.

5) If **diabetic** then run both LDDST & ACTH stim but stabilize as much as possible first.

5) Run a **serial blood pressure** in a BP friendly non "white coat effect" atmosphere. Run at least 3 at different times over a few hours or when eating as the patient tends to be calm when eating or give Torbutrol when entering the facility. Cushing's hypertension is usually 150-180 systolic range while pheochromocytoma range is more often > 180 systolic.



PATIENT

Bailey Butler

SPECIES

Canine

BREED

Mixed Breed

SEX

Spayed Female

AGE

13 Years 2 Months

WEIGHT

69 pounds

INTERPRETED BY

Eric Lindquist, DMV,
 DABVP(CFM), Cert.
 IVUSS

IMAGING PERFORMED BY

Eric Lindquist, DMV,
 DABVP(CFM), Cert.
 IVUSS

HOSPITAL NAME

Greenwood Lakes
 Animal Hospital

REFERRING VET

Dr. Streng

INVOICE

15297

DATE

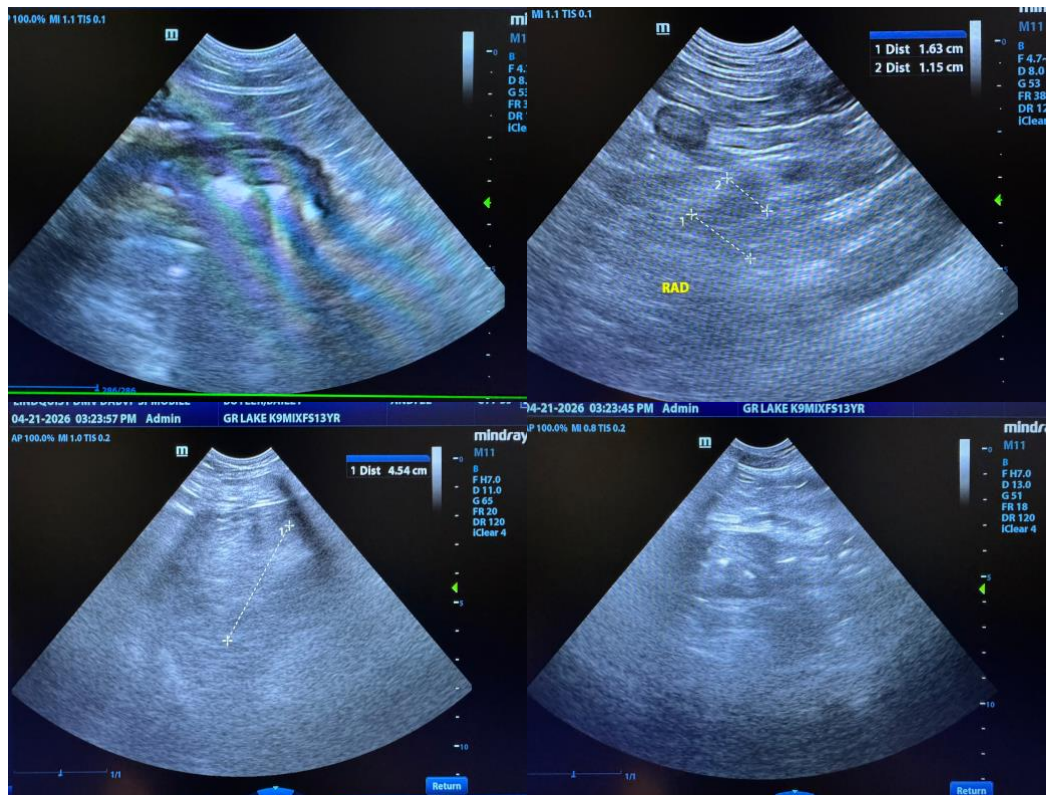
04/21/26

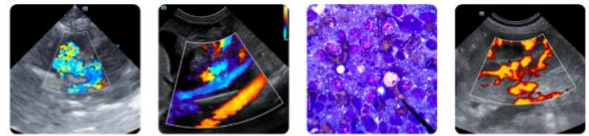
6) **Perform CT** of the pituitary to identify macro adenoma expansion if any lethargy or dullness or other central clinical CNS signs are minimally present. CT for adrenal may be more thorough for adrenalectomy surgical planning if ultrasound views of the CVC were problematic.

7) **Adrenectomy** for adrenal mass is prescribed then it is essential to stabilize the patient first regarding secondary disease such as organ dysfunction, hypertension, diabetes mellitus, hypernatremia, thromboembolic risk urinary and other infection in order to minimize potential for operative and postoperative complications as they are common in adrenalectomy. Trilostane stabilization therapy for Cushing's would be the first approach then address surgery and hypertension should be managed ideally < 160 systolic with ace inhibitors, phenoxybenzamine, or amlodipine.

Suggested reading:

Behrend EN, Kooistra HS, Nelson R, et al. Diagnosis of Spontaneous Canine Hyperadrenocorticism: 2012 ACVIM Consensus Statement (Small Animal). J Vet Intern Med 2013;27:1292–1304 .





PATIENT

Bailey Butler

SPECIES

Canine

BREED

Mixed Breed

SEX

Spayed Female

AGE

13 Years 2 Months

WEIGHT

69 pounds

INTERPRETED BY

Eric Lindquist, DMV,
 DABVP(CFM), Cert.
 IVUSS

IMAGING PERFORMED BY

Eric Lindquist, DMV,
 DABVP(CFM), Cert.
 IVUSS

HOSPITAL NAME

Greenwood Lakes
 Animal Hospital

REFERRING VET

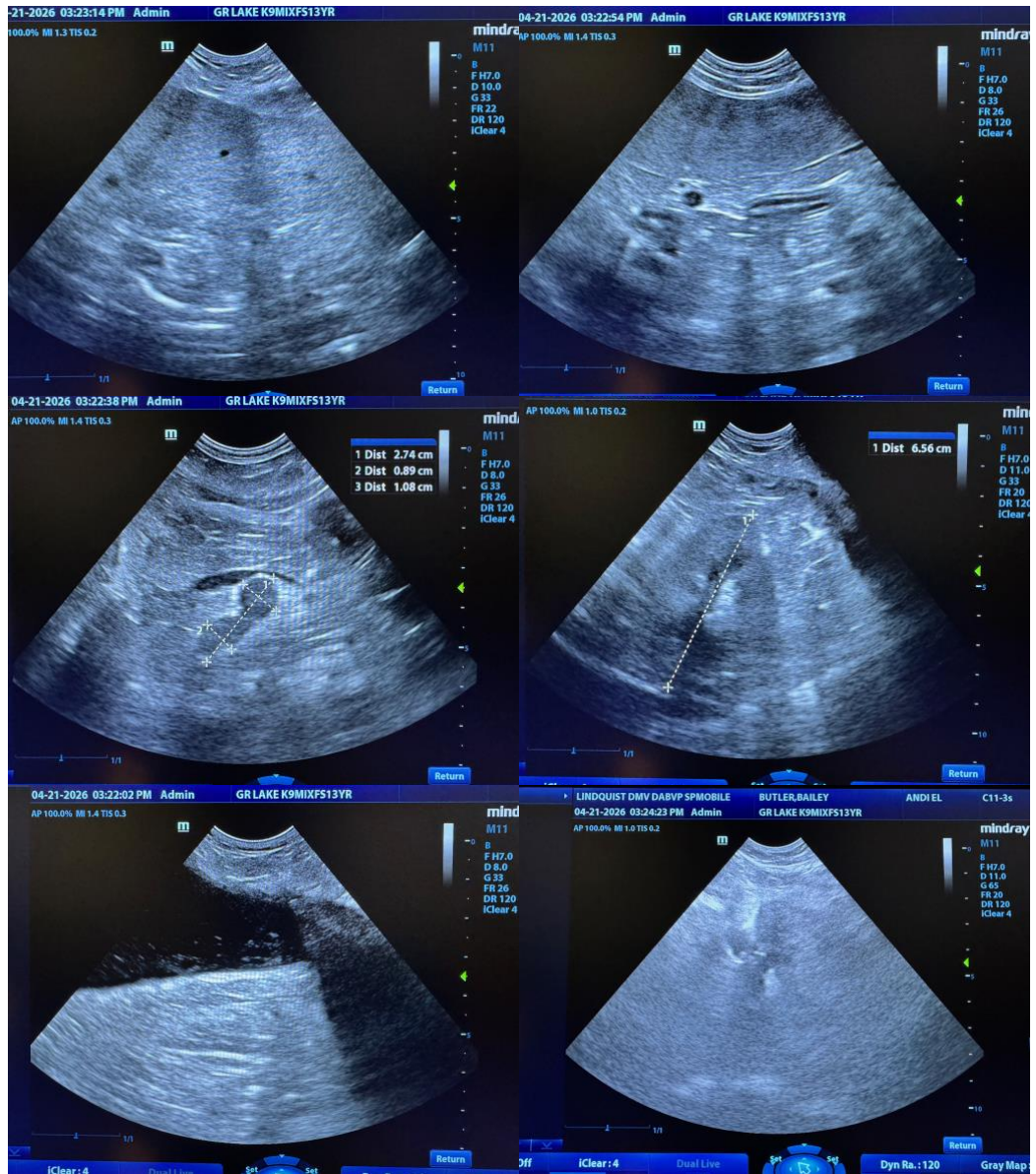
Dr. Streng

INVOICE

15297

DATE

04/21/26



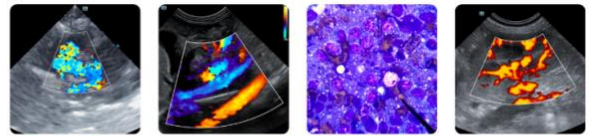
The information and recommendations provided are based on the images presented by the referring veterinarian/sonographer. No evaluation can be communicated regarding pathology that was not visible in the image/video clips provided.

Thank you for this referral. If the clinical or image interpretation does not parallel your findings or if I can be of any further assistance, please contact me.

Eric Lindquist, DMV, DABVP(CFM), Cert. IVUSS,

CEO, Owner, Founder -- SonoPath.com

info@SonoPath.com



PATIENT

Bailey Butler

SPECIES

Canine

BREED

Mixed Breed

SEX

Spayed Female

AGE

13 Years 2 Months

WEIGHT

69 pounds

INTERPRETED BY

Eric Lindquist, DMV,
DABVP(CFM), Cert.
IVUSS

**IMAGING
PERFORMED BY**

Eric Lindquist, DMV,
DABVP(CFM), Cert.
IVUSS

HOSPITAL NAME

Greenwood Lakes
Animal Hospital

REFERRING VET

Dr. Streng

INVOICE

15297

DATE

04/21/26