

**PATIENT**

Peter Pan Barber

**SPECIES**

Canine

**BREED**

Yorkshire Terrier

**SEX**

Neutered Male

**AGE**

6

**WEIGHT**

6

**INTERPRETED BY**

Eric Lindquist, DMV  
DABVP, Cert. IVUSS

**IMAGING PERFORMED BY**

A. Waffle

**HOSPITAL NAME**

Torch Lake VC

**REFERRING VET**

Adrienne Waffle

**INVOICE**

22118

**DATE**

4/21/23

**PRESENTING CLINICAL SIGNS**

History: Original ultrasound and radiography 4/18, brought back in for fasted ultrasound. Radiography reports possible mural thickening wall pyloric antrum of stomach and sliding hiatal hernia

**LIMITED ULTRASONOGRAPHIC EXAMINATION**

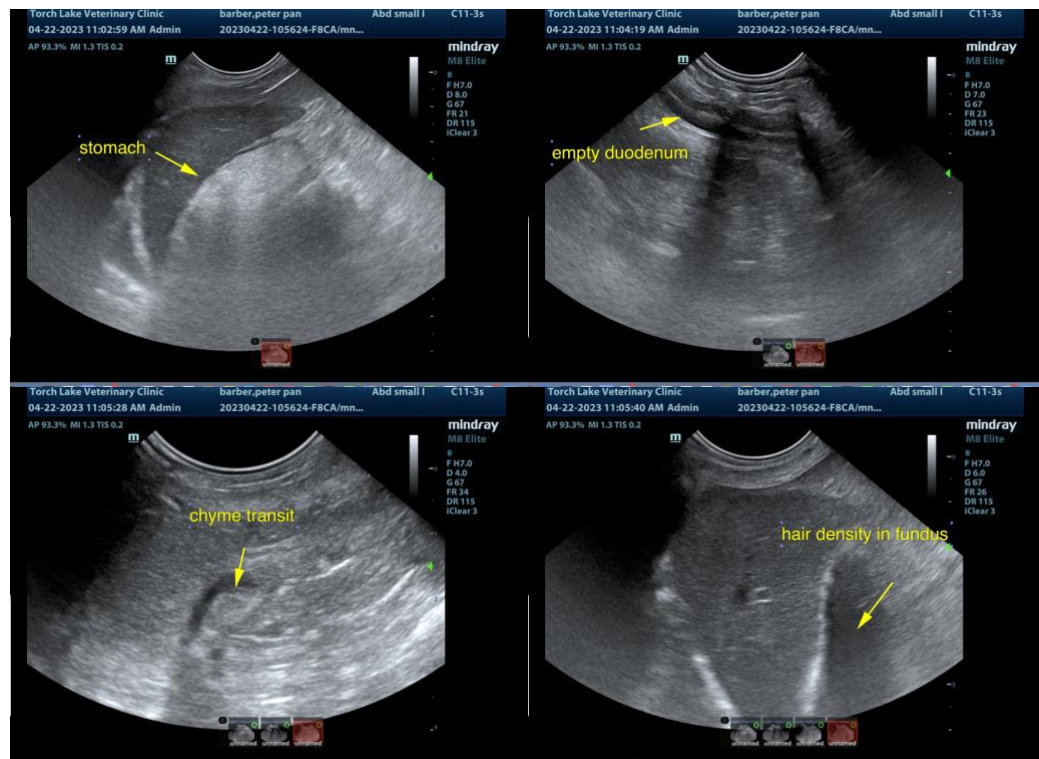
The stomach was persistently filled with progressively shadowing material with minor transit of chyme. This is a grass type density in this patient yet occupies the gastric fundus.

**ULTRASONOGRAPHIC FINDINGS**

- Full stomach- grass type density or possible foreign matter

**INTERPRETATION OF THE FINDINGS & FURTHER RECOMMENDATIONS**

Direct gastrotomy is indicated, or endoscopy. No overt hiatal hernia was noted at the time of the sonogram yet may be a sliding hernia. Surgical intervention is recommended.



**The information and recommendations provided are based on the images presented by the referring veterinarian. No evaluation can be communicated regarding pathology that was not visible in the image/video clips provided.**

Thank you for this referral. If the clinical or image interpretation does not parallel your findings or if I can be of any further assistance please contact me.

**Eric Lindquist, DMV, DABVP, Cert. IVUSS, CEO of SonoPath.com**



**PATIENT**

info@SonoPath.com

Peter Pan Barber

**SPECIES**

Canine

**BREED**

Yorkshire Terrier

**SEX**

Neutered Male

**AGE**

6

**WEIGHT**

6

**INTERPRETED BY**

Eric Lindquist, DMV  
DABVP, Cert. IVUSS

**IMAGING  
PERFORMED BY**

A. Waffle

**HOSPITAL NAME**

Torch Lake VC

**REFERRING VET**

Adrienne Waffle

**INVOICE**

22118

**DATE**

4/21/23