



PATIENT

Angel Kenyon

SPECIES

Canine

BREED

Lab Mix

SEX

Spayed Female

AGE

12 Years

WEIGHT

40.6 Pounds

INTERPRETED BY

Eric Lindquist, DMV
DABVP, Cert. IVUSS

IMAGING PERFORMED BY

Griffin

HOSPITAL NAME

Northside VC

REFERRING VET

Griffin

INVOICE

22122

DATE

4/21/23

PRESENTING CLINICAL SIGNS

Patient had severe mast cell disease on lateral thorax

ULTRASONOGRAPHIC EXAMINATION OF THE ABDOMEN

Urinary System

The **urinary bladder**, trigone, and pelvic urethra presented normal thicknesses and normal tone. The ureters were not visible which is normal. No uroliths or sediment were visualized and anechoic urine was present. No evidence of inflammatory or neoplastic changes were noted. Ureteral papillae were normal. The pelvic urethra was imaged 2.0 cm beyond the cystourethral junction.

The **kidneys** revealed largely normal size and structure, corticomedullary definition and ratio (cortex 1/3 of medulla) were essentially maintained with some mild age-related loss of curvilinear patterns regarding the capsule and C/M junction. The cortices presented largely uniform texture with some increased echogenicity expected for his age patient. Medullary structure differed distinctly from that of the cortex and no evidence of pelvic dilation was present. The right kidney measured 4.3 cm. The left kidney measured 4.6 cm.

Adrenal Glands

Both **adrenal glands** were visualized and recognized as having normal shape, size, position and echogenicity for this breed. The phrenic vasculature, glandular echogenicity and detail were unremarkable. Capsule, cortex, and medullary definition were normal for this age patient. The left adrenal gland measured 0.57 cm. The right adrenal gland measured 0.6 cm.

Spleen

The **spleen** was slightly enlarged with subtle micronodular changes and minor scalloping contour.

Liver

The **liver** revealed minor enlargement with heterogenous changes. The gallbladder and common bile duct were unremarkable.

Gastrointestinal

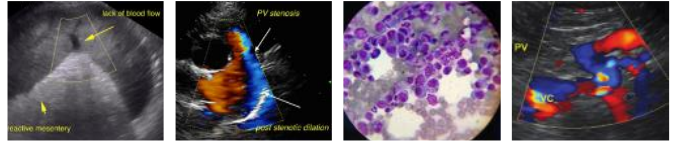
Examination of the **gastrointestinal tract** revealed a stomach and intestine free of stasis, of normal wall thickness, acceptable curvilinear mural detail, and peristaltic activity. Small and large intestine demonstrated normal luminal chyme and stool consistency respectively. No obstructive or overt infiltrative disease was noted. No associated abnormal lymphatic activity was noted.

Pancreas

The base and limbs of the **pancreas** were observed to be largely isoechoic to surrounding omental fat. Pancreatic duct and capsular contour were acceptably normal and parenchyma respected normal curvilinear patterns. No overt evidence of active inflammatory or neoplastic disease was noted.

ULTRASONOGRAPHIC FINDINGS

- Minor splenic enlargement
- Minor heterogenous hepatic enlargement
- Age-related renal changes



PATIENT

Angel Kenyon

SPECIES

Canine

BREED

Lab Mix

SEX

Spayed Female

AGE

12 Years

WEIGHT

40.6 Pounds

INTERPRETED BY

Eric Lindquist, DMV
DABVP, Cert. IVUSS

IMAGING PERFORMED BY

Griffin

HOSPITAL NAME

Northside VC

REFERRING VET

Griffin

INVOICE

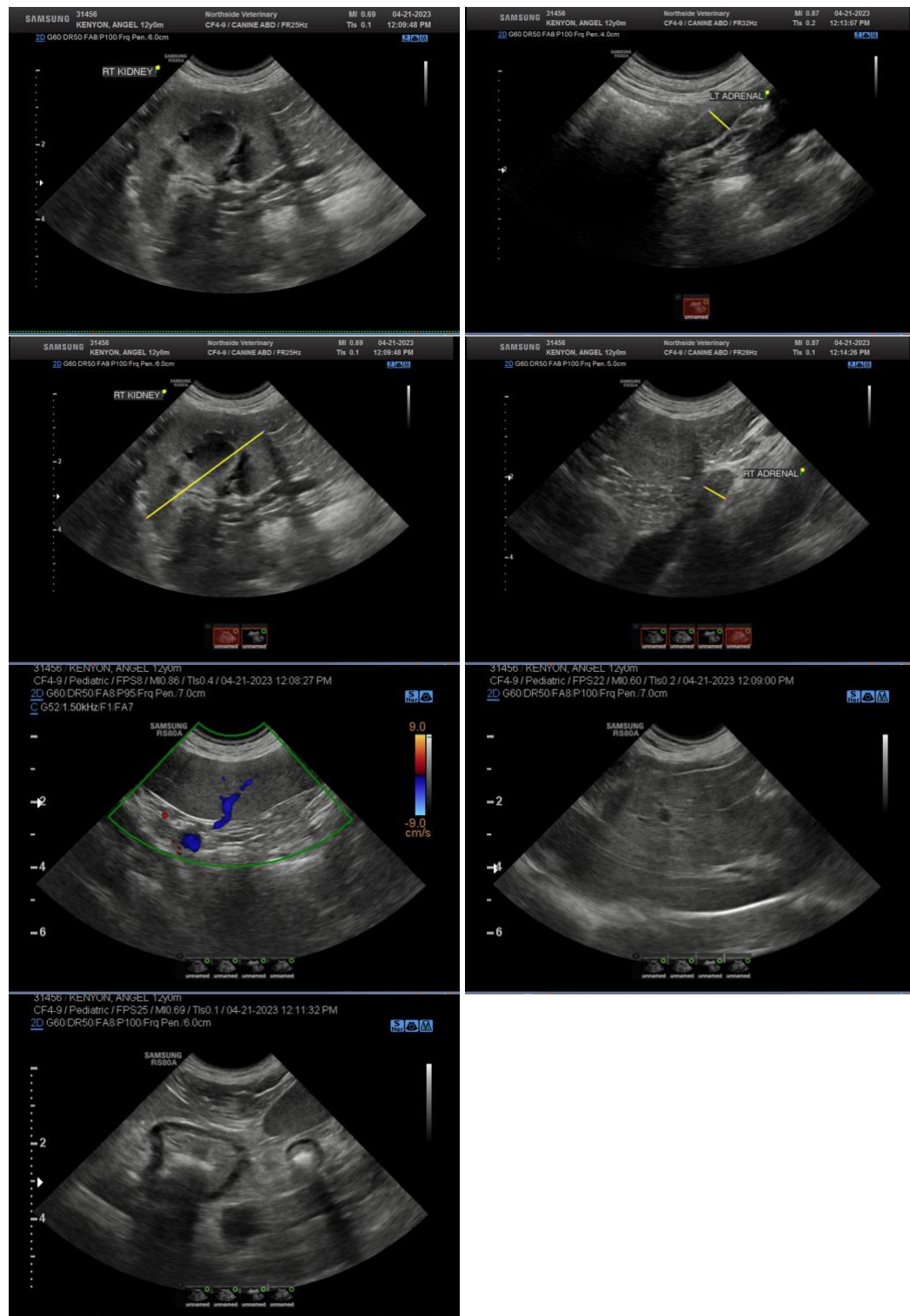
22122

DATE

4/21/23

INTERPRETATION OF THE FINDINGS & FURTHER RECOMMENDATIONS

Given the patient history, screening FNA of the spleen and liver is indicated. No overt evidence of metastatic disease, however, micrometastasis cannot be ruled out.





PATIENT

Angel Kenyon

The information and recommendations provided are based on the images presented by the referring veterinarian. No evaluation can be communicated regarding pathology that was not visible in the image/video clips provided.

SPECIES

Canine

Thank you for this referral. If the clinical or image interpretation does not parallel your findings or if I can be of any further assistance please contact me.

BREED

Lab Mix

Eric Lindquist, DMV, DABVP, Cert. IVUSS, CEO of SonoPath.com
info@SonoPath.com

SEX

Spayed Female

AGE

12 Years

WEIGHT

40.6 Pounds

INTERPRETED BY

Eric Lindquist, DMV
DABVP, Cert. IVUSS

**IMAGING
PERFORMED BY**

Griffin

HOSPITAL NAME

Northside VC

REFERRING VET

Griffin

INVOICE

22122

DATE

4/21/23