



## PATIENT

Stella Black

## SPECIES

Canine

## BREED

Boston Terrier

## SEX

Spayed female

## AGE

13 years

## WEIGHT

15.5 lbs

## INTERPRETED BY

Eric Lindquist, DMV  
DABVP, Cert. IVUSS

## IMAGING PERFORMED BY

Katie Heisler

## HOSPITAL NAME

TotalBond VH

## REFERRING VET

Dr. Heisler

## INVOICE

74617

## DATE

4/20/26

## PRESENTING CLINICAL SIGNS

History: - lethargy and inappetence starting 4/16  
- Fast scan showed gall bladder sludge and liver nodules  
- 1-2lbs weight loss over the past 2 years  
- Ursodiol started 4/16  
Abnormal PE/Chem/CBC/UA Results: - Thin BCS - ALP 387 - lymphopenia 0.56

## ULTRASONOGRAPHIC EXAMINATION OF THE ABDOMEN

### Urinary System

The **urinary bladder**, trigone, and pelvic urethra presented normal thicknesses and normal tone. The ureters were not visible which is normal. No uroliths or sediment were visualized and anechoic urine was present. No evidence of inflammatory or neoplastic changes was noted. Ureteral papillae were normal.

The **kidneys** revealed largely normal size and structure, corticomedullary definition and ratio (cortex 1/3 of medulla) were essentially maintained with some age-related loss of curvilinear patterns regarding the capsule and C/M junction. The cortices presented largely uniform texture with some increased echogenicity expected for this age patient. Medullary structure differed distinctly from that of the cortex and no evidence of pelvic dilation was present. The right kidney measured 4.5 cm. The left kidney measured 3.7 cm.

### Adrenal Glands

The left **adrenal gland** was enlarged and irregular with hypoechoic, swollen, irregular contour. The left adrenal gland measured 2.4 x 0.93 cm. The right adrenal gland was also enlarged and nodular. The right adrenal gland measured 3.2 x 1.4 cm at the cranial pole and 1.1 cm at the caudal pole.

### Spleen

The **spleen** in this patient was mildly enlarged with uniform parenchyma and was folded upon itself cranially. This is a positional variant and is not pathological. Subtle, heterogenous micronodular changes were noted in the spleen, yet non-disruptive and consistent with hyperplasia.

### Liver

The **liver** images from right and left intercostal as well as subcostal views revealed subjectively normal liver size, contour, and structure. Some age-related parenchymal remodeling was noted but likely not clinically significant at this time. Multi-focal, non-disruptive nodular changes were noted and measured up to 1.0 cm. The right hepatic base revealed an adenomatous type nodule that measured 2.6 cm and was non-disruptive. Vascular and biliary tracts were of normal volume and no evidence of congestion was noted. The gallbladder presented some dependent debris with essentially normal contour. The cystic and common bile ducts were normal. The hepatic lymph nodes were unremarkable.



**PATIENT**

**Gastrointestinal**

Stella Black

Examination of the **gastrointestinal tract** revealed a stomach and intestine free of stasis, of normal wall thickness, acceptable curvilinear mural detail, and peristaltic activity. Small and large intestine demonstrated normal luminal chyme and stool consistency respectively. No obstructive or overt infiltrative disease was noted. No associated abnormal lymphatic activity was noted.

**SPECIES**

Canine

**BREED**

**Pancreas**

Boston Terrier

The base and limbs of the **pancreas** were observed to be largely isoechoic to surrounding omental fat. Pancreatic duct and capsular contour were acceptably normal and parenchyma respected normal curvilinear patterns. No overt evidence of active inflammatory or neoplastic disease was noted.

**SEX**

Spayed female

**AGE**

13 years

**ULTRASONOGRAPHIC FINDINGS**

Micronodular hyperplasia splenic and hepatic patterns, likely benign.

**WEIGHT**

15.5 lbs

Bilateral, irregular nodular adrenal glands. Hyperplasia, emerging carcinoma and pheochromocytoma are all possible.

**INTERPRETED BY**

Eric Lindquist, DMV  
DABVP, Cert. IVUSS

**INTERPRETATION OF THE FINDINGS & FURTHER RECOMMENDATIONS**

FNA of the general hepatic parenchyma, spleen and liver are recommended with FNA of the macronodular change at the base of the right liver.

**IMAGING PERFORMED BY**

Katie Heisler

Full adrenal work-up is warranted. If the patient appears Cushingoid, PDH or adrenal dependent Cushing's is possible.

**HOSPITAL NAME**

TotalBond VH

Maldigestion panel, three view chest radiographs and full CNS examination is recommended to examine for occult disease that could be responsible for the weight loss. Evaluation for competitive eating environments should also be considered.

**REFERRING VET**

Dr. Heisler

**Efficient & Accurate Cushing's Work up-Lindquist**

**INVOICE**

74617

**Notes regarding Cushing's Clinical Presentations:**

*Nearly all Cushing's dogs have SAP elevations and true PU/PD (USG < 1.025) and most are polyphagic.*

*Cushing's dogs are > 6 years and usually > 9 years old, usually have poor skin coats, body scores > 3/5, and are usually sedentary animals.*

**DATE**

4/20/26

*Its important to remember that Cushing's dogs usually look and play the part and other diseases cause false + stress related cortisol spikes. On rare occasion a Cushing's dog will not follow the rules but this is truly an exception.*

*Potential Cushing's patient workups can be costly and frustrating if not definitive and, in my experience, the non-definitive patient usually has something else going on that may be contributing to*



## PATIENT

Stella Black

## SPECIES

Canine

## BREED

Boston Terrier

## SEX

Spayed female

## AGE

13 years

## WEIGHT

15.5 lbs

## INTERPRETED BY

Eric Lindquist, DMV  
DABVP, Cert. IVUSS

## IMAGING PERFORMED BY

Katie Heisler

## HOSPITAL NAME

TotalBond VH

## REFERRING VET

Dr. Heisler

## INVOICE

74617

## DATE

4/20/26

some of the clinical signs a Cushing's dog will have, especially SAP elevations or PU/PD. Based on this prelude of information I came up with the following algorithm in the spirit of diagnostic efficiency. The following suggested protocol is based on current available literature on Cushing's disease and extensive clinical-sonographic experience evaluation + Cushing's and False + LDDST & ACTH stim. cases in order to maximize the efficiency of a Cushing's workup in practice.

### Screen first, workup second

1) **UA:** Repeatable (2-3 urine samples) Urine specific gravity & urine cortisol/creatinine ratio (UCCR): If **repeatable USG < 10.20 and + UCCR** move to next step 2.

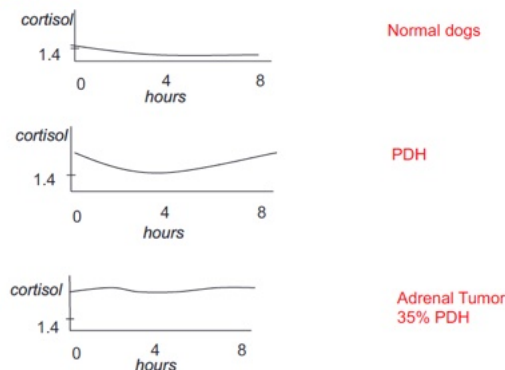
*Note: UA is inexpensive and easy to obtain and if UA criteria is not met for Cushing's then resources can be spent into other more pertinent diagnostics or left on hold until the UA criteria is met in emerging Cushing's cases.*

2) **Sonogram:** Does the patient **have concurrent disease** clinically or sonographically as non-Cushing's illness will influence the potential false + LDDST or even ACTH stim. The sonogram gives a global perspective of the internal health of the patient to be considered in the Cushing's workup as an assessment of concurrent disease. Is there a concurrent neoplastic process, UTI pancreatitis, mucocele...? Are the adrenals enlarged (Cushing's-PDH, stress, age related or breed variant), or atrophied (iatrogenic Cushing's or adrenal burnout), have asymmetric enlargement (Adrenal tumor, hyperplasia, adenoma, age related variant), or is there vascular invasion (Invasive pheo with false + UA criteria or adenocarcinoma or phrenic thrombosis)? The sonogram answers these questions proactively.

**Address & treat concurrent disease first before performing Cushing's testing or testing will be artificially altered increasing false negatives and positives.**

3) **LDDST** (0.01 D-Sodium phosphate mg/kg IV **with precise dosing\*\*\*\***) (Better screening test but plagued with false + but considered more specific than ACTH stim) Use if there is potential early Cushing's or if adrenal asymmetry present on sonogram suspecting tumor. Use LDDST in cats at a higher dose (0.1 mg/kg IV). **Interpretation LDDST:** Look at 8-hour post first: If > 1.4 = Cushing's. Then look at 4-hour: if > 1.4 or > 50% baseline = Cushing's. 4-hour do then 8-hour spike most consistent with PDH. Flat line high constant curve without dip more consistent with tumor but can be PDH. See attached graph.

### LDDS



Courtesy: Rebecca Berg DACVIM, DECVIM



## PATIENT

Stella Black

## SPECIES

Canine

## BREED

Boston Terrier

## SEX

Spayed female

## AGE

13 years

## WEIGHT

15.5 lbs

## INTERPRETED BY

Eric Lindquist, DMV  
DABVP, Cert. IVUSS

## IMAGING PERFORMED BY

Katie Heisler

## HOSPITAL NAME

TotalBond VH

## REFERRING VET

Dr. Heisler

## INVOICE

74617

## DATE

4/20/26

4) **ACTH stim.** (Better confirming test but can have false +) Use if the patient “looks” Cushingoid or if bilateral adrenal enlargement is present, or high normal width on sonogram, or if iatrogenic Cushing’s suspected (Cortisone Tx in past). ACTH stim is better for diagnosis of Addisons, Iatrogenic Cushing’s, and Cushing’s therapy monitoring but problematic with initial Cushing’s diagnosis. First dx LDDST is suggested.

5) If **diabetic** then run both LDDST & ACTH stim but stabilize as much as possible first.

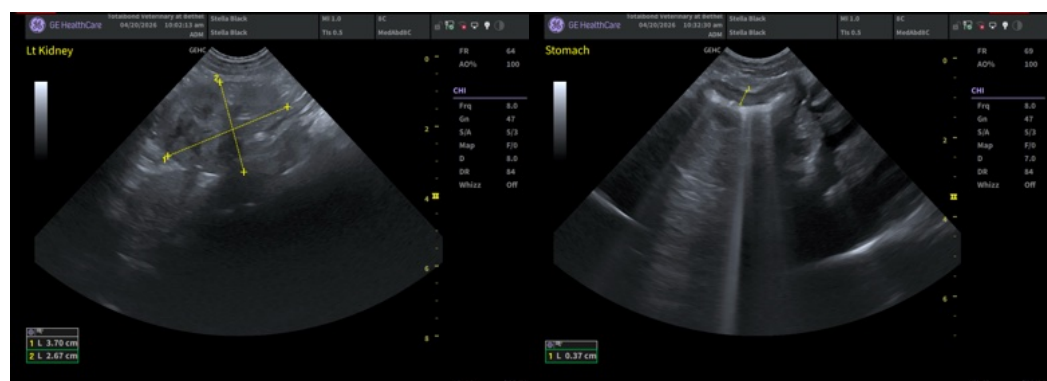
5) Run a **serial blood pressure** in a BP friendly non “white coat effect” atmosphere. Run at least 3 at different times over a few hours or when eating as the patient tends to be calm when eating or give Torbutrol when entering the facility. Cushing’s hypertension is usually 150-180 systolic range while pheochromocytoma range is more often > 180 systolic.

6) **Perform CT** of the pituitary to identify macro adenoma expansion if any lethargy or dullness or other central clinical CNS signs are minimally present. CT for adrenal may be more thorough for adrenalectomy surgical planning if ultrasound views of the CVC were problematic.

7) **Adrenectomy** for adrenal mass is prescribed then it is essential to stabilize the patient first regarding secondary disease such as organ dysfunction, hypertension, diabetes mellitus, hypernatremia, thromboembolic risk urinary and other infection in order to minimize potential for operative and postoperative complications as they are common in adrenalectomy. Trilostane stabilization therapy for Cushing’s would be the first approach then address surgery and hypertension should be managed ideally < 160 systolic with ace inhibitors, phenoxybenzamine, or amlodipine.

Suggested reading:

Behrend EN, Kooistra HS, Nelson R, et al. Diagnosis of Spontaneous Canine Hyperadrenocorticism: 2012 ACVIM Consensus Statement (Small Animal). J Vet Intern Med 2013;27:1292–1304 .





**PATIENT**

Stella Black

**SPECIES**

Canine

**BREED**

Boston Terrier

**SEX**

Spayed female

**AGE**

13 years

**WEIGHT**

15.5 lbs

**INTERPRETED BY**

Eric Lindquist, DMV  
DABVP, Cert. IVUSS

**IMAGING PERFORMED BY**

Katie Heisler

**HOSPITAL NAME**

TotalBond VH

**REFERRING VET**

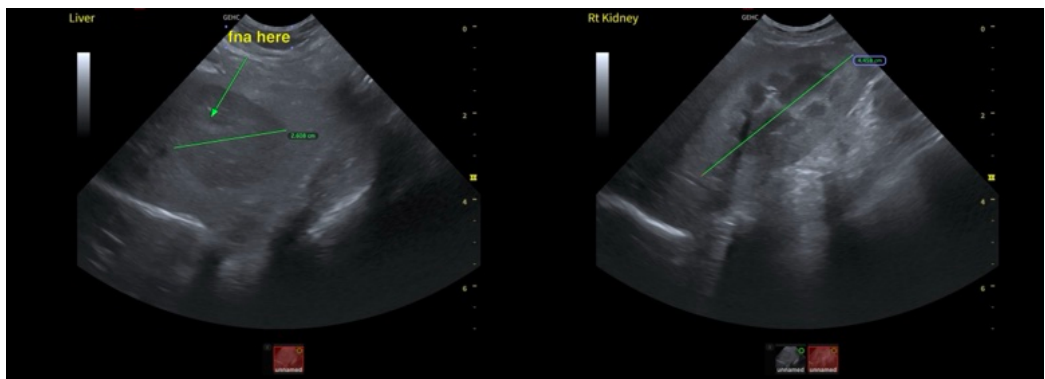
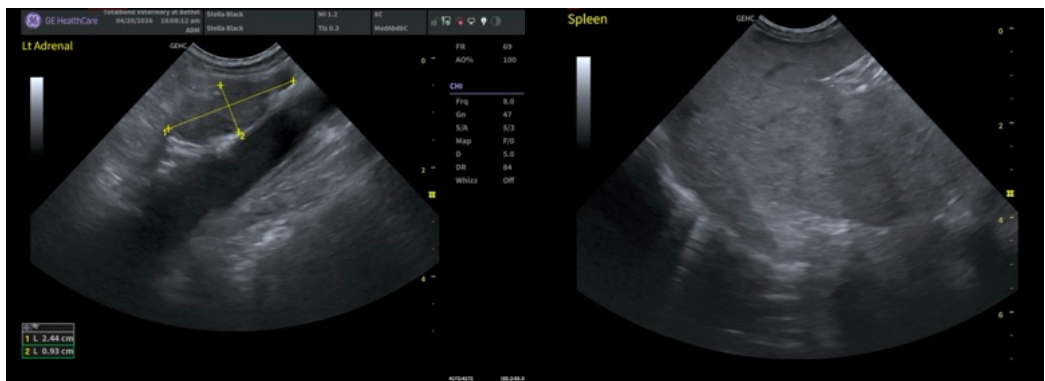
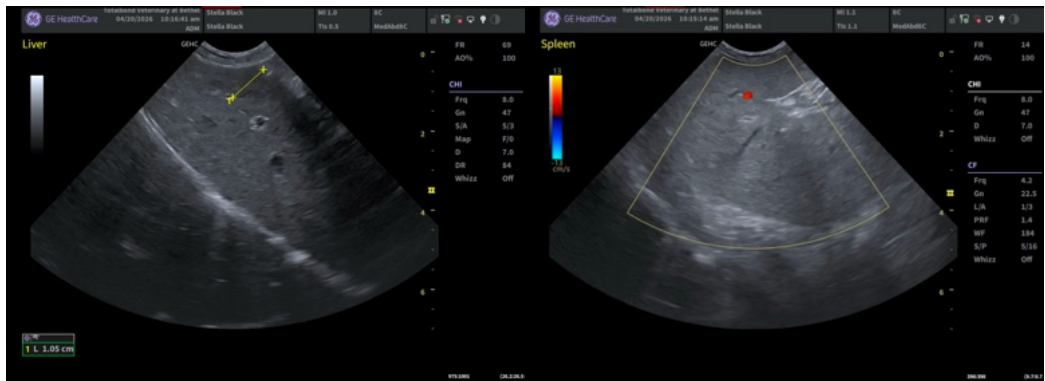
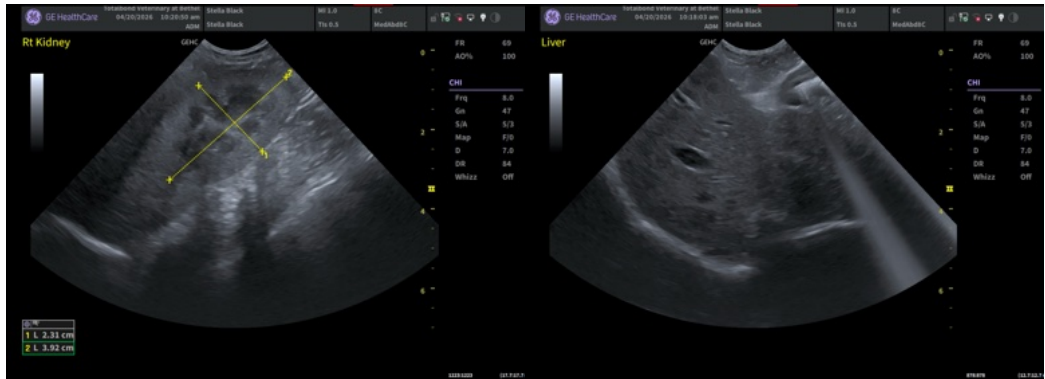
Dr. Heisler

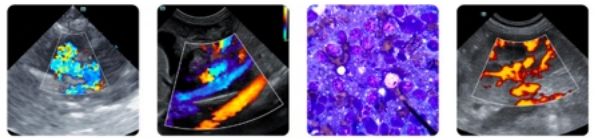
**INVOICE**

74617

**DATE**

4/20/26





## PATIENT

Stella Black

## SPECIES

Canine

## BREED

Boston Terrier

## SEX

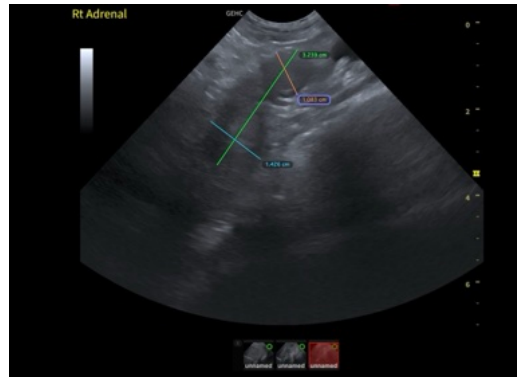
Spayed female

## AGE

13 years

## WEIGHT

15.5 lbs



The information and recommendations provided are based on the images presented by the referring veterinarian/sonographer. No evaluation can be communicated regarding pathology that was not visible in the image/video clips provided.

Thank you for this referral. If the clinical or image interpretation does not parallel your findings or if I can be of any further assistance please contact me.

Eric Lindquist, DMV, DABVP (CFM), Cert. IVUSS, CEO of SonoPath.com

[info@SonoPath.com](mailto:info@SonoPath.com)

## INTERPRETED BY

Eric Lindquist, DMV  
DABVP, Cert. IVUSS

## IMAGING PERFORMED BY

Katie Heisler

## HOSPITAL NAME

TotalBond VH

## REFERRING VET

Dr. Heisler

## INVOICE

74617

## DATE

4/20/26