



PATIENT

Parker Bustamante

SPECIES

Feline

BREED

DSH

SEX

Spayed Female

AGE

6 Months

WEIGHT

8.1 Pounds

INTERPRETED BY

Eric Lindquist, DMV,
DABVP (Canine & Feline), Cert. IVUSS

IMAGING PERFORMED BY

Vincent Ravancho,
CVT

HOSPITAL NAME

Northvale VC

REFERRING VET

Dr. Simon

INVOICE

36657

DATE

4/20/26

PRESENTING CLINICAL SIGNS

History: Panting and open mouth breathing intermittently. Sibling has feline asthma; thoracic rads pending and sent to Sonopath.

ULTRASONOGRAPHIC EXAMINATION OF THE HEART

FELINE CARDIAC PARAMETERS	BODY WEIGHT (lbs)	HR (BPM)	IVSd (cm)	LVIDd (cm)	LVWd (cm)	FS (%)	EF (%)
NORMAL PARAMETER	-----	150-240	0.3-0.6	1.0-2.1	0.25-0.6	35-67	80-100
PATIENT	8.1	105	0.47	1.8	0.46	41	75
FELINE CARDIAC PARAMETERS	LA/AO (M-mode)	LA/AO HEART BASE (Sisson)	LAD LA MAX 4 Chamber		LVOT VEL (m/s)	RVOT VEL (m/s)	IVRT (m/)
NORMAL PARAMETER	<1.5	1.6	0.7-1.7		<1.6	<1.3	40-60
PATIENT	1.05	--	--		1.00	.95	NM

Adapted from June Boon, Veterinary Echocardiography, 1998
Sisson D et al. JVIM 1991; 5: 232, Jacobs et al. Am J Vet Res 1985; 46:1705

E-wave velocity: 0.6, EPSS: 0.1

Cardiac Presentation

The echocardiogram in this patient demonstrated normal **left atrial** size based on 3 separate LA measurements. The cranial and caudal **mitral** valve leaflets presented normal linear structure and kinetics. The **left ventricle** presented normal thicknesses with linear contour and was not dilated nor restricted. The **myocardium** presented normal echogenicity without subjective evidence of significant fibrotic or ischemic disease. **Contractility** of the ventricular walls was adequate and in normal range for this patient evidenced by the fractional shortening measurement and subjective evaluation of the different regions and angles of the myocardium. The **left ventricular outflow** tract demonstrated normal laminar flow and subjective structural integrity. The **right atrium** and auricle revealed normal size, structure and content. No evidence of masses was noted or chamber overload. **Tricuspid** valvular assessment demonstrated adequate linear morphology and kinetics. The **right ventricle** was of normal size (1/3 diameter of LV), chordae structure, myocardial echogenicity and thickness. **Pulmonic** tract assessment revealed normal valve structure, laminar flow, and diameter (approx. 1:1 pa/ao ratio). No visible **pericardial** or free pleura fluid was noted or extra cardiac pathology in the visible planes. The cranial **mediastinum** and **pericardial regions** were free of masses in the visible window.

ULTRASONOGRAPHIC FINDINGS

- Normal echocardiogram- no cardiogenic disease in this patient.

INTERPRETATION OF THE FINDINGS & FURTHER RECOMMENDATIONS

No evidence of clinical disease.



PATIENT

Parker Bustamante

SPECIES

Feline

BREED

DSH

SEX

Spayed Female

AGE

6 Months

WEIGHT

8.1 Pounds

INTERPRETED BY

Eric Lindquist, DMV,
 DABVP (Canine &
 Feline), Cert. IVUSS

IMAGING PERFORMED BY

Vincent Ravancho,
 CVT

HOSPITAL NAME

Northvale VC

REFERRING VET

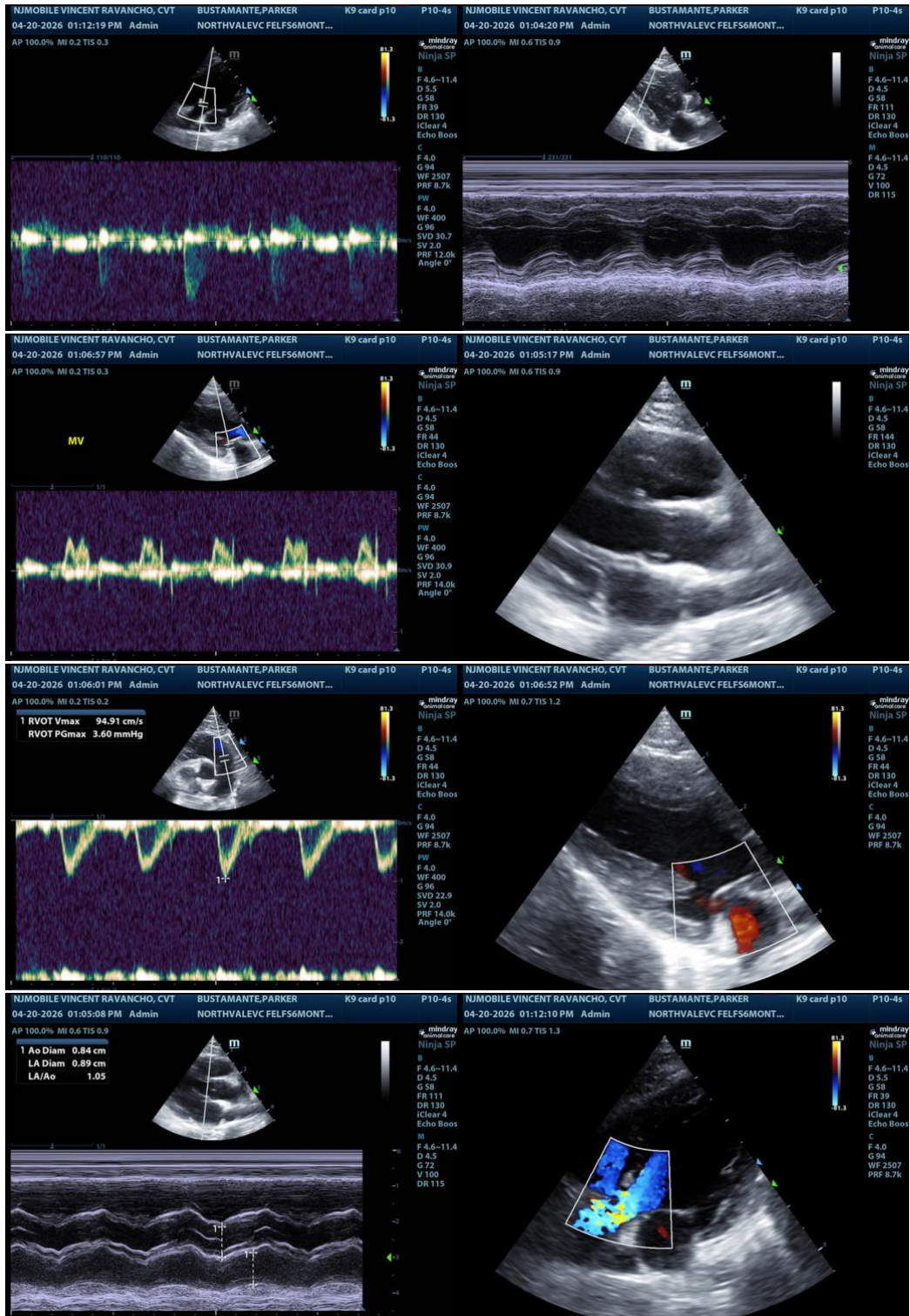
Dr. Simon

INVOICE

36657

DATE

4/20/26





PATIENT

Parker Bustamante

SPECIES

Feline

BREED

DSH

SEX

Spayed Female

AGE

6 Months

WEIGHT

8.1 Pounds

INTERPRETED BY

Eric Lindquist, DMV,
DABVP (Canine &
Feline), Cert. IVUSS

**IMAGING
PERFORMED BY**

Vincent Ravancho,
CVT

HOSPITAL NAME

Northvale VC

REFERRING VET

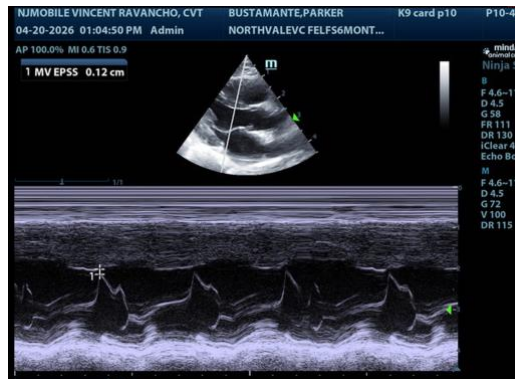
Dr. Simon

INVOICE

36657

DATE

4/20/26



The information and recommendations provided are based on the images presented by the referring veterinarian/sonographer. No evaluation can be communicated regarding pathology that was not visible in the image/video clips provided.

Thank you for this referral. If the clinical or image interpretation does not parallel your findings or if I can be of any further assistance please contact me.

Eric Lindquist, DMV, DABVP(CFM), Cert. IVUSS,
CEO, Owner, Founder -- SonoPath.com
info@SonoPath.com