



PATIENT

Raphael Johansen

SPECIES

Feline

BREED

Sphynx

SEX

Spayed female

AGE

5 years

WEIGHT

3.82 kg

INTERPRETED BY

Eric Lindquist, DMV
DABVP, Cert. IVUSS

IMAGING PERFORMED BY

Dr. Biederbeck

HOSPITAL NAME

Lomsnes VH

REFERRING VET

Dr. Biederbeck

INVOICE

43906

DATE

4/20/23

PRESENTING CLINICAL SIGNS

History: Ate a flutterboard >1mo ago. Since then vomiting once/wk, intermittently acting painful and hiding. Has lost 100g

Abnormal PE/Chem/CBC/UA Results: Has lost 100g, otherwise normal.

ULTRASONOGRAPHIC EXAMINATION OF THE ABDOMEN

Urinary System

The **urinary bladder**, trigone, and pelvic urethra presented normal thicknesses and normal tone. The ureters were not visible which is normal. No uroliths or sediment were visualized and anechoic urine was present. No evidence of inflammatory or neoplastic changes was noted. Ureteral papillae were normal.

The **kidneys** revealed normal size and structure, corticomedullary definition and ratio for this age. The cortices presented largely uniform texture with normal echogenic relationship to liver and spleen. Medullary structure differed distinctly from the cortex and no evidence of pelvic dilation was present. The capsules were acceptably uniform without significant irregularities. The left kidney measured 4.0 cm.

Adrenal Glands

Both **adrenal glands** were visualized and recognized as having normal shape, size, position and echogenicity for this breed. The phrenic vasculature, glandular echogenicity and detail were unremarkable. Capsule, cortex, and medullary definition were normal for this age patient.

Spleen

The **spleen** presented a smooth homogeneous parenchyma hyperechoic to liver and renal cortical parenchyma. The capsule was smooth without noticeable expansion or deviation from within the spleen or adjacent pathology. The splenic vasculature demonstrated normal volume without signs of congestion or thrombosis. No sonographic evidence of acute or chronic inflammatory, neoplastic, or infarctual changes was noted.

Liver

The **liver** images submitted revealed subjectively normal liver size, contour, and structure. Parenchymal echogenicity was naturally coarse and hypoechoic to the spleen. Vascular and biliary tracts were of normal volume with no evidence of congestion. The gallbladder presented acceptably thin walls with primarily anechoic content. The cystic and common bile ducts were normal. No pathological hepatic lymphadenopathy was evident. No overt structural evidence of inflammatory, infiltrative or regenerative pathology was evident.



PATIENT

Raphael Johansen

SPECIES

Feline

BREED

Sphynx

SEX

Spayed female

AGE

5 years

WEIGHT

3.82 kg

INTERPRETED BY

Eric Lindquist, DMV
DABVP, Cert. IVUS

IMAGING PERFORMED BY

Dr. Biederbeck

HOSPITAL NAME

Lomsnes VH

REFERRING VET

Dr. Biederbeck

INVOICE

43906

DATE

4/20/23

Gastrointestinal

The **stomach** presented a fluid filled lumen and gas. The small intestine and upper duodenum was empty. Descending colon was filled with normal stool. Reactive mesentery was noted in the mesenteric root with slight mesenteric lymphadenopathy measuring up to 0.5 cm.

Pancreas

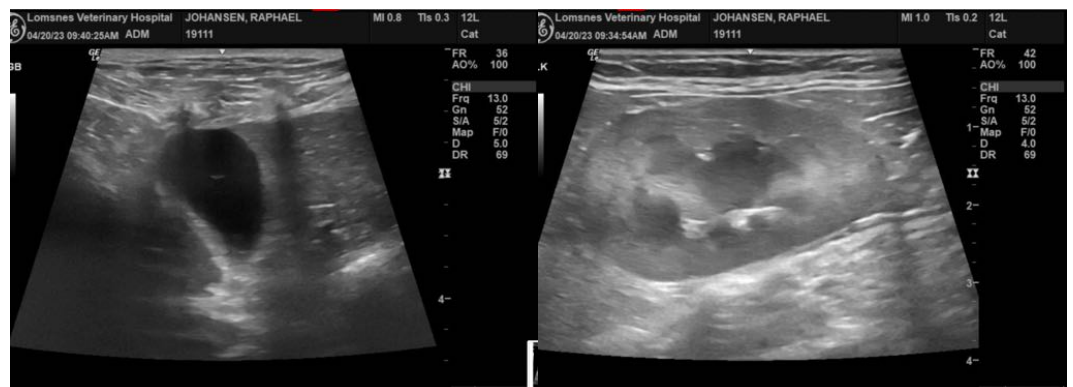
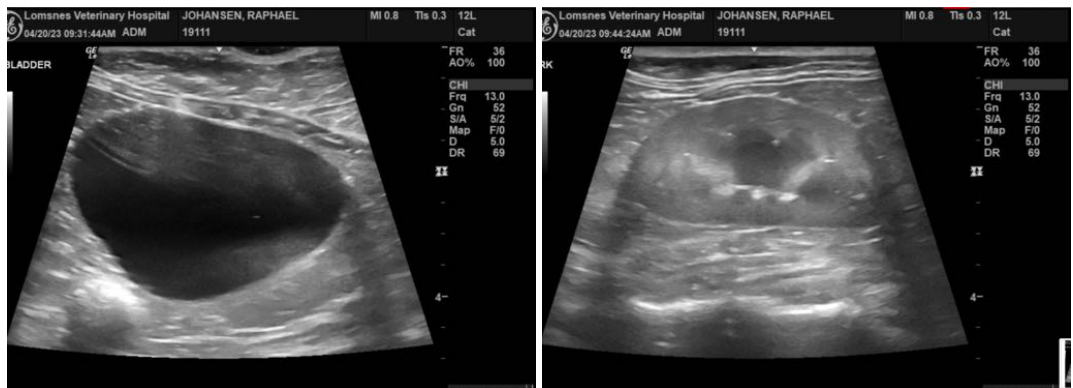
The base and limbs of the **pancreas** were observed to be largely isoechoic to surrounding omental fat. Pancreatic duct and capsular contour were acceptably normal and parenchyma respected normal curvilinear patterns. No overt evidence of active inflammatory or neoplastic disease was noted.

ULTRASONOGRAPHIC FINDINGS

Mild gastritis pattern, no obvious foreign matter.

INTERPRETATION OF THE FINDINGS & FURTHER RECOMMENDATIONS

Supportive care should prove effective if the clinical signs persist. A recheck sonogram is recommended in 48-72 hours. Some reactive mesentery was noted. There was no overt evidence of foreign matter.





PATIENT

Raphael Johansen

SPECIES

Feline

BREED

Sphynx

SEX

Spayed female

AGE

5 years

WEIGHT

3.82 kg

INTERPRETED BY

Eric Lindquist, DMV
DABVP, Cert. IVUSS

IMAGING PERFORMED BY

Dr. Biederbeck

HOSPITAL NAME

Lomsnes VH

REFERRING VET

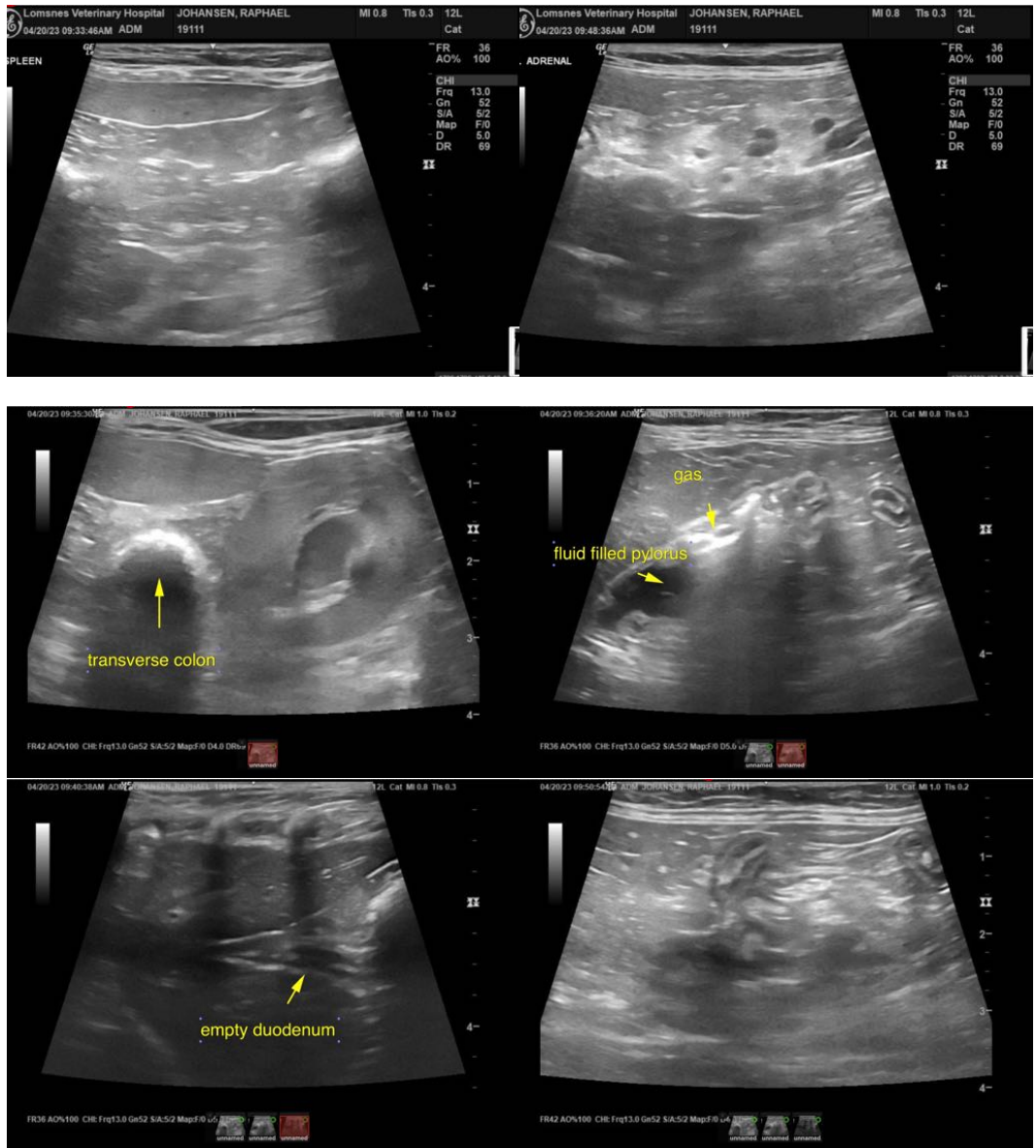
Dr. Biederbeck

INVOICE

43906

DATE

4/20/23



The information and recommendations provided are based on the images presented by the referring veterinarian/sonographer. No evaluation can be communicated regarding pathology that was not visible in the image/video clips provided.

Thank you for this referral. If the clinical or image interpretation does not parallel your findings or if I can be of any further assistance please contact me.

Eric Lindquist, DMV, DABVP, Cert. IVUSS, CEO of SonoPath.com
info@SonoPath.com