



PATIENT

Lili Maniar

SPECIES

Feline

BREED

DSH

SEX

Spayed Female

AGE

10

WEIGHT

12.2

INTERPRETED BY

Eric Lindquist, DMV

DABVP, Cert. IVUSS

IMAGING PERFORMED BY

Jenn

HOSPITAL NAME

Rockaway AH

REFERRING VET

Dr. Maniar

INVOICE

46805

DATE

4/20/23

PRESENTING CLINICAL SIGNS

Recheck from yesterday, persistent anemia, no vomiting, did hairball move?

LIMITED ULTRASONOGRAPHIC EXAMINATION

Gastrointestinal

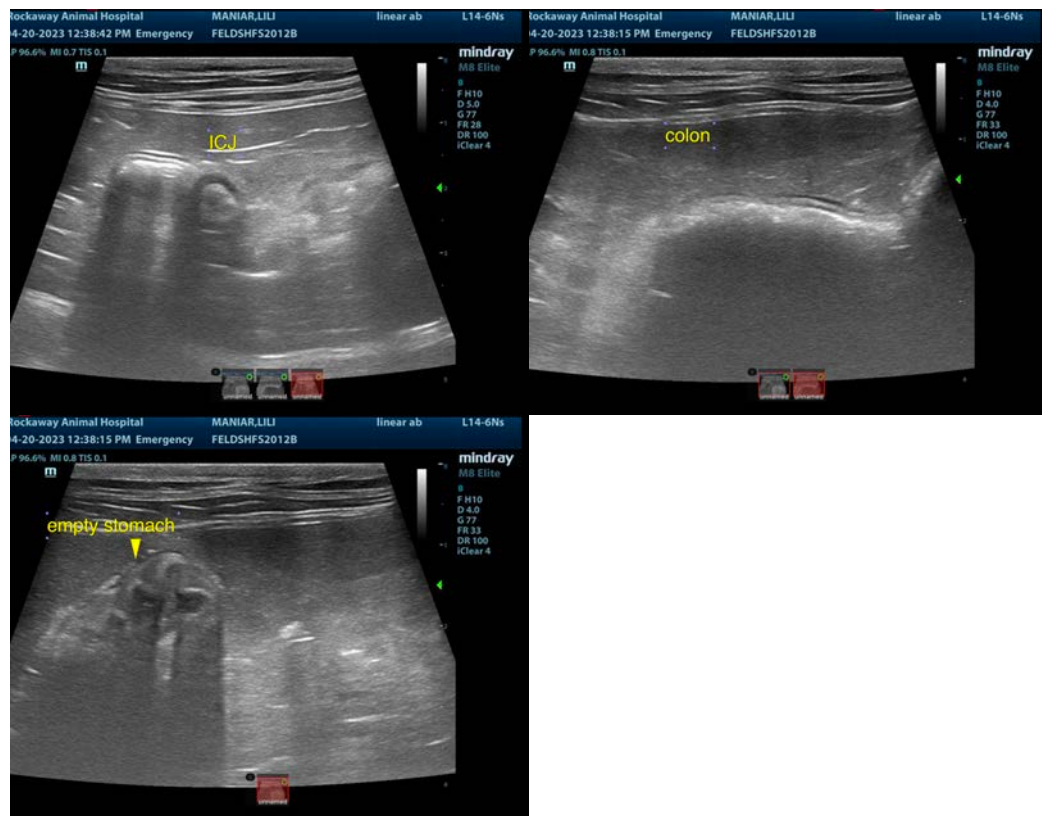
Examination of the **gastrointestinal tract** revealed persistent intestinal thickening. The colon was filled with normal stool. The ileocecal junction was free of evident pathology.

ULTRASONOGRAPHIC FINDINGS

- No evidence of hairball accumulation noted

INTERPRETATION OF THE FINDINGS & FURTHER RECOMMENDATIONS

The cause of anemia is unclear. However, the GI presentation appears to have improved.



The information and recommendations provided are based on the images presented by the referring veterinarian/sonographer. No evaluation can be communicated regarding pathology that was not visible in the image/video clips provided.

Thank you for this referral. If the clinical or image interpretation does not parallel your findings or if I can be of any further assistance please contact me.

Eric Lindquist, DMV, DABVP, Cert. IVUSS, CEO of SonoPath.com

info@SonoPath.com