SonoPath
Clinical Sonography & Telecytology

EDUCATIONAL TELECONSULTATION SERVICES™

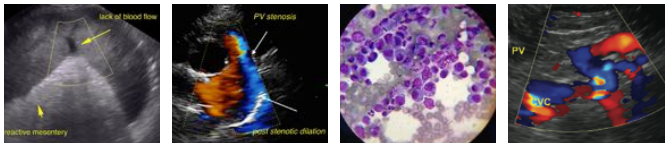

SonoPath.com™
1-800-838-4268 info@sonopath.com

PATIENT
Evvy Terpak

SPECIES
Canine

BREED
Cavalier King Charles Spaniel

SEX
Spayed female

AGE
7 years

WEIGHT
18.8 lbs

INTERPRETED BY
Eric Lindquist, DMV DABVP, Cert. IVUSS

IMAGING PERFORMED BY
Dr. McFeely

HOSPITAL NAME
Straley VA

REFERRING VET
Dr. McFeely

INVOICE
43918

DATE
4/20/23

PRESENTING CLINICAL SIGNS

History: Evvy presented recently for an exam as a new patient recently adopted from local rescue shelter. The grade III/VI cardiac murmur was found during exam and no abnormal cardiac clinical signs have been observed. Evvy also had lab work run today, she has significant periodontal disease, and a dental procedure needs to be scheduled if risk is minimal. VHS was 12.9 on chest radiographs today, and blood pressure was normal, 143/66 (79) mmHg systolic/diastolic (MAP). 1.6 mg butorphanol was given IV to lightly sedate for the cardiac ultrasound today.
Abnormal PE/Chem/CBC/UA Results: Elevated K of 6.2, Na/K ratio of 23:1 found during lab work today. A baseline cortisol was run, result was 1.2ug/dl. A fecal will be run to rule out whipworm infestation and ACTH stim test will be scheduled.

ULTRASONOGRAPHIC EXAMINATION OF THE HEART

The echocardiogram in this patient demonstrated normal **left atrial** size based on 3 separate methods of LA evaluation. Minor **mitral** valve insufficiency was noted in this patient and was centralized with a minor jet. The **left ventricle** presented thicknesses with linear contour and was not dilated nor restricted. The **myocardium** presented normal echogenicity without subjective evidence of significant fibrotic or ischemic disease. **Contractility** of the ventricular walls was adequate and in normal range for this patient evidenced by the fractional shortening measurement and subjective evaluation of the different regions of the myocardium. The **left ventricular outflow** tract demonstrated normal laminar flow and subjective structural integrity. The **right atrium** and auricle revealed normal size, structure and content. No evidence of masses was noted. **Tricuspid** valvular assessment demonstrated adequate linear morphology and kinesis. The **right ventricle** was of normal size (1/3 diameter of LV), chordae structure, myocardial echogenicity and thickness. **Pulmonary outflow** tract assessment revealed normal valve structure, laminar flow, and diameter (approx.1:1 pa/ao ratio). No visible **pericardial** or free pleura fluid was noted. The cranial **mediastinum and pericardial and extra-cardiac regions** were free of masses in the visible window. The hepatic veins were not dilated.

CANINE CARDIAC PARAMETERS	MR VMAX (m/s)	TR VMAX (m/s)	LA/AO (Boon method)	LA/AO (Heart Base;)	FS (%)	EF (%)	EPSS (cm)
NORMAL PARAMETER	4.5-5.5	<2.7	1.3	<1.6	28-40	40-100	<0.6
PATIENT			1.15	1.3	-	-	NM
CANINE CARDIAC PARAMETERS	**HR** (BPM)	**AV VMAX** (m/s)	**PV MAX** (m/s)	**BODY WEIGHT** (kg)	**LA** 2D short axis Base view (cm)	**LVIDd** Avg; 2D and m-mode short axis (cm)	**LVIDs** Avg; 2D and m-mode short axis (cm)
NORMAL PARAMETER	50-100	0.7-1.7	0.7-1.6	BELOW	BELOW	BELOW	BELOW
PATIENT			0.6	18.8 lbs	2.9	3.26	

SonoPath
Clinical Sonography & Telecytology
EDUCATIONAL TELECONSULTATION SERVICES™

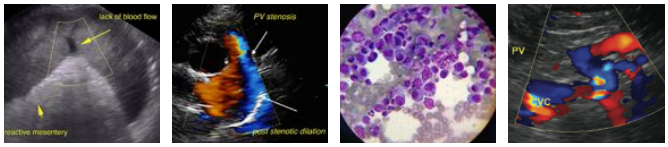

SonoPath.com™
1-800-838-4268 info@sonopath.com

PATIENT

Evvy Terpak

SPECIES

Canine

BREED

Cavalier King Charles Spaniel

SEX

Spayed female

AGE

7 years

WEIGHT

18.8 lbs

INTERPRETED BY

Eric Lindquist, DMV DABVP, Cert. IVUSS

IMAGING PERFORMED BY

Dr. McFeely

HOSPITAL NAME

Straley VA

REFERRING VET

Dr. McFeely

INVOICE

43918

DATE

4/20/23

ULTRASONOGRAPHIC FINDINGS

Stage B1 valvular disease.

INTERPRETATION OF THE FINDINGS & FURTHER RECOMMENDATIONS

The heart is stable without clinical disease. No overt contraindication for anesthesia of brief to moderate duration. I suggest Torbutrol premed, Propofol induction, Isoflo maintenance or similar protocol if anesthesia is desired. Blood pressure recommended if not already performed and target white coat negative systolic pressure of < 160 mmHg. If higher than this ACE-inhibitor is suggested to reach this level. Recheck echocardiogram is recommended in 6 months, earlier if murmur grade increases or clinical signs initiate.

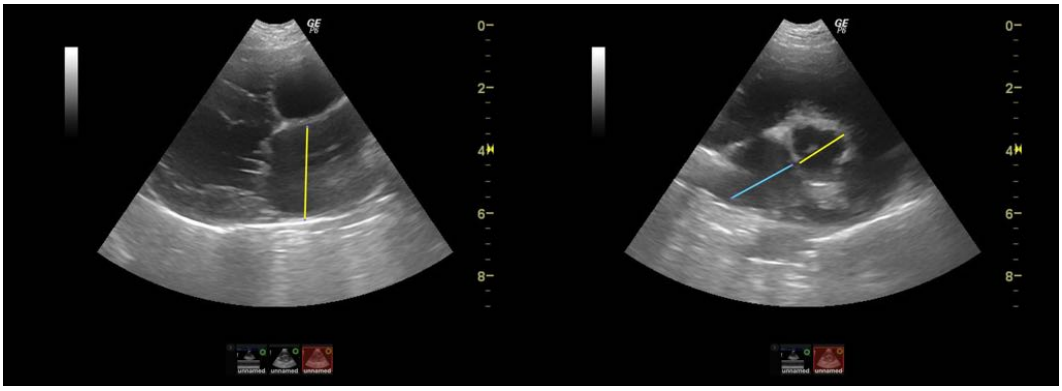

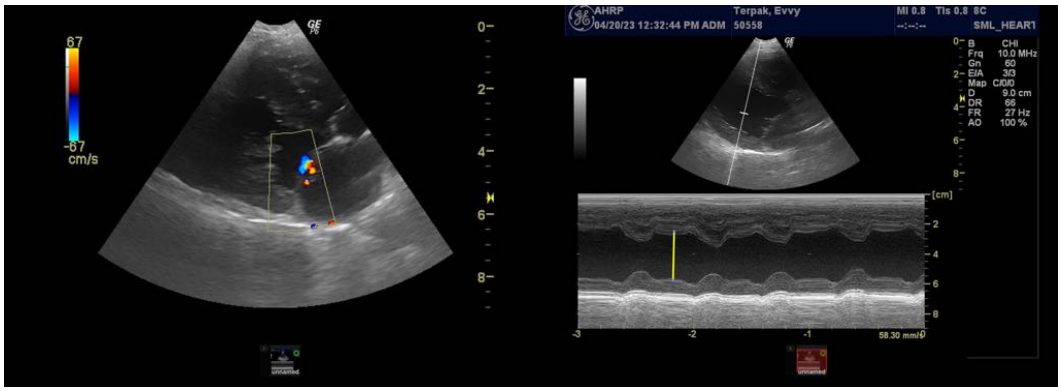

SonoPath
Clinical Sonography & Telecytology

EDUCATIONAL TELECONSULTATION SERVICES™

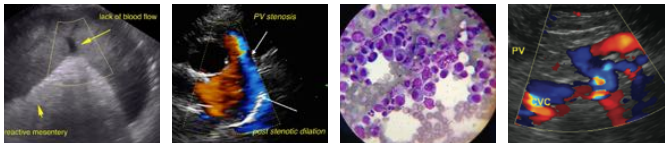

SonoPath.com™
1-800-838-4268 info@sonopath.com

PATIENT

Evvy Terpak

SPECIES

Canine

BREED

Cavalier King Charles Spaniel

SEX

Spayed female

AGE

7 years

WEIGHT

18.8 lbs

INTERPRETED BY

Eric Lindquist, DMV DABVP, Cert. IVUSS

IMAGING PERFORMED BY

Dr. McFeely

HOSPITAL NAME

Straley VA

REFERRING VET

Dr. McFeely

INVOICE

43918

DATE

4/20/23

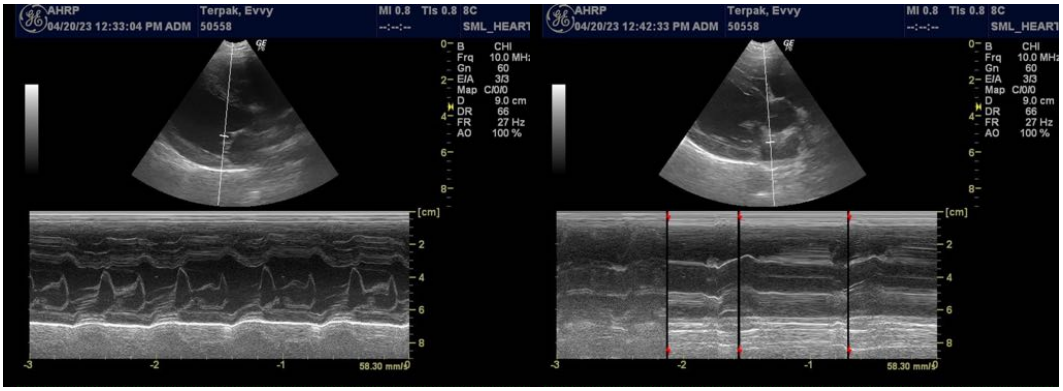

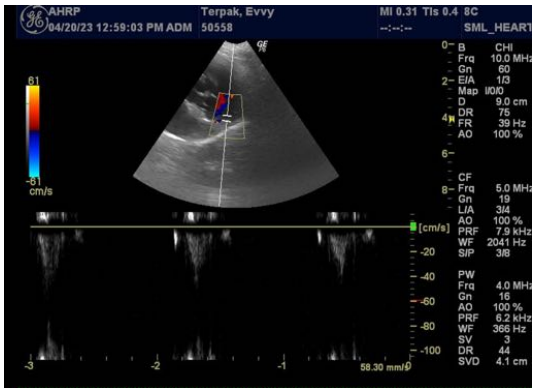

The information and recommendations provided are based on the images presented by the referring veterinarian/sonographer. No evaluation can be communicated regarding pathology that was not visible in the image/video clips provided.

Thank you for this referral. If the clinical or image interpretation does not parallel your findings or if I can be of any further assistance please contact me.

Eric Lindquist, DMV, DABVP, Cert. IVUSS, CEO of SonoPath.com
info@SonoPath.com