

PATIENT

Mia Kaleo

SPECIES

Canine

BREED

Pit Bull X

SEX

Spayed Female

AGE

5 Years

WEIGHT

86 Pounds

INTERPRETED BY

Eric Lindquist, DMV

DABVP, Cert. IVUSS

IMAGING PERFORMED BY

Dr. Tara Klimovitz

HOSPITAL NAME

Stay Pet Veterinary

REFERRING VET

Dr. Tara Klimovitz

INVOICE

37048

DATE

4/20/22

PRESENTING CLINICAL SIGNS

Acute onset hematuria during boarding stay currently - urinary only ultrasound to r/o pathology versus stress related

Abnormal PE/Chem/CBC/UA Results: Not performed

LIMITED ULTRASONOGRAPHIC EXAMINATION

Urinary System

The **urinary bladder** revealed minor apical micropolypoid changes. Anechoic urine present. The pelvic urethra was imaged 2.0 cm beyond the cystourethral junction.

The **right kidney** revealed normal size and structure, corticomedullary definition and ratio for this age. The cortices presented largely uniform texture with normal echogenic relationship to liver and spleen. Medullary structure differed distinctly from the cortex and no evidence of pelvic dilation was present. The capsules were acceptably uniform without significant irregularities. The right kidney measured 6.68 cm.

The **left kidney** measured 5.5 cm and was visualized obliquely.

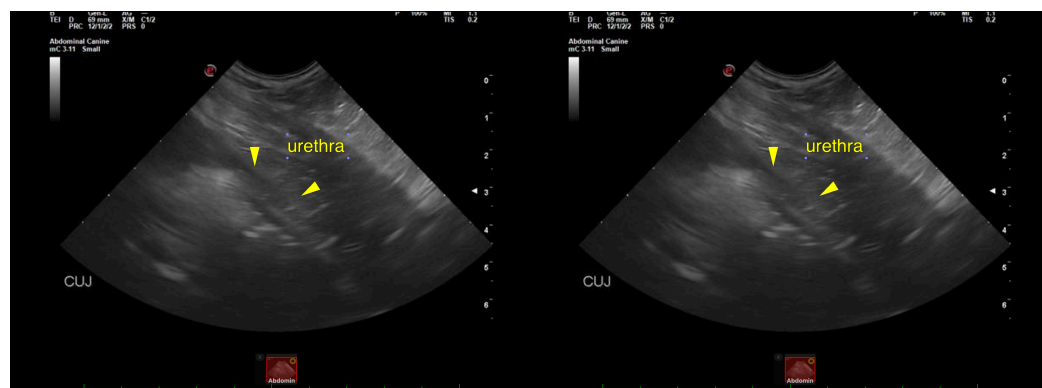
ULTRASONOGRAPHIC FINDINGS

- Minor cystitis pattern

INTERPRETATION OF THE FINDINGS & FURTHER RECOMMENDATIONS

Deep pelvic urethral pathology cannot be completely ruled out. However, the urethra 2.0 cm caudal from the cystourethral junction appeared to be unremarkable. Idiopathic cystitis, occult UTI, coagulopathy should all be considered. Cystoscopy would be ideal for further definition.

****5 still images and 8 videos received.**





PATIENT

Mia Kaleo

SPECIES

Canine

BREED

Pit Bull X

SEX

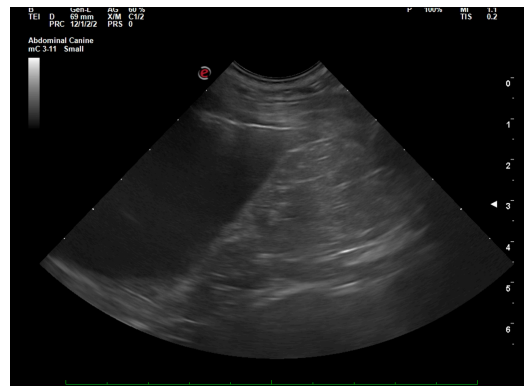
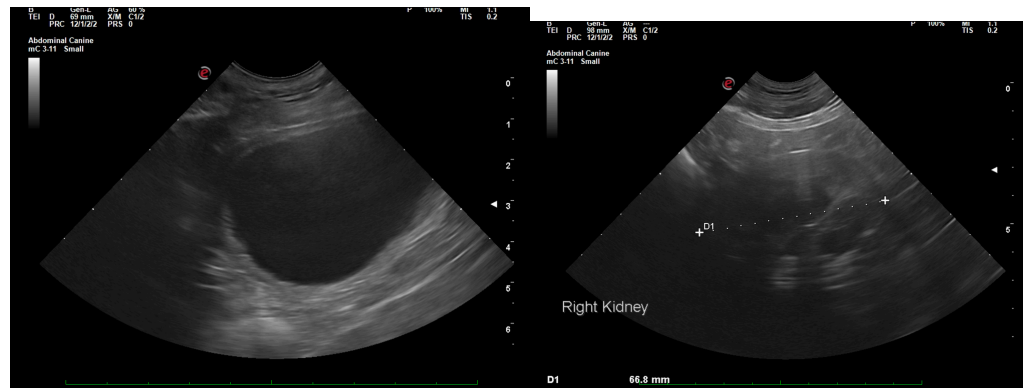
Spayed Female

AGE

5 Years

WEIGHT

86 Pounds



INTERPRETED BY

Eric Lindquist, DMV

DABVP, Cert. IVUSS

IMAGING PERFORMED BY

Dr. Tara Klimovitz

HOSPITAL NAME

Stay Pet Veterinary

REFERRING VET

Dr. Tara Klimovitz

INVOICE

37048

DATE

4/20/22

The information and recommendations provided are based on the images presented by the referring veterinarian/sonographer. No evaluation can be communicated regarding pathology that was not visible in the image/video clips provided.

Thank you for this referral. If the clinical or image interpretation does not parallel your findings or if I can be of any further assistance please contact me.

Eric Lindquist, DMV, DABVP, Cert. IVUSS, CEO of SonoPath.com

info@SonoPath.com