

PATIENT PRESENTING CLINICAL SIGNS

Jack Flores History: Recheck echo to assess anesthetic risk - B2 valvular disease. Current meds: Vetmedin 1.25mg

SPECIES ULTRASONOGRAPHIC EXAMINATION OF THE HEART

Canine

BREED

Chihuahua

Cardiac presentation in this patient presented progressive left atrial enlargement that was mildly increased compared to the prior sonogram. There was mild prolapse of the anterior mitral valve leaflet noted. There as mild left ventricular volume overload was present. Contractility was adequate. Mitral and tricuspid insufficiency was present. There was no pericardial or pleural effusion noted.

SEX

Neutered male

AGE

13 years

WEIGHT

13.33 lbs

INTERPRETED BY

Eric Lindquist, DMV
DABVP, Cert. IVUSS

CANINE CARDIAC PARAMETERS	MR VMAX (m/s)	TR VMAX (m/s)	LA/AO (Boon method)	LA/AO (Heart Base; Swe)	FS (%)	EF (%)	EPSS (cm)
NORMAL PARAMETER	4.5-5.5	<2.7	1.3	<1.3	28-40	40-100	<0.6
PATIENT	5.23	2.93	NM		52	85	NM
CANINE CARDIAC PARAMETERS	HR (BPM)	AV VMAX (m/s)	PV MAX (m/s)	BODY WEIGHT	LA (2D short axis Base view) (cm)	LVIDd (Avg; 2D and m-mode short axis) (cm)	LVIDs (Avg; 2D and m-mode short axis) (cm)
NORMAL PARAMETER	50-100	0.7-1.7	0.7-1.6				
PATIENT	165	1.56	0.9	13.33 lbs	3.7 max	3.06	

IMAGING PERFORMED BY

Jessica Miller, RDMS

ULTRASONOGRAPHIC FINDINGS

Progressed moderate, B2 valvular disease.

HOSPITAL NAME

Animal Paradise Hospital

REFERRING VET

Dr. Elshafie

INTERPRETATION OF THE FINDINGS & FURTHER RECOMMENDATIONS

There is moderate anesthetic risk in this patient at this time. I recommend adding Spironolactone at 1-2 mg/kg b.i.d. and ace inhibitor at 0.5 mg/kg s.i.d. progressing to b.i.d. Recheck BUN, creatinine, chest radiographs, respiratory rate and clinical exam in 10 days. Ideally an echocardiogram would be performed at that time. Regardless, there will likely be mild anesthetic risk. Eventual protocol would be Torbutrol pre med, Propofol induction and Isoflurane maintenance with minimal anesthetic time necessary to complete the procedure.

INVOICE

99410

DATE

4/20/22



PATIENT

Jack Flores

SPECIES

Canine

BREED

Chihuahua

SEX

Neutered male

AGE

13 years

WEIGHT

13.33 lbs

INTERPRETED BY

Eric Lindquist, DMV
DABVP, Cert. IVUSS

**IMAGING
PERFORMED BY**

Jessica Miller, RDMS

HOSPITAL NAME

Animal Paradise
Hospital

REFERRING VET

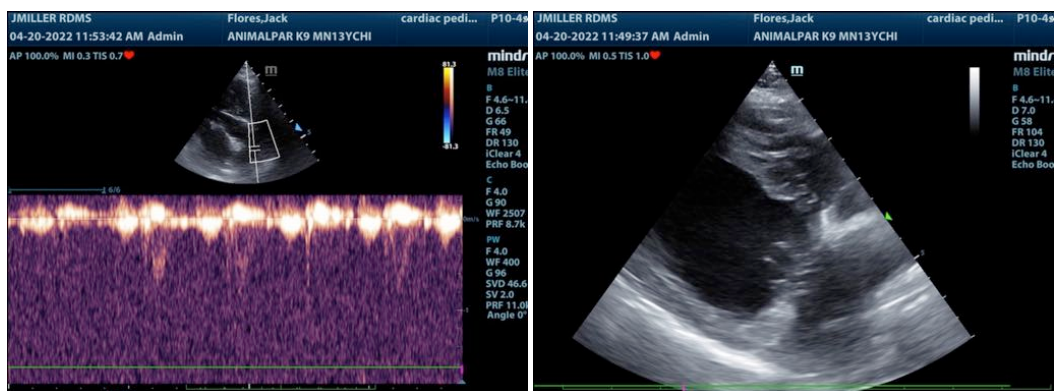
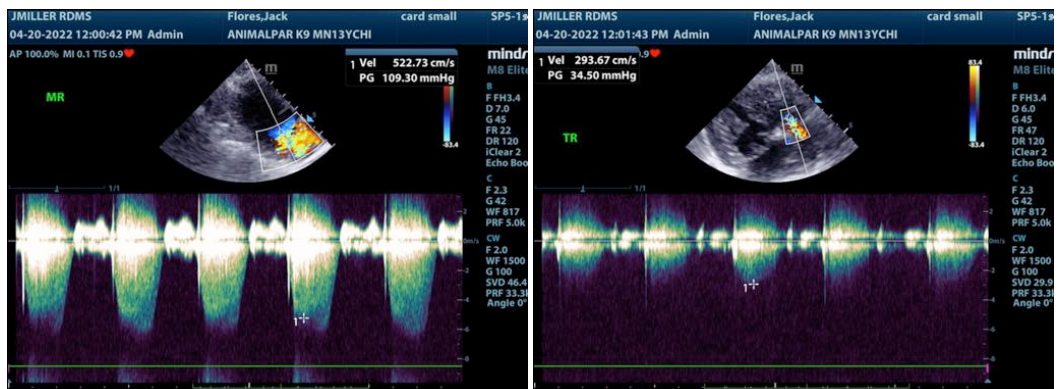
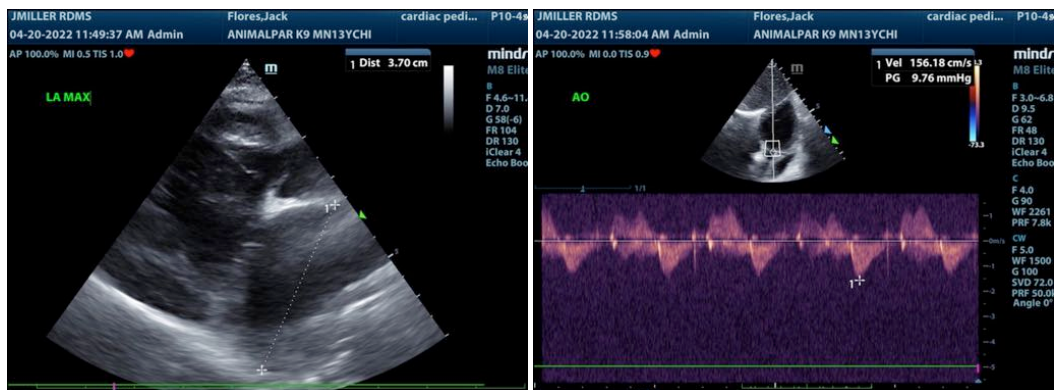
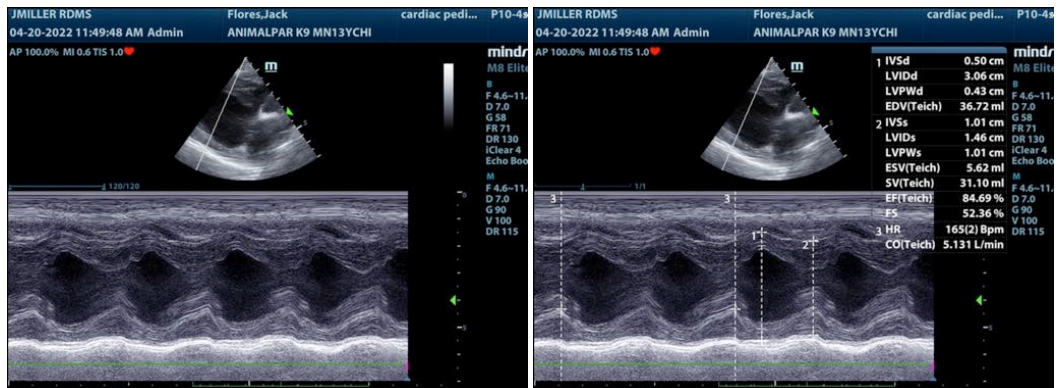
Dr. Elshafie

INVOICE

99410

DATE

4/20/22





PATIENT

Jack Flores

The information and recommendations provided are based on the images presented by the referring veterinarian/sonographer. No evaluation can be communicated regarding pathology that was not visible in the image/video clips provided.

SPECIES

Canine

Thank you for this referral. If the clinical or image interpretation does not parallel your findings or if I can be of any further assistance please contact me.

Eric Lindquist, DMV, DABVP, Cert. IVUSS, CEO of SonoPath.com
info@SonoPath.com

BREED

Chihuahua

SEX

Neutered male

AGE

13 years

WEIGHT

13.33 lbs

INTERPRETED BY

Eric Lindquist, DMV
DABVP, Cert. IVUSS

**IMAGING
PERFORMED BY**

Jessica Miller, RDMS

HOSPITAL NAME

Animal Paradise
Hospital

REFERRING VET

Dr. Elshafie

INVOICE

99410

DATE

4/20/22