



PATIENT

Abby Kaufman

PRESENTING CLINICAL SIGNS

Prev. hx of cutaneous hemangiosarcoma. Now has grade IV-V/VI mitral area murmur not heard previously. Has been salivating and not eating well.

SPECIES

Canine

ULTRASONOGRAPHIC EXAMINATION OF THE HEART

The echocardiogram in this patient demonstrated enlarged **left atrial** size based on 3 different LA measurement methods. Chamber volumes and echogenicity were normal. The cranial and caudal **mitral** valve leaflets presented vegetative thickening consistent with endocardiosis. Doppler indicated measurable insufficiency. The **left ventricle** presented thicknesses with linear contour and was not dilated nor restricted. The **myocardium** presented normal echogenicity without subjective evidence of significant fibrotic or ischemic disease. **Contractility** of the ventricular walls was adequate and in normal range for this patient evidenced by the fractional shortening measurement and subjective evaluation of the different regions of the myocardium. The **left ventricular outflow** tract demonstrated normal laminar flow and subjective structural integrity. The **right atrium** and auricle revealed normal size, structure and content. No evidence of masses was noted or chamber overload. Minor **tricuspid** insufficiency was noted and measured 2.4 m/sec. The **right ventricle** was of normal size (1/3 diameter of LV), chordae structure, myocardial echogenicity and thickness. **Pulmonic** tract assessment revealed normal valve structure, laminar flow, and diameter (approx. 1:1 pa/ao ratio). No visible **pericardial** or free pleura fluid was noted. No echographically detectable evidence of infiltrative disease was visible. The cranial **mediastinum and pericardial regions** were free of masses in the visible window. Occasional arrhythmia was noted in this patient.

BREED

Mix

SEX

Spayed Female

AGE

9 years

WEIGHT

58 lbs

INTERPRETED BY

Eric Lindquist, DMV
DABVP, Cert. IVUSS

IMAGING PERFORMED BY

Shari Reffi, CVT

HOSPITAL NAME

Animal General
(Augusta)

REFERRING VET

Dr. Castimore

CANINE CARDIAC PARAMETERS	MR VMAX (m/s)	TR VMAX (m/s)	LA/AO (Boon method)	LA/AO (Heart Base; Swe)	FS (%)	EF (%)	EPSS (cm)
NORMAL PARAMETER	4.5-5.5	<2.7	1.3	<1.3	28-40	40-100	<0.6
PATIENT	5.61	2.4	1.5	1.42	40	70	0.2
CANINE CARDIAC PARAMETERS	HR (BPM)	AV VMAX (m/s)	PV MAX (m/s)	BODY WEIGHT	LA 2D short axis Base view (cm)	LVIDd Avg; 2D and m-mode short axis (cm)	LVIDs Avg; 2D and m-mode short axis (cm)
NORMAL PARAMETER	50-100	0.7-1.7	0.7-1.6				
PATIENT	145	1.51	0.96	58 lbs	5.72	5.15	

INVOICE

99414

DATE

4/20/22

ULTRASONOGRAPHIC FINDINGS

Mitral and tricuspid insufficiency.

Stage B2 + valvular disease with left atrial enlargement.

Occasional arrhythmia.



PATIENT

Abby Kaufman

SPECIES

Canine

BREED

Mix

SEX

Spayed Female

AGE

9 years

WEIGHT

58 lbs

INTERPRETED BY

Eric Lindquist, DMV
DABVP, Cert. IVUSS

IMAGING PERFORMED BY

Shari Reffi, CVT

HOSPITAL NAME

Animal General
(Augusta)

REFERRING VET

Dr. Castimore

INVOICE

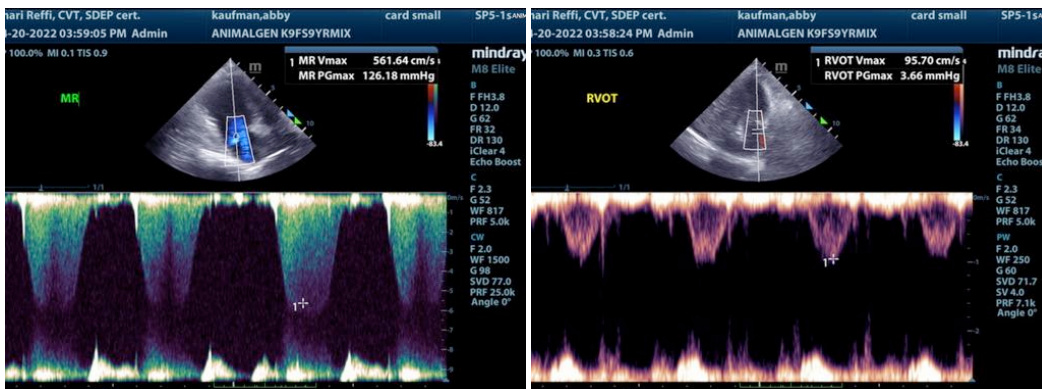
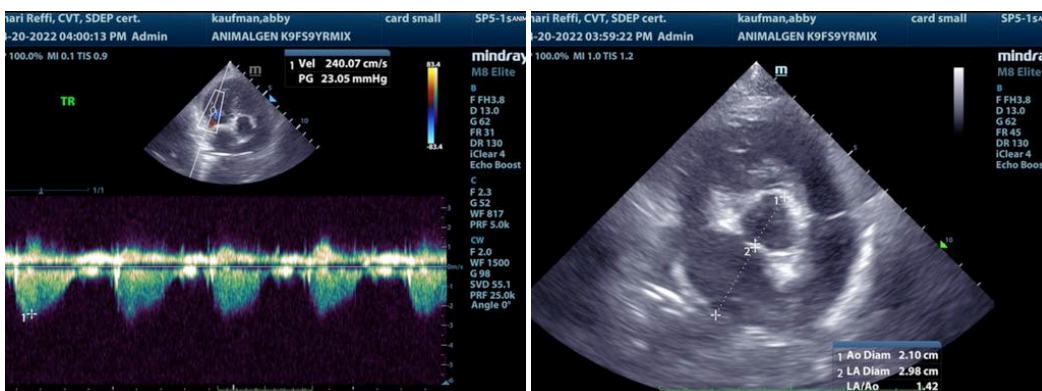
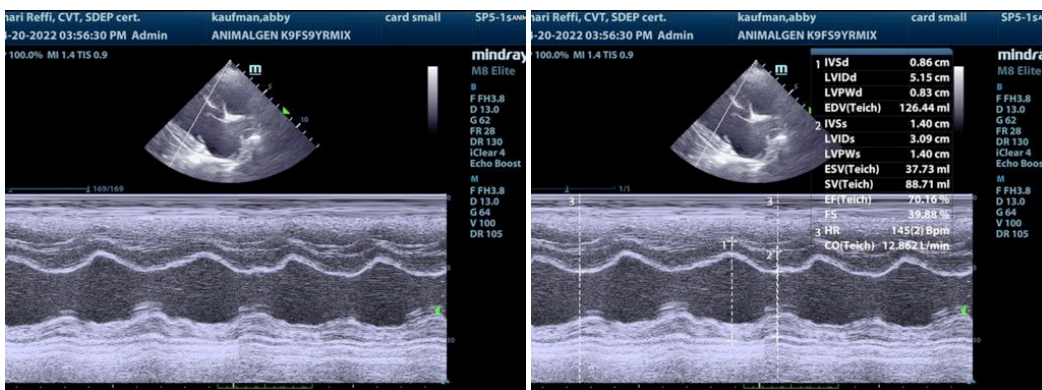
99414

DATE

4/20/22

INTERPRETATION OF THE FINDINGS & FURTHER RECOMMENDATIONS

I recommend blood pressure measurements, Pimobendan at 0.3 mg/kg b.i.d., ace inhibitor at 0.5 mg/kg s.i.d. progressing to b.i.d. and Spironolactone at 1-2 mg/kg b.i.d. A recheck echocardiogram is recommended in a month. I am concerned for emerging left-sided heart failure in this patient. EKG is indicated given the occasional arrhythmia noted long lead 2 would be indicated. There was no evidence of masses or pericardial effusion.





PATIENT

Abby Kaufman

SPECIES

Canine

BREED

Mix

SEX

Spayed Female

AGE

9 years

WEIGHT

58 lbs

INTERPRETED BY

Eric Lindquist, DMV
DABVP, Cert. IVUSS

IMAGING PERFORMED BY

Shari Reffi, CVT

HOSPITAL NAME

Animal General
(Augusta)

REFERRING VET

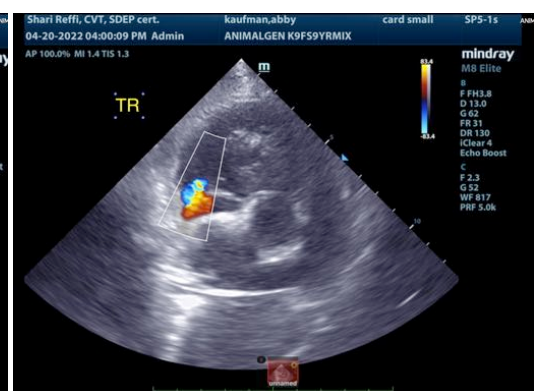
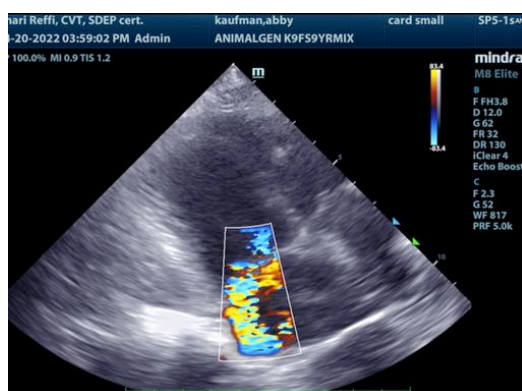
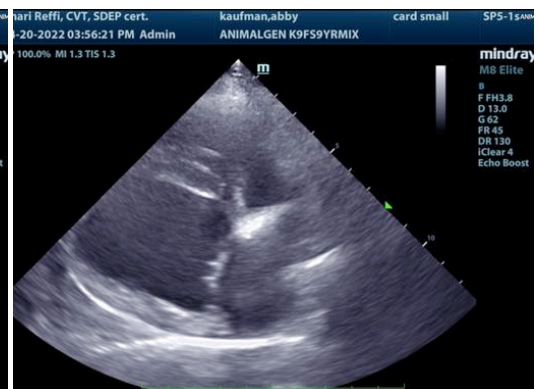
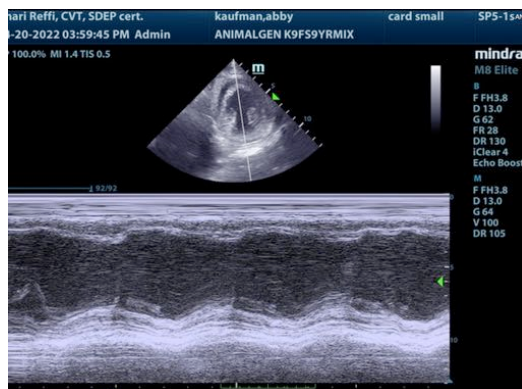
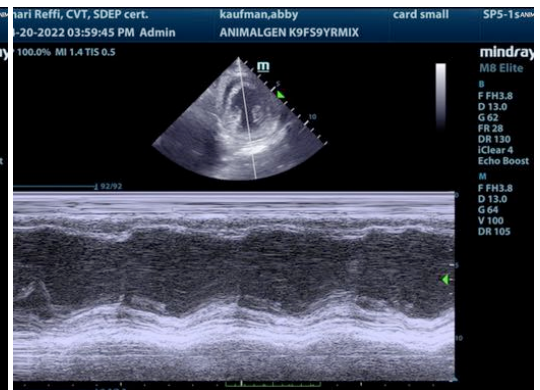
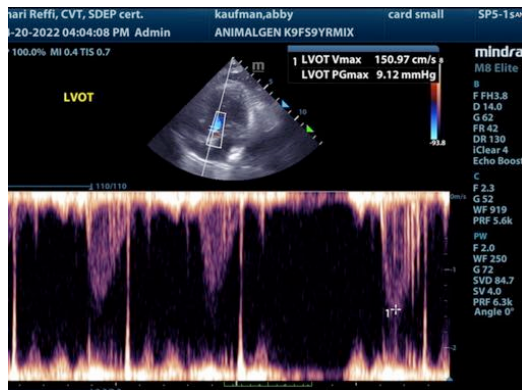
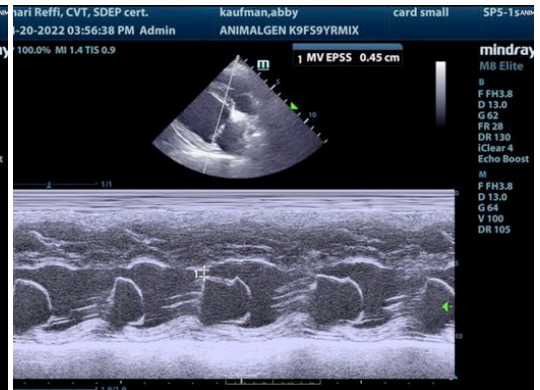
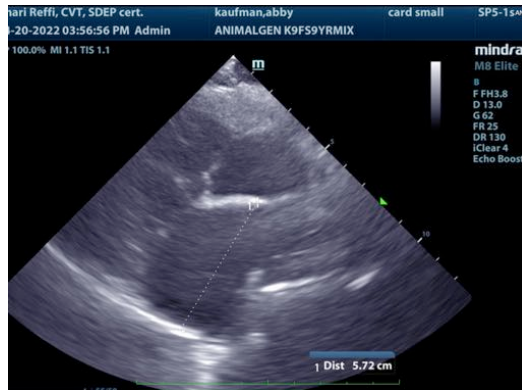
Dr. Castimore

INVOICE

99414

DATE

4/20/22





PATIENT

Abby Kaufman

The information and recommendations provided are based on the images presented by the referring veterinarian/sonographer. No evaluation can be communicated regarding pathology that was not visible in the image/video clips provided.

SPECIES

Canine

Thank you for this referral. If the clinical or image interpretation does not parallel your findings or if I can be of any further assistance please contact me.

BREED

Mix

Eric Lindquist, DMV, DABVP, Cert. IVUSS, CEO of SonoPath.com
Info@SonoPath.com

SEX

Spayed Female

AGE

9 years

WEIGHT

58 lbs

INTERPRETED BY

Eric Lindquist, DMV
DABVP, Cert. IVUSS

**IMAGING
PERFORMED BY**

Shari Reffi, CVT

HOSPITAL NAME

Animal General
(Augusta)

REFERRING VET

Dr. Castimore

INVOICE

99414

DATE

4/20/22