



PATIENT

Peggy Strunz

SPECIES

Canine

BREED

Puggle

SEX

Spayed female

AGE

12 years

WEIGHT

50 lbs

INTERPRETED BY

Eric Lindquist, DMV
DABVP, Cert. IVUSS

IMAGING PERFORMED BY

Dr. Cerf

HOSPITAL NAME

VC Hardyston

REFERRING VET

Dr. Cerf

INVOICE

74106

DATE

4/2/26

PRESENTING CLINICAL SIGNS

- Chronic Coughing
- CBC: Inflammatory Leukogram CHEM: ALT: 553 ALP: 1690

ULTRASONOGRAPHIC EXAMINATION OF THE ABDOMEN

Urinary System

The **urinary bladder**, trigone, and pelvic urethra presented normal thicknesses and normal tone. The ureters were not visible which is normal. No uroliths or sediment were visualized and anechoic urine was present. No evidence of inflammatory or neoplastic changes was noted. Ureteral papillae were normal.

The **kidneys** revealed largely normal size and structure, corticomedullary definition and ratio (cortex 1/3 of medulla) were essentially maintained with some age-related loss of curvilinear patterns regarding the capsule and C/M junction. The cortices presented largely uniform texture with some increased echogenicity expected for this age patient. Medullary structure differed distinctly from that of the cortex and no evidence of pelvic dilation was present. Slight pinpoint mineralization was noted. The left kidney measured 5.7 cm. The right kidney measured 5.4 cm.

Adrenal Glands

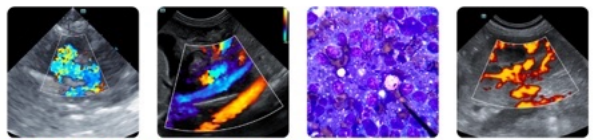
Both **adrenal glands** were visualized and recognized as having normal shape, size, position and echogenicity for this breed. The phrenic vasculature, glandular echogenicity and detail were unremarkable. Capsule, cortex, and medullary definition were normal for this age patient. The left adrenal gland measured 0.54 cm. The right adrenal gland measured 1.0 cm at the cranial pole and 0.5 cm at the caudal pole.

Spleen

The **spleen** presented a smooth homogeneous parenchyma hyperechoic to liver and renal cortical parenchyma. The capsule was smooth without noticeable expansion or deviation from within the spleen or adjacent pathology. The splenic vasculature demonstrated normal volume without signs of congestion or thrombosis. No sonographic evidence of acute or chronic inflammatory, neoplastic, or infarctual changes was noted.

Liver

The **liver** was enlarged with multi-focal, hypoechoic nodular changes. The parenchyma is hyperechoic. The gallbladder revealed a minor amount of debris.



PATIENT

Gastrointestinal

Peggy Strunz

Examination of the **gastrointestinal tract** revealed a stomach and intestine free of stasis, of normal wall thickness, acceptable curvilinear mural detail, and peristaltic activity. Small and large intestine demonstrated normal luminal chyme and stool consistency respectively. No obstructive or overt infiltrative disease was noted. No associated abnormal lymphatic activity was noted.

SPECIES

Canine

BREED

Pancreas

Puggle

The base and limbs of the **pancreas** were observed to be largely isoechoic to surrounding omental fat. Pancreatic duct and capsular contour were acceptably normal and parenchyma respected normal curvilinear patterns. No overt evidence of active inflammatory or neoplastic disease was noted.

SEX

Spayed female

AGE

12 years

ULTRASONOGRAPHIC FINDINGS

Subjectively benign hepatopathy with nodular hyperplasia pattern.

WEIGHT

50 lbs

INTERPRETATION OF THE FINDINGS & FURTHER RECOMMENDATIONS

INTERPRETED BY

Eric Lindquist, DMV
DABVP, Cert. IVUSS

FNA of the liver is indicated for further definition. This is subjectively benign.

IMAGING PERFORMED BY

Dr. Cerf

HOSPITAL NAME

VC Hardyston

REFERRING VET

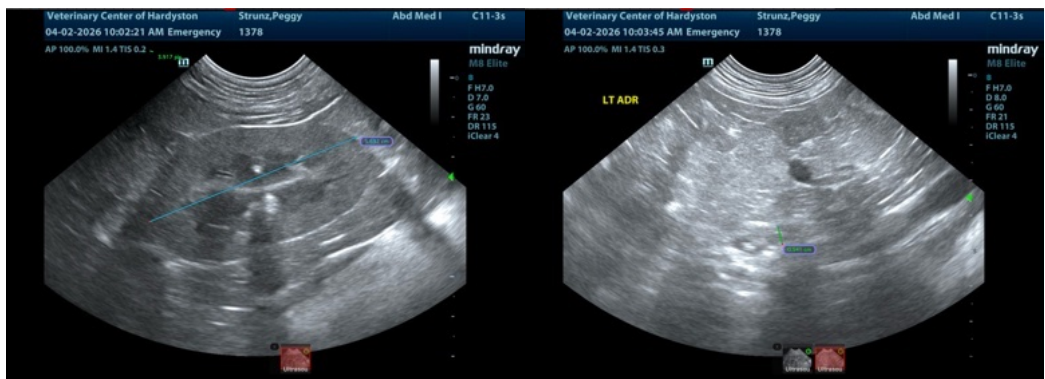
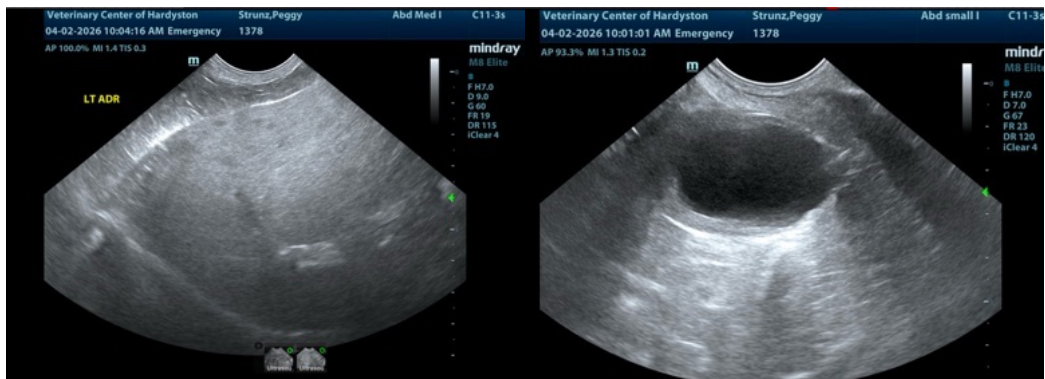
Dr. Cerf

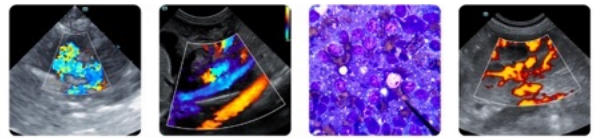
INVOICE

74106

DATE

4/2/26





PATIENT

Peggy Strunz

SPECIES

Canine

BREED

Puggle

SEX

Spayed female

AGE

12 years

WEIGHT

50 lbs

INTERPRETED BY

Eric Lindquist, DMV
DABVP, Cert. IVUSS

IMAGING PERFORMED BY

Dr. Cerf

HOSPITAL NAME

VC Hardyston

REFERRING VET

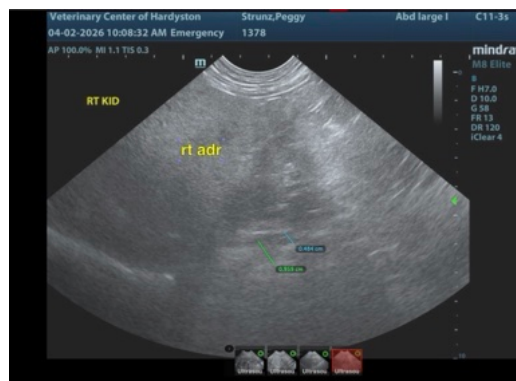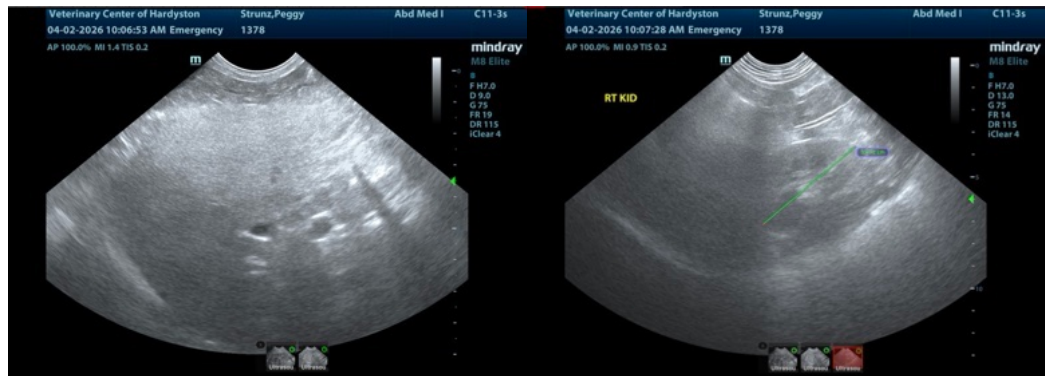
Dr. Cerf

INVOICE

74106

DATE

4/2/26



The information and recommendations provided are based on the images presented by the referring veterinarian/sonographer. No evaluation can be communicated regarding pathology that was not visible in the image/video clips provided.

Thank you for this referral. If the clinical or image interpretation does not parallel your findings or if I can be of any further assistance please contact me.

Eric Lindquist, DMV, DABVP (CFM), Cert. IVUSS, CEO of SonoPath.com

info@SonoPath.com