



## PATIENT

Nola Cain

## SPECIES

Canine

## BREED

Pit Mix

## SEX

Spayed Female

## AGE

11 Years

## WEIGHT

56 pounds

## INTERPRETED BY

Eric Lindquist, DMV,  
DABVP(CFM), Cert.  
IVUSS

## IMAGING PERFORMED BY

Keisha Smitley CVT

## HOSPITAL NAME

Geary Veterinary  
Services

## REFERRING VET

Dr. Curtis Geary VMD

## INVOICE

14787

## DATE

04/02/26

## PRESENTING CLINICAL SIGNS

Patient has been ADR for the past few months with vomiting 1-2 times a week with a decreased appetite.

CBC - Non-Regenerative Anemia Low Albumin BW and Urine Attached PT and PTT normal

## ULTRASONOGRAPHIC EXAMINATION OF THE ABDOMEN

### Urinary System

The **urinary bladder**, trigone, and pelvic urethra presented normal thicknesses and normal tone. The ureters were not visible which is normal. No uroliths or sediment were visualized, and anechoic urine was present. No evidence of inflammatory or neoplastic changes were noted. Ureteral papillae were normal.

The **iliac trifurcation** was unremarkable.

The **kidneys** revealed normal size and structure, corticomedullary definition and ratio for this age. The cortices presented largely uniform texture with normal echogenic relationship to liver and spleen. Medullary structure differed distinctly from the cortex and no evidence of pelvic dilation was present. The capsules were acceptably uniform without significant irregularities. The left kidney measured 5.3 cm in length. The right kidney measured 5.7 cm in length.

### Adrenal Glands

Both **adrenal glands** were visualized and recognized as having normal shape, size, position and echogenicity for this breed. The phrenic vasculature, glandular echogenicity and detail were unremarkable. Capsule, cortex, and medullary definition were normal for this age patient. The left adrenal gland measured 0.57 cm width at the caudal pole and 0.57 cm width at the cranial pole. The right adrenal gland measured 1.2 cm width at the cranial pole and 0.58 cm width at the caudal pole.

### Spleen

The **spleen** presented enlarged and heterogenous with hypoechoic nondisruptive nodular changes. The spleen was folded upon itself cranially. The largest nodule measured 1.3 cm. Subtle micronodular changes were noted elsewhere. A mixed hypoechoic splenic mass was noted measuring 2.5 cm.

### Liver

The **liver** images from right and left intercostal as well as subcostal views revealed subjectively normal liver size, contour, and structure. Some mild age-related parenchymal remodeling was noted but likely not clinically significant at this time. Vascular and biliary tracts were of normal volume and no evidence of congestion was noted. The gallbladder presented some dependent debris with essentially normal contour. The cystic and common bile ducts were normal. No overt evidence of active inflammatory, infiltrative or regenerative pathology was noted but should be paired with current or past LE elevations regarding any clinical significance to this presentation. The hepatic lymph nodes were unremarkable.

### Gastrointestinal



## PATIENT

Nola Cain

## SPECIES

Canine

## BREED

Pit Mix

## SEX

Spayed Female

## AGE

11 Years

## WEIGHT

56 pounds

## INTERPRETED BY

Eric Lindquist, DMV,  
DABVP(CFM), Cert.  
IVUSS

## IMAGING PERFORMED BY

Keisha Smitley CVT

## HOSPITAL NAME

Geary Veterinary  
Services

## REFERRING VET

Dr. Curtis Geary VMD

## INVOICE

14787

## DATE

04/02/26

The **gastrointestinal** presentation revealed mild uniform prominence of the gastric mucosa as well as areas of "ropy" small intestinal wall with slight disruption of the normal 1:3 muscularis/mucosal ratio. The intestinal submucosa was slightly irregular, thickened and hyperechoic suggestive of low grade, chronic disease. No concerning lymphadenopathy was visible. No evidence of obstruction was present. Chronic inflammatory bowel disease is likely with a low possibility of an early neoplastic event such as lymphoma. Full thickness tissue biopsies via open laparotomy, ideally guided by intraoperative ultrasound in order to obtain the most representative mural sample, would be necessary to rule out this possibility.

### **Pancreas**

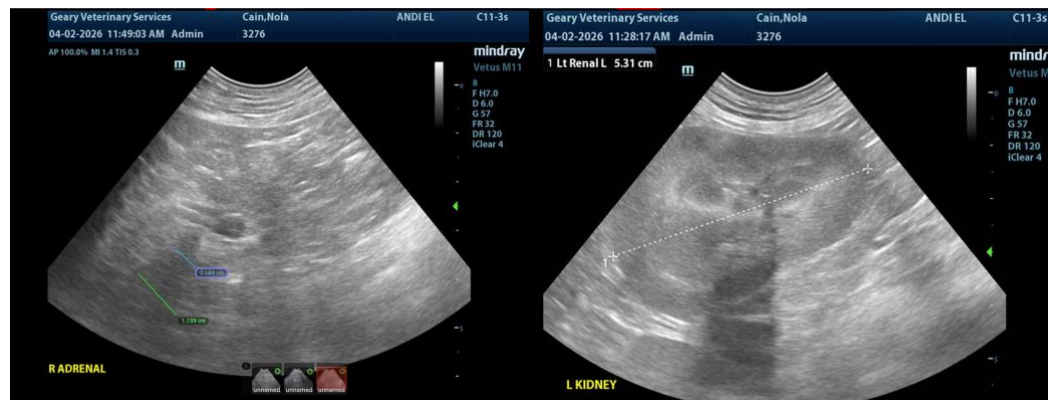
The base and limbs of the **pancreas** were observed to be largely isoechoic to surrounding omental fat. Pancreatic duct and capsular contour were acceptably normal and parenchyma respected normal curvilinear patterns. No overt evidence of active inflammatory or neoplastic disease was noted.

### **ULTRASONOGRAPHIC FINDINGS**

- Splenic enlargement with nodules and mass formation.
- Minor intestinal thickening- strong concern for round cell neoplasia.

### **INTERPRETATION OF THE FINDINGS & FURTHER RECOMMENDATIONS**

If the liver is free of evident pathology, proactive splenectomy could be considered, however would not directly explain the anemia in this patient. CBC path review with bone marrow aspirate would be indicated prior to surgery to assess for concurrent bone marrow disease as well as chest radiographs and echocardiogram to assess for metastatic disease. Prognosis is guarded.





## PATIENT

Nola Cain

## SPECIES

Canine

## BREED

Pit Mix

## SEX

Spayed Female

## AGE

11 Years

## WEIGHT

56 pounds

## INTERPRETED BY

Eric Lindquist, DMV,  
DABVP(CFM), Cert.  
IVUSS

## IMAGING PERFORMED BY

Keisha Smitley CVT

## HOSPITAL NAME

Geary Veterinary  
Services

## REFERRING VET

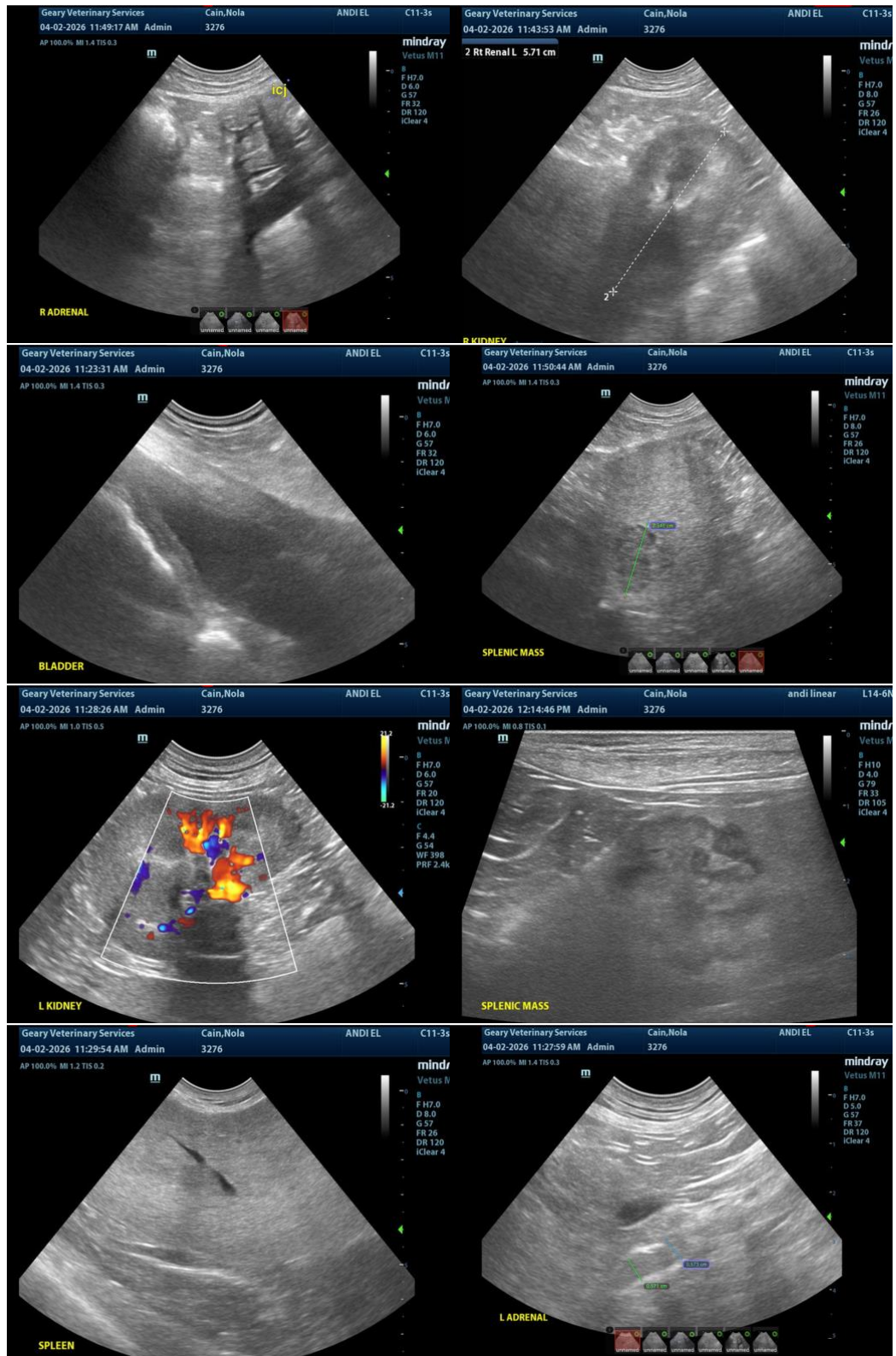
Dr. Curtis Geary VMD

## INVOICE

14787

## DATE

04/02/26





## PATIENT

Nola Cain

## SPECIES

Canine

## BREED

Pit Mix

## SEX

Spayed Female

## AGE

11 Years

## WEIGHT

56 pounds

## INTERPRETED BY

Eric Lindquist, DMV,  
DABVP(CFM), Cert.  
IVUSS

## IMAGING PERFORMED BY

Keisha Smitley CVT

## HOSPITAL NAME

Geary Veterinary  
Services

## REFERRING VET

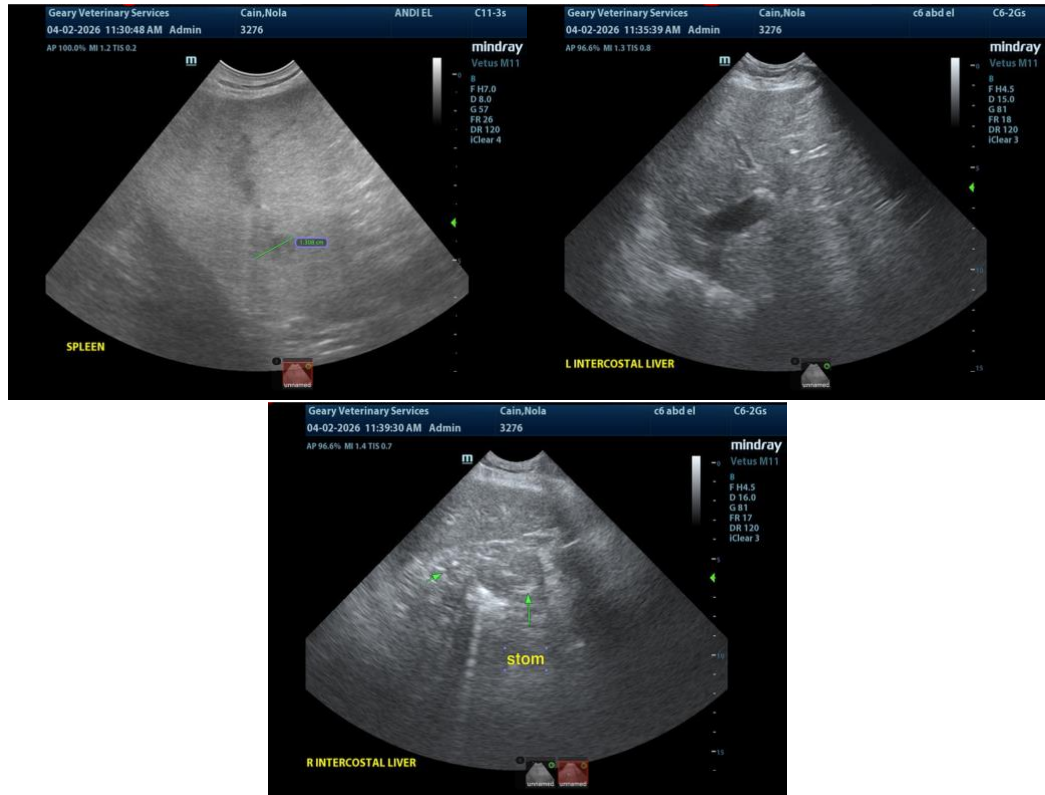
Dr. Curtis Geary VMD

## INVOICE

14787

## DATE

04/02/26



The information and recommendations provided are based on the images presented by the referring veterinarian/sonographer. No evaluation can be communicated regarding pathology that was not visible in the image/video clips provided.

Thank you for this referral. If the clinical or image interpretation does not parallel your findings or if I can be of any further assistance, please contact me.

**Eric Lindquist, DMV, DABVP(CFM), Cert. IVUSS,**

CEO, Owner, Founder -- SonoPath.com

[info@SonoPath.com](mailto:info@SonoPath.com)