**PATIENT**

Indigo Lynch

SPECIES

Feline

BREED

Domestic Shorthair

SEX

Spayed Female

AGE

1 Year 1 Month

WEIGHT

6.7 Pounds

INTERPRETED BYEric Lindquist, DMV
DABVP, Cert. IVUSS**IMAGING PERFORMED BY**

Tom McNeill

HOSPITAL NAME

SVS Imaging CT

REFERRING VETAdvanced AH- Dr.
Schnuelle**INVOICE**

14561

DATE

4/2/22

PRESENTING CLINICAL SIGNS

History: Presented on 2/21/22 for vomiting and diarrhea Since 2/21/22 through 3/21/22 - inappetence Abnormal PE/Chem/CBC/UA Results: Radiographs: Assessment: Small kidneys. Considerations include congenital anomaly, anatomical variant, and chronic renal disease. The influence of potential renal disease on reported vomiting is unclear. While small intestinal loops are at the upper limits of normal for size, a mechanical obstruction was not confirmed on this exam. A functional ileus is not excluded. Gastroenteritis, +/- pancreatitis is a consideration. Consider a fPLI or PSL test if pancreatitis is of concern. Based on the young age of this patient, rule out parasitism. Senior Profile: kidney enzymes on high end of normal

ULTRASONOGRAPHIC EXAMINATION OF THE ABDOMEN**Urinary System**

The **urinary bladder**, trigone, and pelvic urethra presented normal thicknesses and normal tone. The ureters were not visible which is normal. No uroliths or sediment were visualized and anechoic urine was present. No evidence of inflammatory or neoplastic changes were noted. Ureteral papillae were normal.

The **kidneys** revealed largely normal size and structure, corticomedullary definition and ratio (cortex 1/3 of medulla) were essentially maintained with some mild age-related loss of curvilinear patterns regarding the capsule and C/M junction. The cortices presented largely uniform texture with some increased echogenicity expected for his age patient. Medullary structure differed distinctly from that of the cortex and no evidence of pelvic dilation was present. The left kidney measured 2.77 cm. The right kidney measured 3.11 cm.

Adrenal Glands

Both **adrenal glands** were visualized and recognized as having normal shape, size, position and echogenicity for this breed. The phrenic vasculature, glandular echogenicity and detail were unremarkable. Capsule, cortex, and medullary definition were normal for this age patient. The right adrenal gland measured 0.32 cm. The left adrenal gland measured 0.34 cm.

Spleen

The **spleen** presented a smooth homogeneous parenchyma hyperechoic to liver and renal cortical parenchyma. The capsule was smooth without noticeable expansion or deviation from within the spleen or adjacent pathology. The splenic vasculature demonstrated normal volume without signs of congestion or thrombosis. No sonographic evidence of acute or chronic inflammatory, neoplastic, or infarctual changes were noted.

Liver

The **liver** images from right and left intercostal as well as subcostal views revealed subjectively normal liver size, contour, and structure. Some age-related parenchymal remodeling was noted but likely not clinically significant at this time. Vascular and biliary tracts were of normal volume and no evidence of congestion was noted. The gallbladder presented some dependent debris with essentially normal contour. The cystic and common bile ducts were normal. No overt evidence of active inflammatory, infiltrative or regenerative pathology was noted but should be paired with current or past LE

**PATIENT**

Indigo Lynch

elevations regarding any clinical significance to this presentation. The hepatic lymph nodes were unremarkable. Minor vestigial secondary gallbladder noted, not pathological.

Gastrointestinal**SPECIES**

Feline

The **gastrointestinal** presentation revealed mild uniform prominence of the gastric mucosa as well as areas of "ropey" small intestinal wall. Muscularis/mucosal ratio was 1:1. The intestinal submucosa was slightly irregular, thickened and hyperechoic suggestive of low grade, chronic disease. Chronic inflammatory bowel disease is likely with a low possibility of an early neoplastic event such as lymphoma. Full thickness tissue biopsies via open laparotomy, ideally guided by intraoperative ultrasound in order to obtain the most representative mural sample, would be necessary to rule out this possibility. Some progressively shadowing material was noted in the stomach, likely hairball accumulation.

BREED

Domestic Shorthair

SEX

Spayed Female

AGE

1 Year 1 Month

Pancreas

The base and limbs of the **pancreas** were observed to be largely isoechoic to surrounding omental fat. Some mild parenchymal remodeling, however, with mild deviation from curvilinear normalcy was observed. Pancreatic duct and capsular irregularities were present consistent with age related changes. If pain upon imaging (+ Murphy sign) was present or if the patient is focally painful in subxyphoid palpation then low-grade smoldering chronic pancreatitis should be suspected.

WEIGHT

6.7 Pounds

Free Abdomen

The mesenteric **lymph nodes** (up to 0.61 cm in width) presented normal length to width ratio with slight, swollen contour. There was no loss of parenchymal detail. This is most consistent with reactive lymphadenitis or lymphatic hyperplasia.

INTERPRETED BYEric Lindquist, DMV
DABVP, Cert. IVUSS

An epigastric **lymph node** was mildly enlarged, measuring up to 0.58 cm.

ULTRASONOGRAPHIC FINDINGS**IMAGING PERFORMED BY**

Tom McNeill

- Mesenteric lymphadenopathy
- Variable intestinal thickening with likely hairball accumulation
- Age-related hepatic changes with minor vestigial secondary gallbladder noted, not pathological.
- Age-related renal and pancreatic changes

HOSPITAL NAME

SVS Imaging CT

INTERPRETATION OF THE FINDINGS & FURTHER RECOMMENDATIONS

Inflammatory bowel/lymphadenitis type presentation with likely hairball accumulation. Possibility of emerging pre-neoplastic presentation with emerging lymphoma. This would necessitate full thickness biopsies for further definition. Hairball therapy warranted and empirical treatment for inflammatory bowel. A clinical trial of the following could be considered.

REFERRING VETAdvanced AH- Dr.
Schnuelle**Triaditis/Pancreatitis protocol****INVOICE**

14561

Part or all of this protocol may be considered based on your clinical impression of the patient:

DATE

4/2/22

Recommend pain management when anorexic with **Buprenorphine** (0.01-0.02 mg/kg IM or SC), clinical trial of **Zithromax** (50 mg sid/cat x 10 days, 3 weeks if bartonella +), **Prednisolone** (0.5-2 mg/kg tapering over 1 week to minimal effective dose), and **B12 injections** if weight

IMAGING PERFORMED BY

SVS Mobile Imaging CT 262-366-5970
fredgromalak@gmail.com



Clinical Sonography & Telecytology

EDUCATIONAL TELECONSULTATION SERVICES™

1-800-838-4268 info@sonopath.com SonoPath.com

PATIENT

Indigo Lynch

SPECIES

Feline

BREED

Domestic Shorthair

SEX

Spayed Female

AGE

1 Year 1 Month

WEIGHT

6.7 Pounds

INTERPRETED BY

Eric Lindquist, DMV
DABVP, Cert. IVUSS

IMAGING PERFORMED BY

Tom McNeill

HOSPITAL NAME

SVS Imaging CT

REFERRING VET

Advanced AH- Dr.
Schnuelle

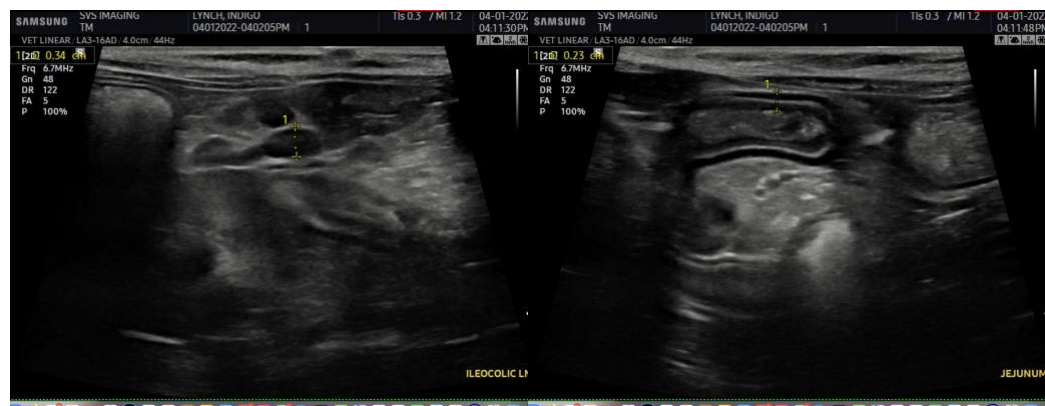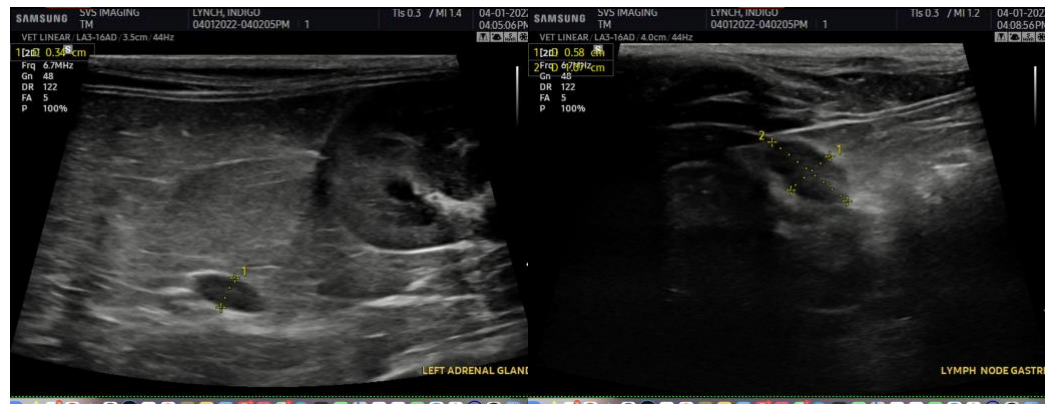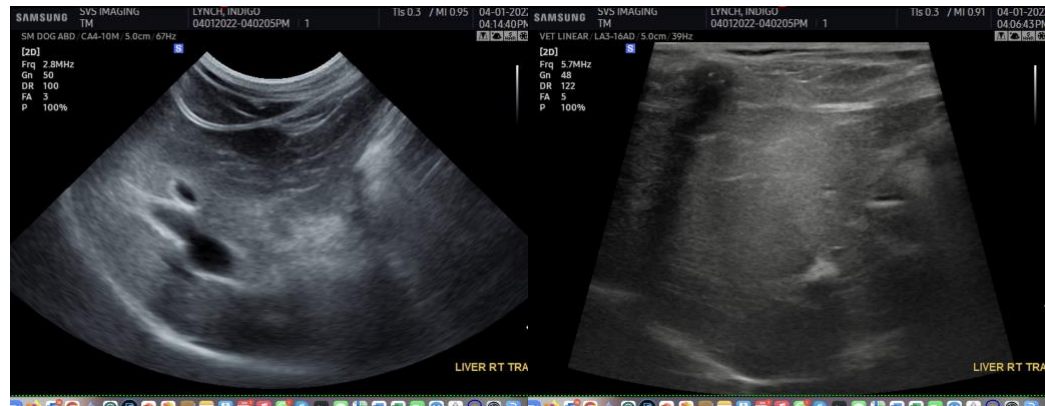
INVOICE

14561

DATE

4/2/22

loss (Cyanobalamine 250 mcg sub-q once-weekly x six weeks, then every other week for six weeks and then once-monthly, long-term if necessary), **novel-protein or hydrolyzed diet** (*Hydrolyzed diets have been shown to be more effective in dietary intolerance case management compared to hypoallergenic diets*) or the **magical Purina DM** (changing protein source is crucial and may need rotation every 6 months if clinical signs recur) Diet trials is a whatever works phenomenon. If vomiting becomes a persistent issue then endoscopy would be warranted and/or recheck sonogram to assess more emerging disease. One diet does not work for all patients so different trials may be necessary or protein source rotation every 6 months as new sensitivities develop.



IMAGING PERFORMED BY

SVS Mobile Imaging CT 262-366-5970
fredgromalak@gmail.com



Clinical Sonography & Telecytology

EDUCATIONAL TELECONSULTATION SERVICES™

1-800-838-4268 info@sonopath.com SonoPath.com

PATIENT

Indigo Lynch

SPECIES

Feline

BREED

Domestic Shorthair

SEX

Spayed Female

AGE

1 Year 1 Month

WEIGHT

6.7 Pounds

INTERPRETED BY

Eric Lindquist, DMV
DABVP, Cert. IVUSS

IMAGING PERFORMED BY

Tom McNeill

HOSPITAL NAME

SVS Imaging CT

REFERRING VET

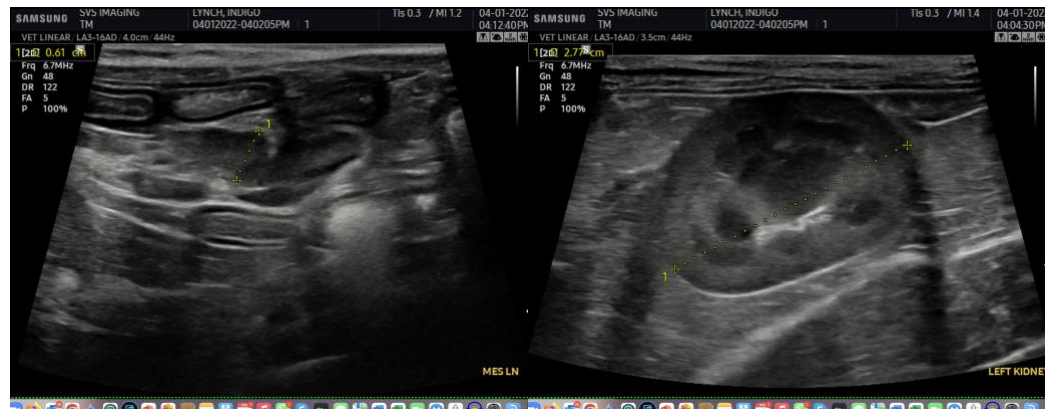Advanced AH- Dr.
Schnuelle

INVOICE

14561

DATE

4/2/22



The information and recommendations provided are based on the images presented by the referring veterinarian. No evaluation can be communicated regarding pathology that was not visible in the image/video clips provided.

Thank you for this referral. If the clinical or image interpretation does not parallel your findings or if I can be of any further assistance please contact me.

Eric Lindquist, DMV, DABVP, Cert. IVUSS, CEO of SonoPath.com
Eric.Lindquist@SonoPath.com