



## PATIENT

HeiHei Hu

## SPECIES

Feline

## BREED

DSH

## SEX

Neutered Male

## AGE

7 Years

## WEIGHT

11

## INTERPRETED BY

Eric Lindquist, DMV,  
DABVP (CFM), Cert.  
IVUSS

## IMAGING PERFORMED BY

Dr. Shen Li

## HOSPITAL NAME

Dr. Shen Li Veterinary  
Service

## REFERRING VET

Dr. Shen Li

## INVOICE

74602

## DATE

4/19/26

## PRESENTING CLINICAL SIGNS

Indoor only. Hx of diarrhea a month ago, resolved after changing diet. Suspected bad food as the other cat in the household had similar symptoms at the same time.

Abnormal PE/Chem/CBC/UA Results: Normal PE crea0.8 usg1.028 1+ protein 3+ struvite the rest bw normal

## ULTRASONOGRAPHIC EXAMINATION OF THE ABDOMEN

### Urinary System

The **urinary bladder**, trigone, and pelvic urethra presented normal thicknesses and normal tone. The ureters were not visible which is normal. No uroliths or sediment were visualized and anechoic urine was present. No evidence of inflammatory or neoplastic changes were noted. Ureteral papillae were normal. The pelvic urethra was imaged 1.0 cm beyond the cystourethral junction.

The **kidneys** revealed normal size and structure, corticomedullary definition and ratio for this age. The cortices presented largely uniform texture with normal echogenic relationship to liver and spleen. Medullary structure differed distinctly from the cortex and no evidence of pelvic dilation was present. The capsules were acceptably uniform without significant irregularities. Left kidney measured 4.9 cm. Right kidney measured 4.47 cm.

### Adrenal Glands

The regions of the **adrenal glands** were unremarkable.

### Spleen

The **spleen** presented a smooth homogeneous parenchyma hyperechoic to liver and renal cortical parenchyma. The capsule was smooth without noticeable expansion or deviation from within the spleen or adjacent pathology. The splenic vasculature demonstrated normal volume without signs of congestion or thrombosis. No sonographic evidence of acute or chronic inflammatory, neoplastic, or infarctual changes were noted.

### Liver

The **liver** images submitted revealed subjectively normal liver size, contour, and structure. Parenchymal echogenicity was naturally coarse and hypoechoic to the spleen. Vascular and biliary tracts were of normal volume with no evidence of congestion. The gallbladder presented acceptably thin walls with primarily anechoic content. The cystic and common bile ducts were normal. No pathological hepatic lymphadenopathy was evident. No overt structural evidence of inflammatory, infiltrative or regenerative pathology was evident.

### Gastrointestinal

The **stomach** was filled with progressively shadowing luminal material. Post-prandial presentation or possible hairball accumulation. I cannot rule out soft foreign matter depending on when the patient ate prior to the sonogram. The small intestine and colon were unremarkable.



**PATIENT**

HeiHei Hu

**SPECIES**

Feline

**BREED**

DSH

**SEX**

Neutered Male

**AGE**

7 Years

**WEIGHT**

11

**INTERPRETED BY**

Eric Lindquist, DMV,  
DABVP (CFM), Cert.  
IUUS

**IMAGING PERFORMED BY**

Dr. Shen Li

**HOSPITAL NAME**

Dr. Shen Li Veterinary  
Service

**REFERRING VET**

Dr. Shen Li

**INVOICE**

74602

**DATE**

4/19/26

**Pancreas**

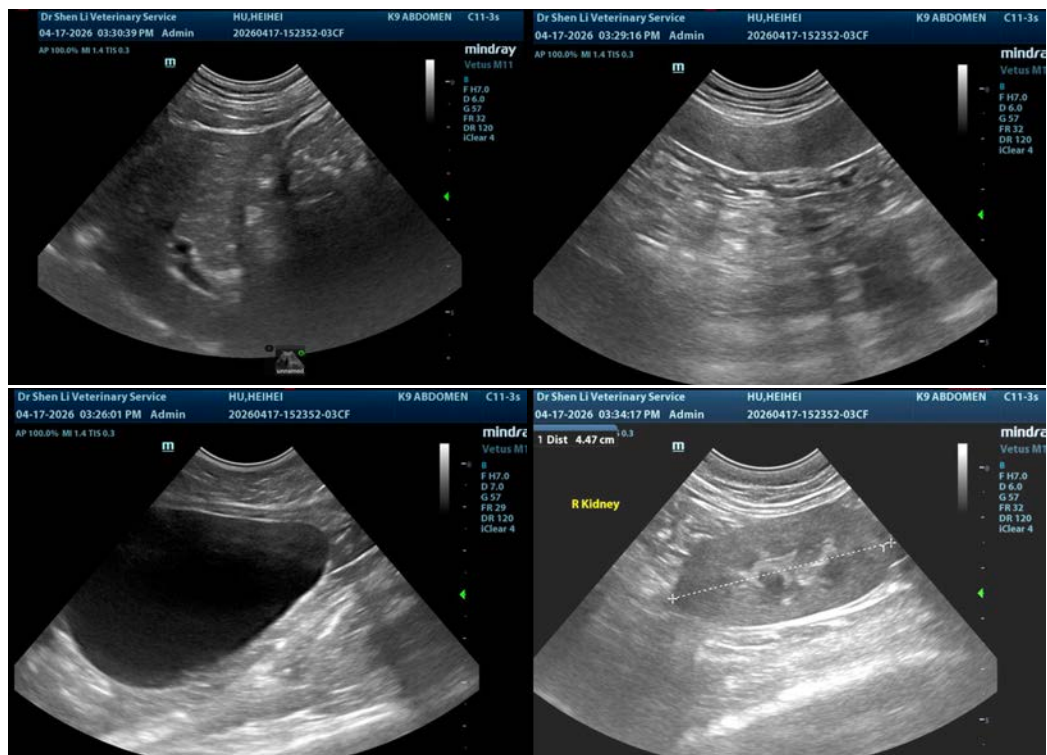
The base and limbs of the **pancreas** were observed to be largely isoechoic to surrounding omental fat. Pancreatic duct and capsular contour were acceptably normal and parenchyma respected normal curvilinear patterns. No overt evidence of active inflammatory or neoplastic disease was noted.

**ULTRASONOGRAPHIC FINDINGS**

- Full stomach or possible hairball or soft foreign matter accumulation.

**INTERPRETATION OF THE FINDINGS & FURTHER RECOMMENDATIONS**

No evidence of structural disease. Differentials for diarrhea include occult parasitism, dietary indiscretion, dietary intolerance, antibiotic responsive colitis, intestinal dysbiosis should all be considered as causes of diarrhea in this patient. A hydrolyzed diet trial may be in this patient's best interest +/- probiotics. 8-12-hour NPO and reintroduction of bland diet indicated. I recommend a fresh fecal smear and fecal floatation analysis if not already performed. Note that recent research has shown that indiscriminate use of antibiotics may actually cause harm. Most acute cases of diarrhea will respond to probiotic therapy, fiber, and gastrointestinal diets over the next 3-5 days. Low dose Prednisolone trial may be necessary in some cases. However, this may be problematic if an occult, non-evident round cell neoplasia or similar is developing.





## PATIENT

HeiHei Hu

## SPECIES

Feline

## BREED

DSH

## SEX

Neutered Male

## AGE

7 Years

## WEIGHT

11

## INTERPRETED BY

Eric Lindquist, DMV,  
DABVP (CFM), Cert.  
IVUSS

## IMAGING PERFORMED BY

Dr. Shen Li

## HOSPITAL NAME

Dr. Shen Li Veterinary  
Service

## REFERRING VET

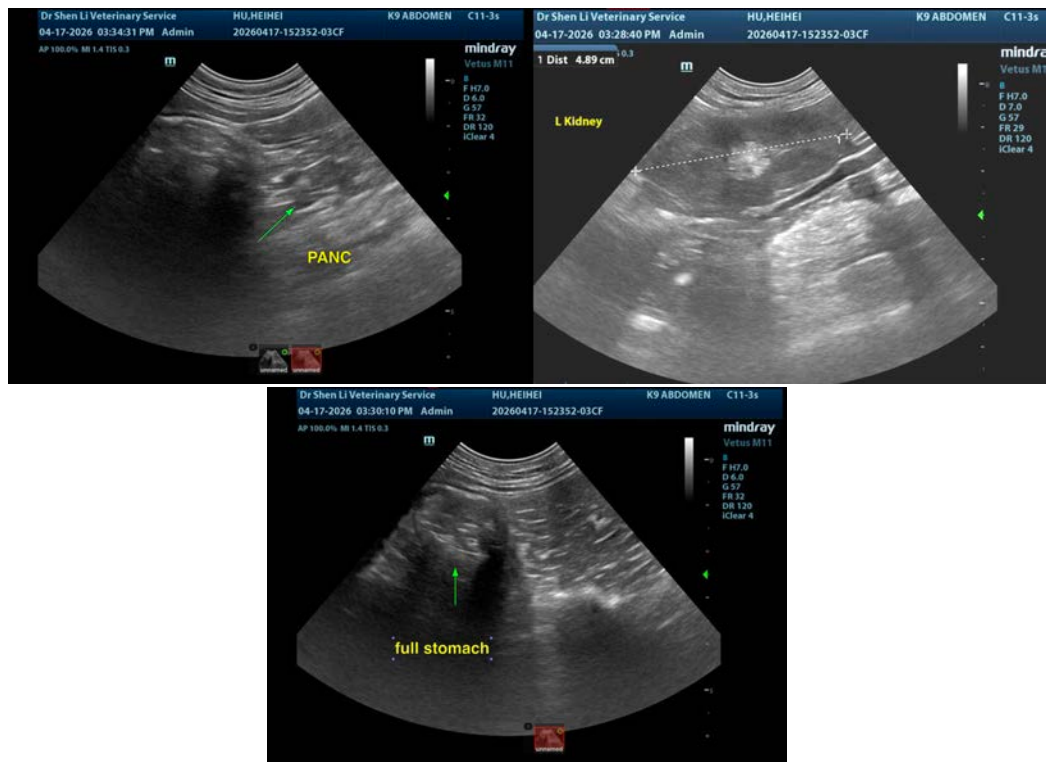
Dr. Shen Li

## INVOICE

74602

## DATE

4/19/26



The information and recommendations provided are based on the images presented by the referring veterinarian/sonographer. No evaluation can be communicated regarding pathology that was not visible in the image/video clips provided.

Thank you for this referral. If the clinical or image interpretation does not parallel your findings or if I can be of any further assistance please contact me.

**Eric Lindquist**, DMV, DABVP(CFM), Cert. IVUSS,  
CEO, Owner, Founder -- SonoPath.com  
[info@SonoPath.com](mailto:info@SonoPath.com)