



PATIENT PRESENTING CLINICAL SIGNS

Lili Maniar History: anorexia, lethargy

SPECIES ULTRASONOGRAPHIC EXAMINATION OF THE ABDOMEN

Feline **Urinary System**

BREED

Domestic Shorthair

The **urinary bladder**, trigone, and pelvic urethra presented normal thicknesses and normal tone. The ureters were not visible which is normal. No uroliths or sediment were visualized and anechoic urine was present. No evidence of inflammatory or neoplastic changes was noted. Ureteral papillae were normal.

SEX

Spayed female

AGE

10 years

The **kidneys** revealed largely normal size and structure, corticomedullary definition and ratio (cortex 1/3 of medulla) were essentially maintained with some age-related loss of curvilinear patterns regarding the capsule and C/M junction. The cortices presented largely uniform texture with some increased echogenicity expected for his age patient. Medullary structure differed distinctly from that of the cortex and no evidence of pelvic dilation was present. Mild pericapsular fat enhancement was noted in both kidneys. The right kidney measured 4.08 cm. The left kidney measured 4.0 cm.

WEIGHT

12.2 lbs

Adrenal Glands

Both **adrenal glands** were visualized and recognized as having normal shape, size, position and echogenicity for this breed. The phrenic vasculature, glandular echogenicity and detail were unremarkable. Capsule, cortex, and medullary definition were normal for this age patient.

INTERPRETED BY

Eric Lindquist, DMV
DABVP, Cert. IVUSS

Spleen

The **spleen** presented a smooth homogeneous parenchyma hyperechoic to liver and renal cortical parenchyma. The capsule was smooth without noticeable expansion or deviation from within the spleen or adjacent pathology. The splenic vasculature demonstrated normal volume without signs of congestion or thrombosis. No sonographic evidence of acute or chronic inflammatory, neoplastic, or infarctual changes was noted. The spleen measured 0.9 cm in width.

IMAGING PERFORMED BY

Jenn

HOSPITAL NAME

Rockaway AH

Liver

REFERRING VET

Dr. Maniar

The **liver** images from right and left intercostal as well as subcostal views revealed subjectively normal liver size, contour, and structure. Some age-related parenchymal remodeling was noted but likely not clinically significant at this time. Vascular and biliary tracts were of normal volume and no evidence of congestion was noted. The gallbladder presented some dependent debris with essentially normal contour. The cystic and common bile ducts were normal. No overt evidence of active inflammatory, infiltrative or regenerative pathology was noted but should be paired with current or past LE elevations regarding any clinical significance to this presentation. The hepatic lymph nodes were unremarkable.

INVOICE

43877

DATE

4/19/23



PATIENT

Gastrointestinal

Lili Maniar

There was some residual chyme and gas was noted in the **stomach**, yet not pathological. This is consistent with end post prandial presentation. The small intestine was slightly thickened in this patient. Some soft, partially shadowing material was noted in the gastric lumen. This is consistent with ingesta or possible hair accumulation. Other foreign matter cannot be completely ruled out.

SPECIES

Feline

Pancreas

BREED

Domestic Shorthair

The base and limbs of the **pancreas** were observed to be largely isoechoic to surrounding omental fat. Pancreatic duct and capsular contour were acceptably normal and parenchyma respected normal curvilinear patterns. No overt evidence of active inflammatory or neoplastic disease was noted.

SEX

Spayed female

ULTRASONOGRAPHIC FINDINGS

Hair density in the stomach, possible other foreign matter.

AGE

10 years

Possible nephritis pattern.

WEIGHT

12.2 lbs

INTERPRETATION OF THE FINDINGS & FURTHER RECOMMENDATIONS

Urinary work-up is warranted to assess for UTI or inflammatory sediment. There is no evidence of neoplasia. Other causes of the clinical signs such as pain related to orthopedic disease, CNS or thoracic disease should be considered as well. Pain related to orthopedic disease, CNS or thoracic disease should be considered as well.

INTERPRETED BY

Eric Lindquist, DMV
DABVP, Cert. IVUSS

ABOUT SONOPATH CT SERVICES:

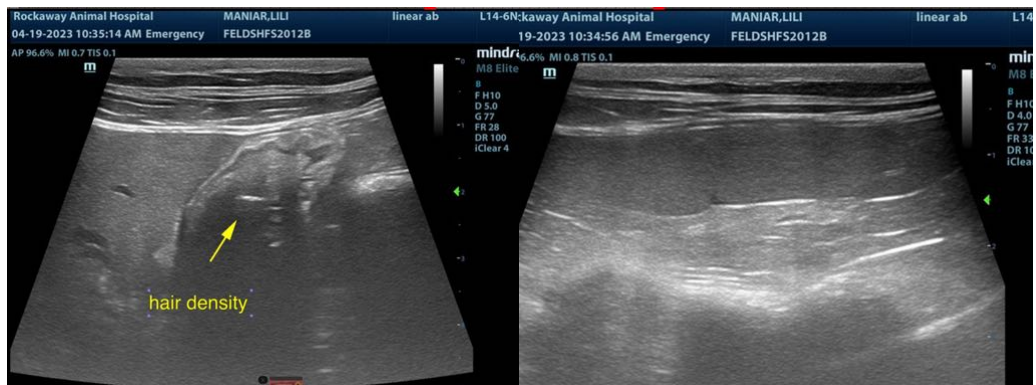
SonoPath CT Services are offered at the SonoPath Imaging and Veterinary Education Center, 141 Main St (rt 206), Andover, New Jersey, a 20-minute drive west on route 80/206 North from the route 80/287 interchange/Parsippany, New Jersey. More information can be found at <https://sonopath.com/resources/sonopath-teleconsultation-services-and-sdep-certification/sonopath-ct-services>

IMAGING PERFORMED BY

Jenn

HOSPITAL NAME

Rockaway AH



REFERRING VET

Dr. Maniar

INVOICE

43877

DATE

4/19/23



PATIENT

Lili Maniar

SPECIES

Feline

BREED

Domestic Shorthair

SEX

Spayed female

AGE

10 years

WEIGHT

12.2 lbs

INTERPRETED BY

Eric Lindquist, DMV
DABVP, Cert. IVUS

IMAGING PERFORMED BY

Jenn

HOSPITAL NAME

Rockaway AH

REFERRING VET

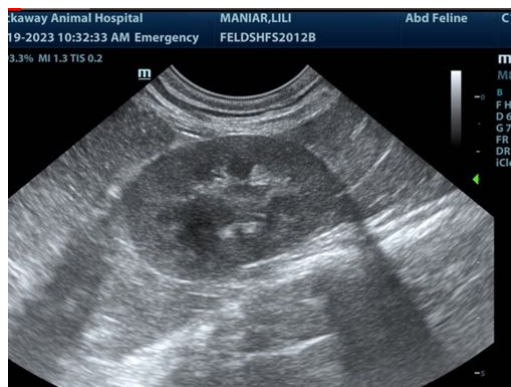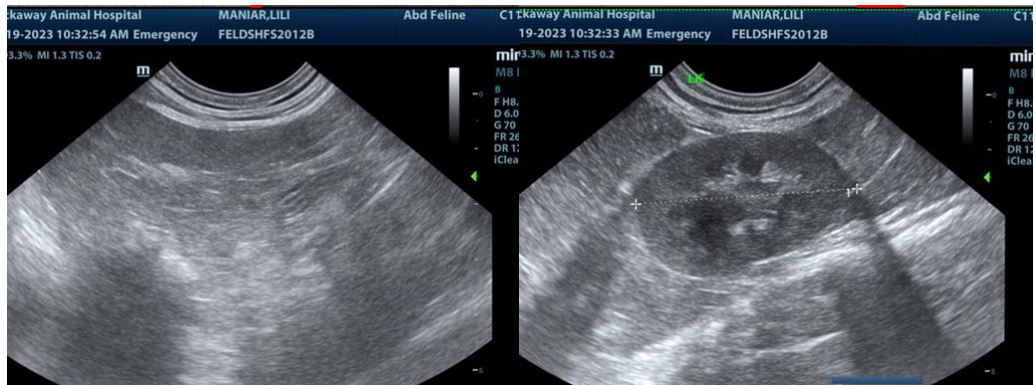
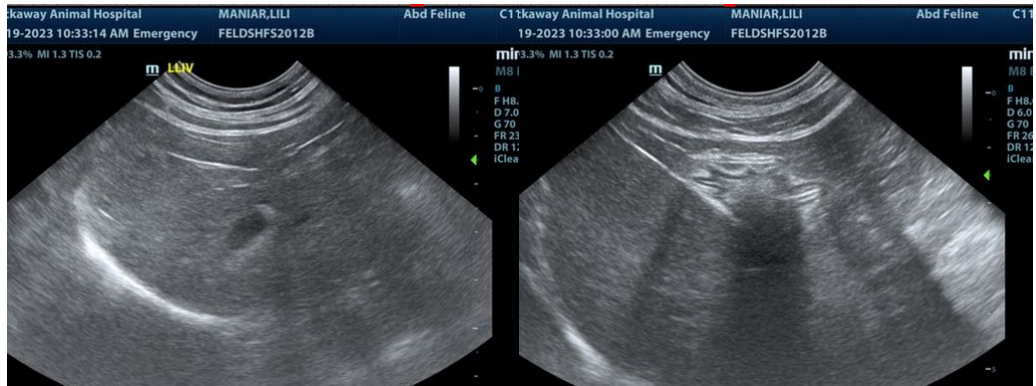
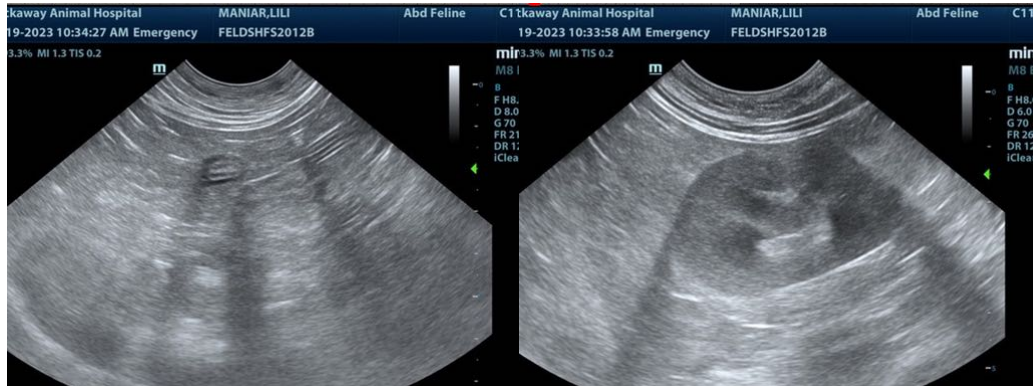
Dr. Maniar

INVOICE

43877

DATE

4/19/23





PATIENT

Lili Maniar

The information and recommendations provided are based on the images presented by the referring veterinarian/sonographer. No evaluation can be communicated regarding pathology that was not visible in the image/video clips provided.

SPECIES

Feline

Thank you for this referral. If the clinical or image interpretation does not parallel your findings or if I can be of any further assistance please contact me.

BREED

Domestic Shorthair

Eric Lindquist, DMV, DABVP, Cert. IVUSS, CEO of SonoPath.com
info@SonoPath.com

SEX

Spayed female

AGE

10 years

WEIGHT

12.2 lbs

INTERPRETED BY

Eric Lindquist, DMV
DABVP, Cert. IVUSS

**IMAGING
PERFORMED BY**

Jenn

HOSPITAL NAME

Rockaway AH

REFERRING VET

Dr. Maniar

INVOICE

43877

DATE

4/19/23