



PATIENT PRESENTING CLINICAL SIGNS

Winn Drake Grade 3/6 systolic murmur, progressed. Asymptomatic. Previous echo 8/11/20. pre-surgical evaluation, please assess for anesthesia. not on any meds

SPECIES

Feline

BREED

Siamese

SEX

Neutered male

AGE

9 years

WEIGHT

12.6 lbs

INTERPRETED BY

Eric Lindquist, DMV
DABVP, Cert. IVUSS

IMAGING PERFORMED BY

Diane McFadden, RVT

HOSPITAL NAME

East Plane AH

INVOICE

Dr. Rosen

DATE

4/19/22

ULTRASONOGRAPHIC EXAMINATION OF THE HEART

The echocardiogram in this patient demonstrated moderate **left atrial** enlargement. **Mitral** valve insufficiency velocity was 5.0 m/sec. The **left ventricle** presented normal thicknesses with linear contour and was not dilated nor restricted. The **myocardium** presented normal echogenicity without subjective evidence of significant fibrotic or ischemic disease. **Contractility** of the ventricular walls was adequate and in normal range for this patient evidenced by the fractional shortening measurement and subjective evaluation of the different regions and angles of the myocardium. The **left ventricular outflow** tract demonstrated normal laminar flow and subjective structural integrity. The **right atrium** and auricle revealed normal size, structure and content. No evidence of masses was noted or chamber overload. **Tricuspid** valvular assessment demonstrated adequate linear morphology and kinetics. The **right ventricle** was of normal size (1/3 diameter of LV), chordae structure, myocardial echogenicity and thickness. **Pulmonic** tract assessment revealed normal valve structure, laminar flow, and diameter (approx.1:1 pa/ao ratio). No visible **pericardial** or free pleura fluid was noted or extra cardiac pathology in the visible planes. The cranial **mediastinum** and **pericardial regions** were free of masses in the visible window.

| FELINE CARDIAC PARAMETERS | BODY WEIGHT (kg) | HR (BPM) | IVSd (cm) | LVIDd (cm) | LVWd (cm) | FS (%) | EF (%) |
|--|------------------|---------------------------|--|-----------------|-----------------|-----------|--------|
| NORMAL PARAMETER | ----- | 150-240 | 0.3-0.6 | 1.0-2.1 | 0.25-0.6 | 35-67 | 80-100 |
| PATIENT | | 245 | 0.42 | 1.36 | 0.39 | 54 | 88 |
| FELINE CARDIAC PARAMETERS | LA/AO (Boon) | LA/AO HEART BASE (Sisson) | LA 2D 4-chamber long axis AS to FW (Sisson) (cm) | LVOT VEL. (m/s) | RVOT VEL. (m/s) | IVRT (m/) | |
| NORMAL PARAMETER | <1.5 | 0.88-1.79 | 0.7-1.7 | <1.6 | <1.3 | 40-60 | |
| PATIENT | 1.9 | 1.6 | | 1.7 | 1.0 | NM | |
| Adapted from June Boon, Veterinary Echocardiography, 1998 Sisson D et al. JVIM 1991; 5: 232, Jacobs et al. Am J Vet Res 1985; 46:1705 | | | | | | | |

ULTRASONOGRAPHIC FINDINGS

Progressed mitral insufficiency.
Left atrial enlargement and tachycardia.



PATIENT

Winn Drake

SPECIES

Feline

BREED

Siamese

SEX

Neutered male

AGE

9 years

WEIGHT

12.6 lbs

INTERPRETED BY

Eric Lindquist, DMV
DABVP, Cert. IVUS

IMAGING PERFORMED BY

Diane McFadden, RVT

HOSPITAL NAME

East Plane AH

INVOICE

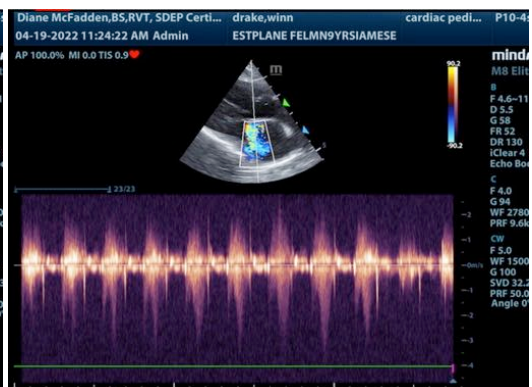
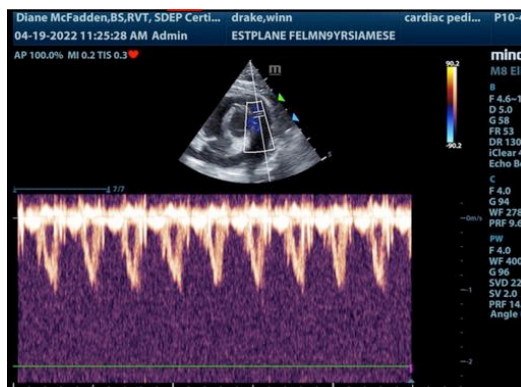
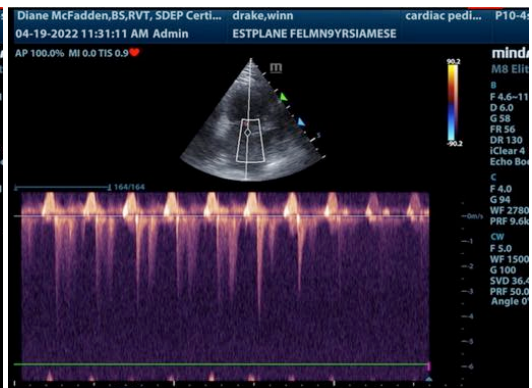
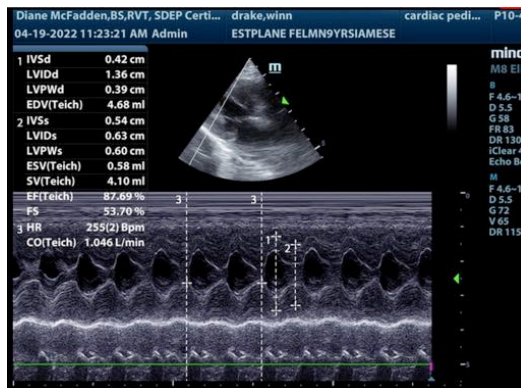
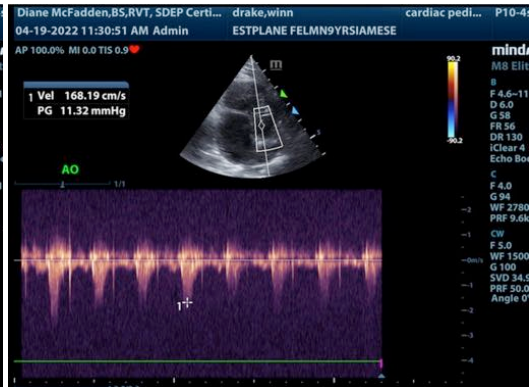
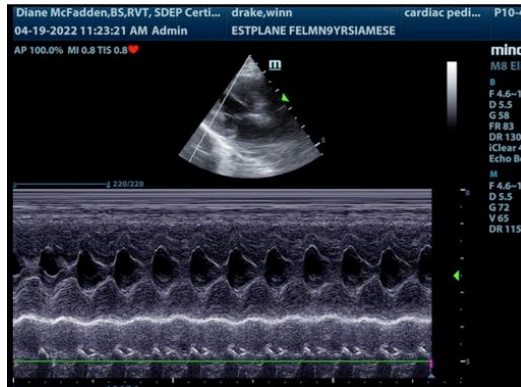
Dr. Rosen

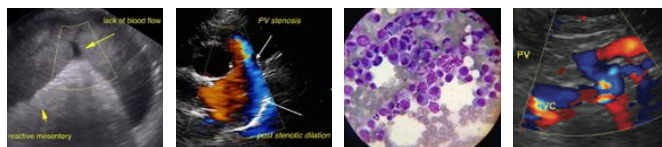
DATE

4/19/22

INTERPRETATION OF THE FINDINGS & FURTHER RECOMMENDATIONS

I recommend ace inhibitor in this patient at 0.5mg/kg s.i.d. and Lasix at 6.25 mg b.i.d. Target respiratory rate less than 20/minute. I do not recommend surgical intervention at this time as this patient is about to enter into congestive heart failure. A recheck echocardiogram is recommended in 7-10 days for reassessment.





PATIENT

Winn Drake

SPECIES

Feline

BREED

Siamese

SEX

Neutered male

AGE

9 years

WEIGHT

12.6 lbs

INTERPRETED BY

Eric Lindquist, DMV
DABVP, Cert. IVUSS

IMAGING PERFORMED BY

Diane McFadden, RVT

HOSPITAL NAME

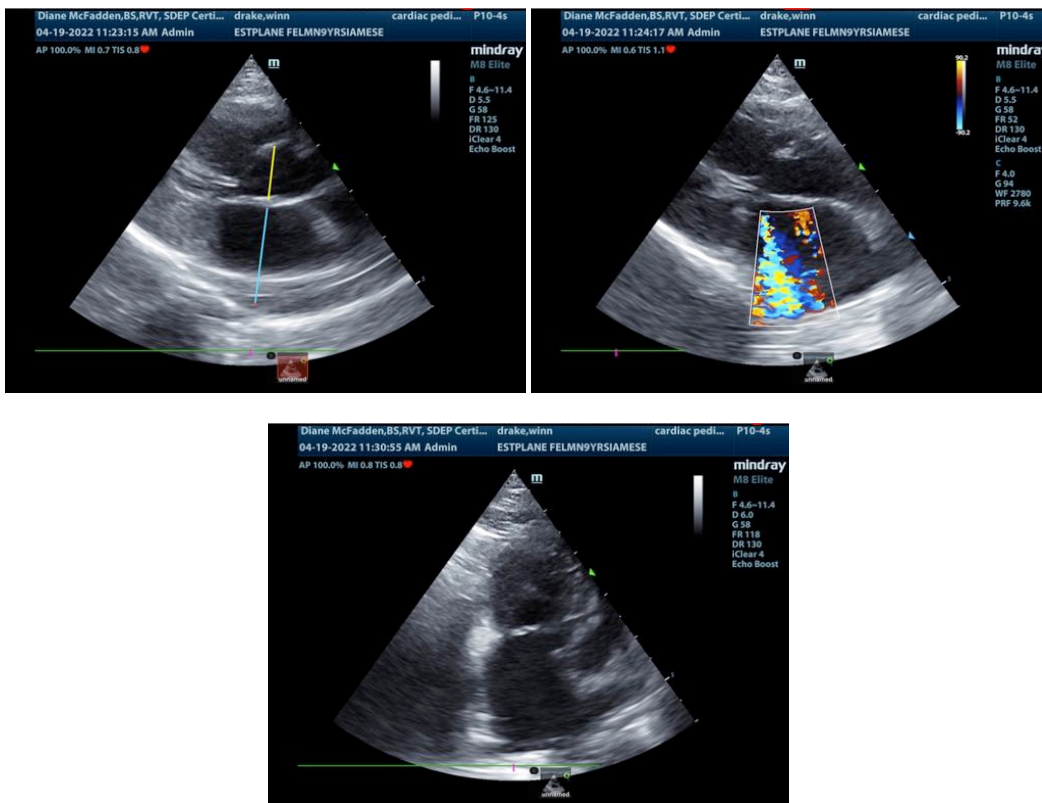
East Plane AH

INVOICE

Dr. Rosen

DATE

4/19/22



The information and recommendations provided are based on the images presented by the referring veterinarian/sonographer. No evaluation can be communicated regarding pathology that was not visible in the image/video clips provided.

Thank you for this referral. If the clinical or image interpretation does not parallel your findings or if I can be of any further assistance please contact me.

Eric Lindquist, DMV, DABVP, Cert. IVUSS, CEO of SonoPath.com
Info@SonoPath.com