



PATIENT	PRESENTING CLINICAL SIGNS
Taz Lucibello	History: Acute onset vomiting, hx of dietary indiscretion.
SPECIES	ULTRASONOGRAPHIC EXAMINATION OF THE ABDOMEN
Feline	Urinary System
BREED	The urinary bladder , trigone, and pelvic urethra presented normal thicknesses and normal tone. The ureters were not visible which is normal. No uroliths or sediment were visualized and anechoic urine was present. No evidence of inflammatory or neoplastic changes was noted. Ureteral papillae were normal.
Domestic Shorthair	
SEX	The kidneys revealed normal size and structure, corticomedullary definition and ratio for this age. The cortices presented largely uniform texture with normal echogenic relationship to liver and spleen. Medullary structure differed distinctly from the cortex and no evidence of pelvic dilation was present. The capsules were acceptably uniform without significant irregularities. The left kidney measured 3.54 cm. The right kidney measured 4.03 cm.
Neutered male	
AGE	
11 months	
WEIGHT	Adrenal Glands
7.1 lbs	Both adrenal glands were visualized and recognized as having normal shape, size, position and echogenicity for this breed. The phrenic vasculature, glandular echogenicity and detail were unremarkable. Capsule, cortex, and medullary definition were normal for this age patient. The right adrenal gland measured 0.33 cm. The left adrenal gland measured 0.38 cm.
INTERPRETED BY	Spleen
Eric Lindquist, DMV DABVP, Cert. IVUSS	The spleen presented a smooth homogeneous parenchyma hyperechoic to liver and renal cortical parenchyma. The capsule was smooth without noticeable expansion or deviation from within the spleen or adjacent pathology. The splenic vasculature demonstrated normal volume without signs of congestion or thrombosis. No sonographic evidence of acute or chronic inflammatory, neoplastic, or infarctual changes was noted. The spleen measured 0.84 cm.
IMAGING PERFORMED BY	Liver
Shari Reffi, CVT	The liver images submitted revealed subjectively normal liver size, contour, and structure. Parenchymal echogenicity was naturally coarse and hypoechoic to the spleen. Vascular and biliary tracts were of normal volume with no evidence of congestion. Duplicated gallbladder was noted, yet not pathological.
HOSPITAL NAME	Gastrointestinal
Rockaway AH	The gastrointestinal presentation revealed mild uniform prominence of the gastric mucosa as well as areas of "ropey" small intestinal wall with slight disruption of the normal 1:3 muscularis/mucosal ratio. The intestinal submucosa was slightly irregular, thickened and hyperechoic suggestive of low grade, chronic disease. The mesenteric lymph nodes were reactive and measured 1.97 x 0.59 cm.
REFERRING VET	
Dr. Maniar	
INVOICE	
99376	
DATE	
4/15/22	



PATIENT

Pancreas

Taz Lucibello

The base and limbs of the **pancreas** were observed to be largely isoechoic to surrounding omental fat. Pancreatic duct and capsular contour were acceptably normal and parenchyma respected normal curvilinear patterns. No overt evidence of active inflammatory or neoplastic disease was noted.

SPECIES

Feline

ULTRASONOGRAPHIC FINDINGS

BREED

IBD GI pattern, subacute presentation.

Domestic Shorthair

Duplicated gallbladder, not pathological.

Slight, mesenteric lymphadenopathy.

SEX

Neutered male

INTERPRETATION OF THE FINDINGS & FURTHER RECOMMENDATIONS

AGE

Supportive care for non-specific GI upset should prove effective. Treatment for Enterotoxins are indicated as well as anti-parasitic protocol.

11 months

WEIGHT

7.1 lbs

INTERPRETED BY

Eric Lindquist, DMV
DABVP, Cert. IVUSS

IMAGING PERFORMED BY

Shari Reffi, CVT

HOSPITAL NAME

Rockaway AH

REFERRING VET

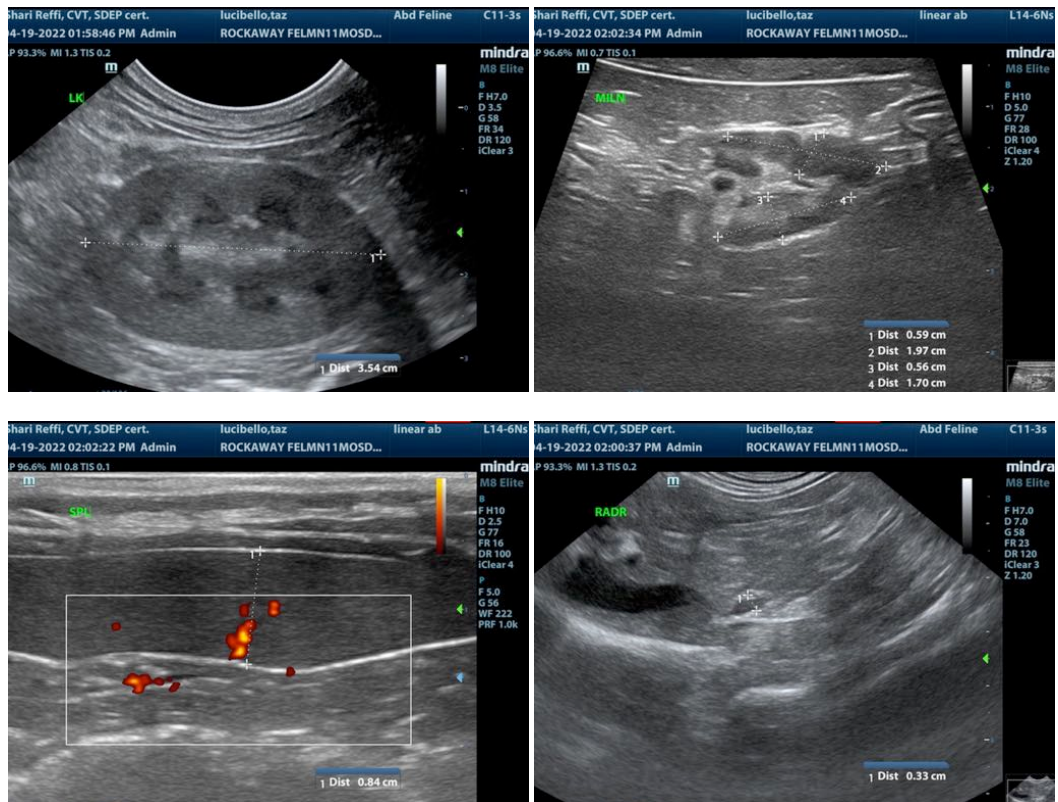
Dr. Maniar

INVOICE

99376

DATE

4/15/22





PATIENT

Taz Lucibello

SPECIES

Feline

BREED

Domestic Shorthair

SEX

Neutered male

AGE

11 months

WEIGHT

7.1 lbs

INTERPRETED BY

Eric Lindquist, DMV
DABVP, Cert. IVUSS

IMAGING PERFORMED BY

Shari Reffi, CVT

HOSPITAL NAME

Rockaway AH

REFERRING VET

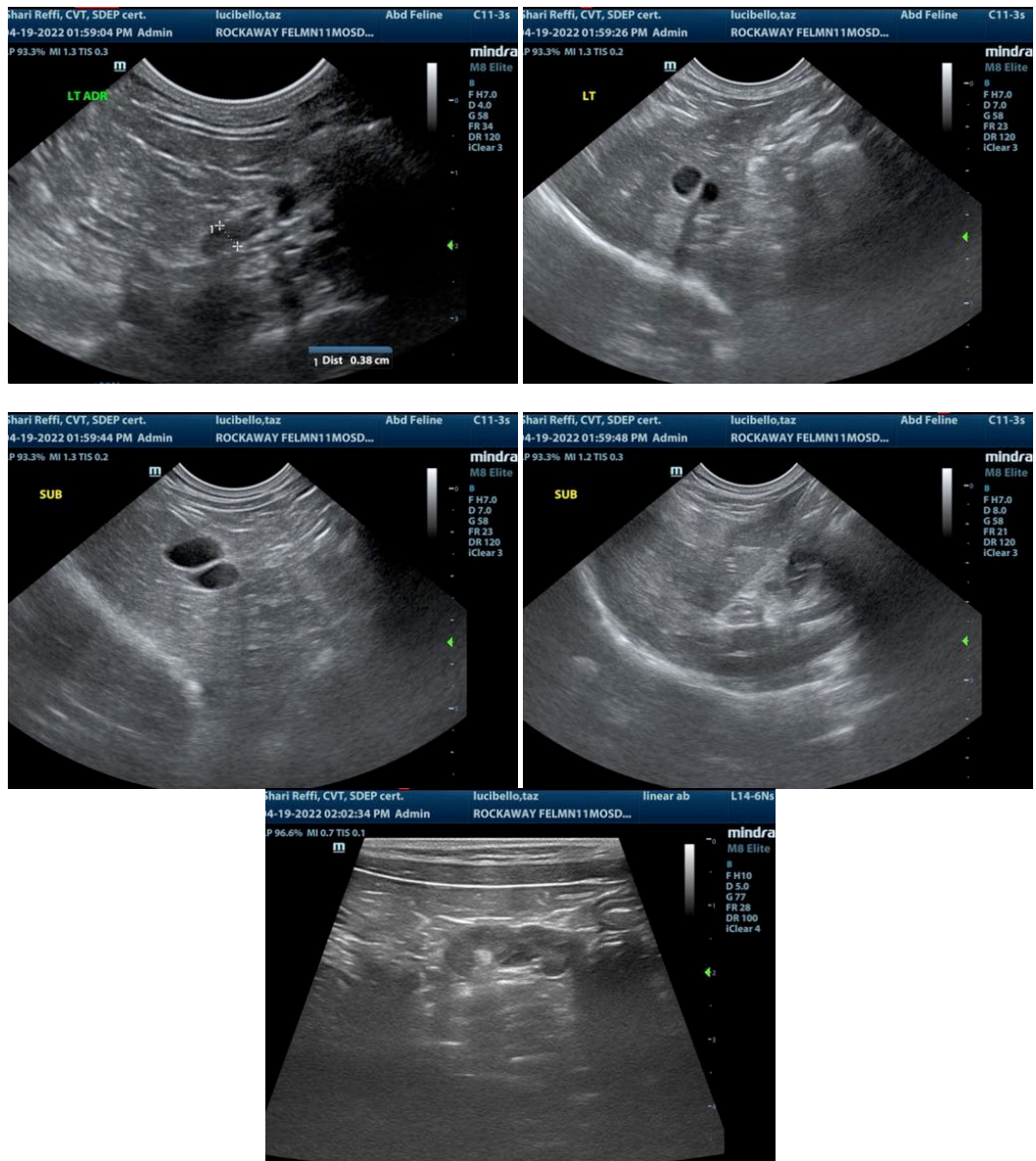
Dr. Maniar

INVOICE

99376

DATE

4/15/22



The information and recommendations provided are based on the images presented by the referring veterinarian/sonographer. No evaluation can be communicated regarding pathology that was not visible in the image/video clips provided.

Thank you for this referral. If the clinical or image interpretation does not parallel your findings or if I can be of any further assistance please contact me.

Eric Lindquist, DMV, DABVP, Cert. IVUSS, CEO of SonoPath.com
Info@SonoPath.com