



PATIENT PRESENTING CLINICAL SIGNS

Gus Johnson Difficulty urinating- no obvious reasons on rads
Abnormal PE/Chem/CBC/UA Results: Lymphocytes 690 Current Medications Cerenia Inj. 2cc

SPECIES

Canine

BREED

Lab x Aussie

SEX

Neutered Male

AGE

14 Years

WEIGHT

56.6 Pounds

INTERPRETED BY

Eric Lindquist, DMV

DABVP, Cert. IVUSS

IMAGING PERFORMED BY

Sara Hansen

HOSPITAL NAME

Linn Vet Hospital

REFERRING VET

Dr. Braat

INVOICE

36987

DATE

4/19/22

ULTRASONOGRAPHIC EXAMINATION OF THE ABDOMEN

Urinary System

The **urinary bladder** revealed a concentric dorsocaudal bladder mass. Wall thickness measured up to 1.5 cm with complete loss of mural detail, areas of mineralization, and ureteral obstruction. The left ureter was dilated to 0.55 cm. The mass continued into the cystourethral junction and urethra and is nonresectable.

The **kidneys** revealed normal size and structure, corticomedullary definition and ratio for this age. The cortices presented largely uniform texture with normal echogenic relationship to liver and spleen. Medullary structure differed distinctly from the cortex and no evidence of pelvic dilation was present. The capsules were acceptably uniform without significant irregularities. The left kidney measured 6.33 cm. The right kidney measured 7.42 cm.

Adrenal Glands

Both **adrenal glands** were visualized and recognized as having normal shape, size, position and echogenicity for this breed. The phrenic vasculature, glandular echogenicity and detail were unremarkable. Capsule, cortex, and medullary definition were normal for this age patient. The left adrenal gland measured 3.51 cm x 0.75 cm at the caudal pole and 0.91 cm at the cranial pole.

Spleen

The **spleen** presented a smooth homogeneous parenchyma hyperechoic to liver and renal cortical parenchyma. The capsule was smooth without noticeable expansion or deviation from within the spleen or adjacent pathology. The splenic vasculature demonstrated normal volume without signs of congestion or thrombosis. No sonographic evidence of acute or chronic inflammatory, neoplastic, or infarctual changes were noted.

Liver

The **liver** images submitted revealed subjectively normal liver size, contour, and structure. Parenchymal echogenicity was naturally coarse and hypoechoic to the spleen. Vascular and biliary tracts were of normal volume with no evidence of congestion. The gallbladder presented acceptably thin walls with primarily anechoic content. The cystic and common bile ducts were normal. No pathological hepatic lymphadenopathy was evident. No overt structural evidence of inflammatory, infiltrative or regenerative pathology was evident.

Gastrointestinal

Examination of the **gastrointestinal tract** revealed a stomach and intestine free of stasis, of normal wall thickness, acceptable curvilinear mural detail, and peristaltic activity. Small and large intestine demonstrated normal luminal chyme and stool consistency respectively. No obstructive or overt infiltrative disease was noted. No associated abnormal lymphatic activity was noted.



PATIENT *Pancreas*

Gus Johnson The base and limbs of the **pancreas** were observed to be largely isoechoic to surrounding omental fat. Pancreatic duct and capsular contour were acceptably normal and parenchyma respected normal curvilinear patterns. No overt evidence of active inflammatory or neoplastic disease was noted.

SPECIES

Canine

BREED

Lab x Aussie

SEX

Neutered Male

AGE

14 Years

WEIGHT

56.6 Pounds

INTERPRETED BY

Eric Lindquist, DMV
 DABVP, Cert. IVUSS

IMAGING PERFORMED BY

Sara Hansen

HOSPITAL NAME

Linn Vet Hospital

REFERRING VET

Dr. Braat

INVOICE

36987

DATE

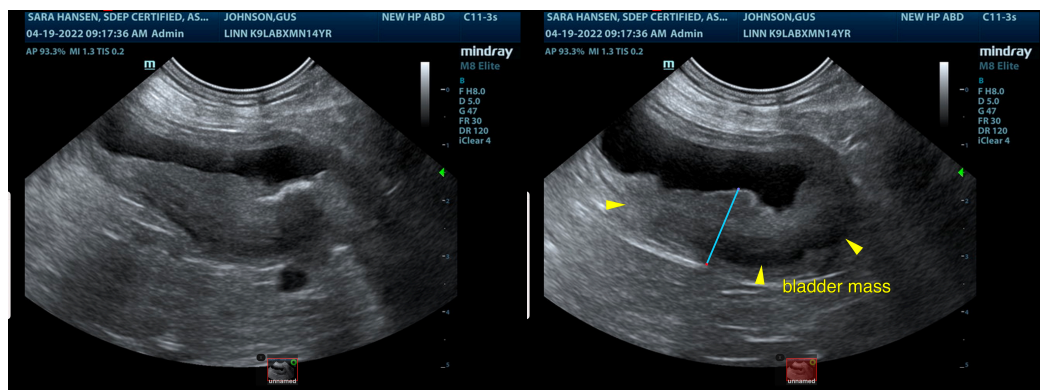
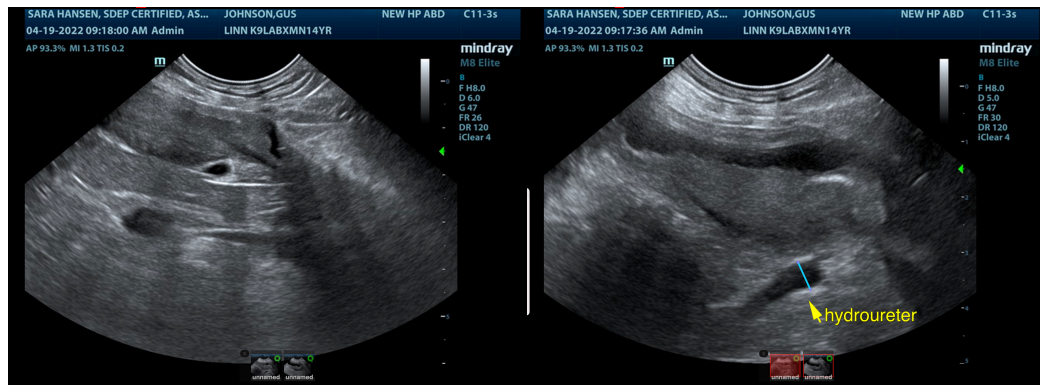
4/19/22

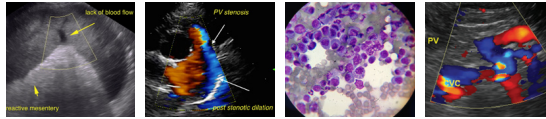
ULTRASONOGRAPHIC FINDINGS

- Cystourethral junction/trigonal bladder mass with left ureteral dilation/obstruction \
- Unremarkable abdomen otherwise

INTERPRETATION OF THE FINDINGS & FURTHER RECOMMENDATIONS

Oncological referral for urethral +/- ureteral stent placement would be indicated in this patient. Ultrasound guided traumatic catheterization could be considered for definitive diagnosis of suspected transitional cell carcinoma. Stent placement and chemotherapeutic intervention likely the best option in this patient. No overt evidence of metastatic disease.





PATIENT

Gus Johnson

SPECIES

Canine

BREED

Lab x Aussie

SEX

Neutered Male

AGE

14 Years

WEIGHT

56.6 Pounds

INTERPRETED BY

Eric Lindquist, DMV

DABVP, Cert. IVUSS

IMAGING PERFORMED BY

Sara Hansen

HOSPITAL NAME

Linn Vet Hospital

REFERRING VET

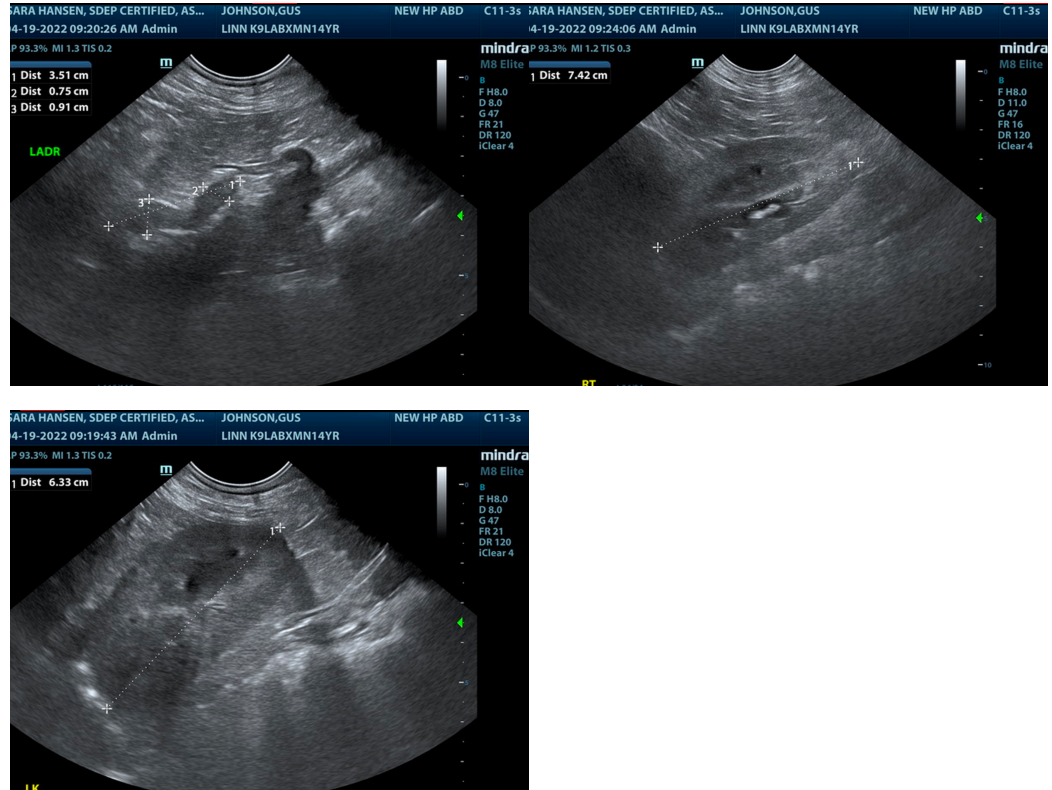
Dr. Braat

INVOICE

36987

DATE

4/19/22




The information and recommendations provided are based on the images presented by the referring veterinarian/sonographer. No evaluation can be communicated regarding pathology that was not visible in the image/video clips provided.

Thank you for this referral. If the clinical or image interpretation does not parallel your findings or if I can be of any further assistance please contact me.

Eric Lindquist, DMV, DABVP, Cert. IVUSS, CEO of SonoPath.com

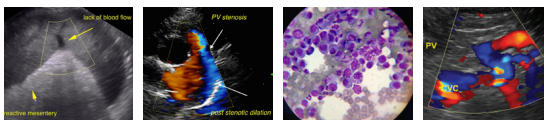
info@SonoPath.com



The following is an applicable excerpt from the *Curbside Guide to Diagnosis & Treatment of Sonographic Disease* offered by SonoPath.com Lindquist, Frank, Lobetti, and Modler.

An essential quick guide for every general practitioner and sonographer.

<https://sonopath.com/products/curbside-guide-editing-due-release-12012015>



PATIENT

Gus Johnson

SPECIES

Canine

BREED

Lab x Aussie

SEX

Neutered Male

AGE

14 Years

WEIGHT

56.6 Pounds

INTERPRETED BY

Eric Lindquist, DMV
DABVP, Cert. IVUSS

IMAGING PERFORMED BY

Sara Hansen

HOSPITAL NAME

Linn Vet Hospital

REFERRING VET

Dr. Braat

INVOICE

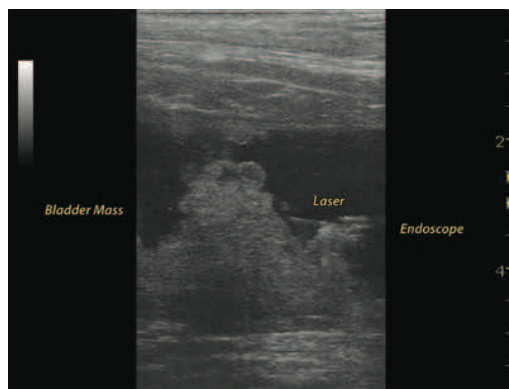
36987

DATE

4/19/22

Transitional Cell Carcinoma

<http://www.sonopath.com/TCC>



Long axis of the urinary bladder just prior to an ultrasound guided endoscopic laser ablation (UGELAB) procedure in a dog with transitional cell carcinoma of the bladder. A large irregular shaped heterogenous mass protruding into the lumen is seen on the dorsal bladder wall. Note the loss of wall layering in the region of the mass. Additional smaller masses are present on the ventral bladder wall. The endoscope and laser lumen are seen as hyperechoic linear structures.

Description: Many cases of transitional cell carcinoma (TCC) are either mistaken for urinary tract infections (UTIs) or go undiagnosed until they reach an advanced stage, thereby compromising the possibility for successful treatment. In dogs, TCC represents 90-95% of all bladder tumors; the remaining cases are comprised of squamous cell carcinoma, adenocarcinoma, papilloma, leiomyosarcoma, fibrosarcoma, hemangiosarcoma, and rhabdomyosarcoma. Urinary bladder tumors are rare in cats, but when they do occur, they are usually cases of TCC, lymphoma, or mesenchymal tumors.

Clinical Signs: Clinical signs of TCC typically include: hematuria, stranguria, pollakiuria, lethargy, weight loss, and bone pain or organ failure due to metastasis. Diagnosis occurs at a mean age of 11 years, and females are more often affected than males (ratio of 1.7:1). Overrepresented breeds include Scottish Terriers, Shetland Sheepdogs, West Highland White Terriers, Airedale Terriers, and Beagles. Obesity appears to be a predisposing factor. Insecticide exposure as well as cyclophosphamide and acrolein use have also been identified as potential triggers.

Diagnostics: Urine sediment analysis can reveal neoplastic cells in up to 30% of cases; however, interpretation must be scrupulous as reactive cells have a similar morphology to neoplastic ones. Ultrasound diagnostics, when available, provide prompt visualization as well as early detection by capturing minute irregularities in the bladder wall down to 2 mm as well as imaging the pelvic urethra to 3-4 cm caudal from the cystourethral junction. Ultrasound can also be used to evaluate regional lymph nodes and other organs for evidence of metastasis as well as the kidneys and ureter for evidence of



PATIENT

Gus Johnson

impingement and back-pressure from tumors located in the trigone area. One study of 65 dogs suggested that it might be possible to achieve even earlier detection using the veterinary bladder tumor antigen test (V-BTA, Bion Diagnostics), which yielded 90% sensitivity and 78% specificity. False positives occurred, however, in cases where the subjects had hematuria, proteinuria, and glucosuria.

SPECIES

Canine

The V-BTA is best used as a screening test, not a diagnostic tool. A negative test suggests that TCC is not likely present, but a positive test indicates that more testing—and a cytopathological or histopathological test in particular—is warranted. Although the V-BTA demonstrates good sensitivity, it only yields reasonable specificity; however, the negative predictive value is 95%. The most appropriate use of this test may be as a screening tool to rule out TCC in geriatric dogs. The second and third generation tests—(BTA stat® and Bard Trak, respectively—should not be used in dogs as they often yield false negative results.

BREED

Lab x Aussie

SEX

Neutered Male

AGE

14 Years

WEIGHT

56.6 Pounds

Treatment: Up to 80% of the urinary bladder can be surgically resected without long-term compromise provided that the trigone is not involved; however, canine TCC often involves the trigone area. TCC in dogs is metastatic, and up to 40% of dogs have metastatic disease at the time of diagnosis (17% of cases will have spread to the lungs). One study of 70 dogs revealed that the 25 that were treated with surgical debulking and medical therapy (chemotherapy and/or piroxicam) achieved a median life span of 272 days. Those that underwent biopsy only with medical therapy (42 dogs) experienced a median life span of 195 days, while the remaining 36 dogs that received medical therapy only averaged 150 days.

INTERPRETED BY

Eric Lindquist, DMV

DABVP, Cert. IVUSS

Surgical options include partial cystectomy, total cystectomy, ureterocolonic anastomosis, or the insertion of a permanent cystostomy catheter. Complete staging, including 3-view thoracic radiographs and abdominal ultrasound, should be performed prior to surgical intervention. A screening of spinal radiographs allows for an evaluation of the lumbar vertebrae.

IMAGING PERFORMED BY

Sara Hansen

Survival times range from a few months to over 48 months, depending on staging criteria and the procedure performed. The survival rate for patients with “non-resectable” trigonal/urethral TCC has improved considerably with the recent development of a new procedure—US-guided endoscopic laser ablation (UGELAB), which can be used in combination with urethral stents. UGELAB has shown significant success as a palliative procedure and can be repeated as progression occurs. Importantly, it avoids seeding by keeping the exfoliating cells within the bladder and is therefore an excellent method of obtaining clean samples given that this kind of tumor is notorious for “trailing” along needle passages. Anecdotal evidence suggests that strongly mineralized tumors respond best to laser ablation (tumor reduction from chemotherapy does not tend to be as effective in these cases). One study of over 60 patients indicated that survival times for those that underwent UGELAB varies depending on the tumor position and ureteral involvement. They ranged between 11 days and 1906 days; however, the median survival time (MST) was approximately 380 days, even in cases when additional therapies had also been pursued.

HOSPITAL NAME

Linn Vet Hospital

REFERRING VET

Dr. Braat

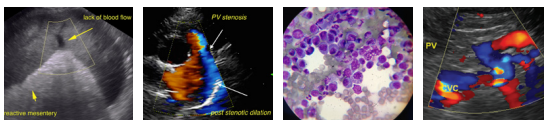
INVOICE

36987

DATE

4/19/22

Complete surgical excision of TCC is usually not possible due to trigone location, tumour size, and the presence of multifocal TCC. A study of 67 dogs with TCC resulted in 2 dogs with tumour-free margins; however, one of these dogs experienced a relapse 8 months later, and the other developed metastatic disease. Radiation therapy alone does not appear to be effective, and the benefits of surgical debulking remain controversial. TCC often recurs in the bladder despite surgical resection, either as a result of



PATIENT

Gus Johnson

microscopic disease at the surgical margins or *de novo* tumor growth due to field carcinogenesis. It is thought that TCC may reoccur in other regions of the bladder wall post-resection since it is highly likely that the entire bladder mucosa would have been exposed to the same carcinogen. Previously affected bladders therefore appear to be predisposed to new tumor development.

SPECIES

Canine

BREED

Lab x Aussie

SEX

Neutered Male

AGE

14 Years

WEIGHT

56.6 Pounds

Chemotherapy remains the treatment of choice for TCC as radiation therapy leads to difficulties with bladder fibrosis. Over the years, various chemotherapeutics have been investigated, such as cisplatin and carboplatin, but few have resulted in increased survivability and many result in significant toxic side effects. Nonsteroidal anti-inflammatory drugs (NSAIDs), including both nonselective COX inhibitors and selective COX II inhibitors, exhibit anti-carcinoma effects and result in partial remission, disease stabilization, and, less commonly, full remission for dogs with TCC. The MST of dogs treated with piroxicam (0.3 mg/kg PO Q24hr) has been reported to be 210 days, which is comparable to the MSTs achieved with other more toxic chemotherapeutics. GI ulceration can occur with piroxicam because it is a non-selective NSAID and inhibits prostaglandin E₂ (PGE₂). To prevent and treat gastric ulceration, misoprostol, a prostaglandin E analogue, should be administered (100 ug/dog PO TID). Selective COX II inhibitors, such as deracoxib (3 mg/kg PO Q24hr) and meloxicam (0.1 mg/kg PO Q24hr), exhibit less GI irritation and can be used as alternatives. Clinical ulceration can be managed with misoprostol (100 ug/dog PO TID), sucralfate (1/2-1 g PO TID; it should be taken one hour before or after food), and concurrent omeprazole (0.7 mg/kg PO Q24hr). One other negative side effect of COX inhibition is reduced renal blood flow due to prostaglandin and thromboxane inhibition, which can result in azotemia in dogs with subnormal renal function. Therefore, it is imperative to assess the baseline renal function and monitor renal analytes over time in these cases.

INTERPRETED BY

Eric Lindquist, DMV

DABVP, Cert. IVUSS

Piroxicam demonstrates greater therapeutic effectiveness when coupled with other chemotherapeutics, such as mitoxantrone. According to one study, the combination of drugs resulted in an MST of 291 days. Typically, an NSAID is combined with mitoxantrone and/or vinblastine. Current studies are examining the effects of tyrosine kinase inhibitors on TTC and whether it is more effective alone or in combination with piroxicam. Research is also being conducted on the use of metronomic chemotherapy, which entails the long-term administration of a low-dose chemotherapeutic, such as chlorambucil or another agent.

IMAGING PERFORMED BY

Sara Hansen

HOSPITAL NAME

Linn Vet Hospital

Common complications associated with TCC in dogs include local invasion, which results in urethral and ureteral obstruction and hydronephrosis, and metastatic disease, which leads to systemic involvement. Metastasis most commonly affects local and distant lymph nodes, the lungs, and the liver. Twenty percent of TCC patients present with metastasis at the time of diagnosis.

REFERRING VET

Dr. Braat

Urethral obstruction can be treated with an indwelling catheter, intermittent catheterization, or a tube cystotomy; however, the best long-term management entails the insertion of a urethral stent by a specialist trained in Interventional Radiology. Unfortunately, urinary incontinence is a long-term possible complication of stent placement.

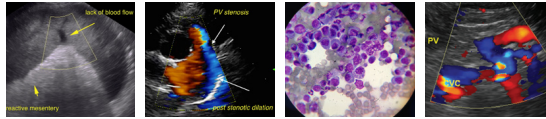
INVOICE

36987

DATE

4/19/22

Many patients often require concurrent—and recurring—treatment for UTIs. Dogs with TCC may have recurrent or chronic UTIs, and the clinician should therefore remain vigilant with respect to this complicating problem.



PATIENT

Gus Johnson

SPECIES

Canine

BREED

Lab x Aussie

SEX

Neutered Male

AGE

14 Years

WEIGHT

56.6 Pounds

INTERPRETED BY

Eric Lindquist, DMV
DABVP, Cert. IVUSS

IMAGING PERFORMED BY

Sara Hansen

HOSPITAL NAME

Linn Vet Hospital

REFERRING VET

Dr. Braat

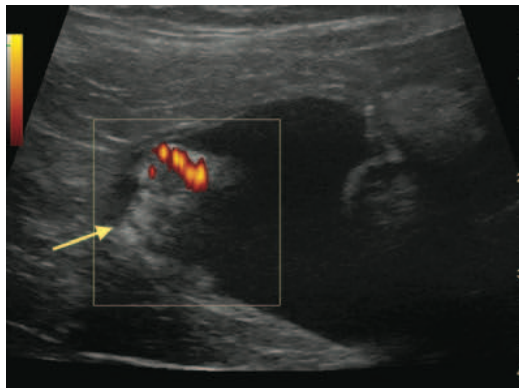
INVOICE

36987

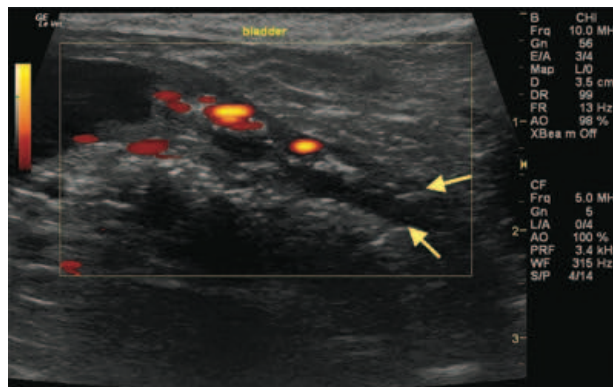
DATE

4/19/22

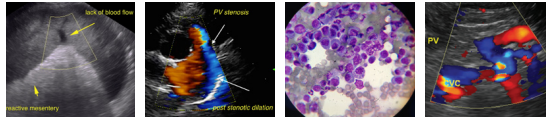
Conclusion: TCC is a frequent cause of bladder neoplasia in dogs. Hematuria, pollakiuria, and dysuria are the most common clinical signs. A multimodal therapy that includes NSAIDs, chemotherapy, stent placement, and possibly endoscopic ablation (UGELAB) may extend disease-free intervals for patients. Cats are much less frequently affected by TCC than dogs.



Short axis of the urinary bladder in a cat with transitional cell carcinoma. An irregular shaped heterogenous mass protruding into the lumen emerges from the right lateral bladder wall (arrow). The power Doppler signal indicates significant intraluminal vascularization and rules out differentials such as hematoma.



Long axis of the bladder neck and urethra in a female dog with transitional cell carcinoma. Note the heterogenous mass lesion occupying the bladder neck. Also note the long extension of the tumor into the pelvic urethra. Arrows indicate the dilated urethral wall owing to hypoechoic tumor infiltration. Considerable vascularity is demonstrated by power Doppler.



PATIENT

Gus Johnson

SPECIES

Canine

BREED

Lab x Aussie

SEX

Neutered Male

AGE

14 Years

WEIGHT

56.6 Pounds

INTERPRETED BY

Eric Lindquist, DMV

DABVP, Cert. IVUSS

IMAGING PERFORMED BY

Sara Hansen

HOSPITAL NAME

Linn Vet Hospital

REFERRING VET

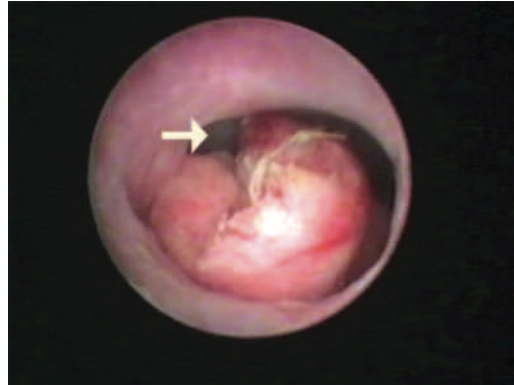
Dr. Braat

INVOICE

36987

DATE

4/19/22



Endoscopic Approach to the UGELAB procedure in a female dog with a urethral tumor visible. Minimal lumen was evident for urine passage (arrow). The patient would pass some urine but with incomplete voiding and resultant pollakiuria and dysuria. Complete ablation of the tumor was performed by UGELAB with normal voiding post procedure. This particular patient needed repeat UGELAB every 3-6 months to remain non clinical.

References:

Blackburn AL, Berent AC, Weisse CW, Brown DC. Evaluation of outcome following urethral stent placement for the treatment of obstructive carcinoma of the urethra in dogs: 42 cases (2004-2008). *J Am Vet Med Assoc* 2013;242(1):59-68.

Boria PA, Glickman NW, Schmidt BR, et al. Carboplatin and piroxicam therapy in 31 dogs with transitional cell carcinoma of the urinary bladder. *Vet Comp Oncol* 2005;3(2):73-80.

Cerf DJ, Lindquist EL. Palliative ultrasound-guided endoscopic diode laser ablation of transitional cell carcinomas of the lower urinary tract in dogs. *J Am Vet Med Assoc* 2012;240(1):51-60.

Glickman LT, Raghavan M, Knapp DW, et al. Herbicide exposure and the risk of transitional cell carcinoma of the urinary bladder in Scottish Terriers. *J Am Vet Med Assoc* 2004;224(8):1290-97.

Henry CJ, Tyler JW, McEntee MC, et al. Evaluation of a bladder tumor antigen test as a screening test for transitional cell carcinoma of the lower urinary tract in dogs. *Am J Vet Res* 2003;64(8):1017-20.

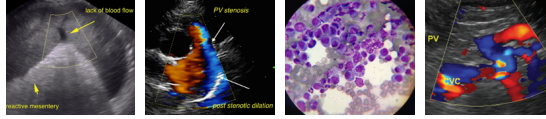
Henry CJ. Management of transitional cell carcinoma. *Vet Clin North Am Small Anim Pract* 2003;33(3):597-613.

Henry CJ. Bladder and urethral tumors. In: Henry CJ, Higginbotham ML, eds. *Cancer Management in Small Animal Practice*. St. Louis, MO: Elsevier; 2010:290.

Knapp DW. Urinary bladder cancer. In: Bonagura J, Twedt D, eds. *Kirk's Current Veterinary Therapy XIV*. St. Louis, MO: Saunders Elsevier; 2008:369-73.

Knapp DW. Ultrasound-guided endoscopic diode laser ablation in dogs with transitional cell carcinoma. *J Am Vet Med Assoc* 2012;240(7):802.

London C. Toceranib phosphate for the treatment of solid tumors in dogs and cats. Proceedings from the American College of Veterinary Internal Medicine, Denver, CO, June 15-18, 2011.



PATIENT

McMillan SK, Boria P, Moore GE, et al. Antitumor effects of deracoxib treatment in 26 dogs with transitional cell carcinoma of the urinary bladder. *J Am Vet Med Assoc* 2011;239(8):1084-89.

Gus Johnson

SPECIES

Mutsaers AJ, Widmer WR, Knapp DW. Canine transitional cell carcinoma. *J Vet Intern Med* 2003;17(2):136-44.

Canine

BREED

Nyland TG, Wallack ST, and Wisner ER. Needle-tract implantation following us-guided fine-needle aspiration biopsy of transitional cell carcinoma of the bladder, urethra, and prostate. *Vet Radiol Ultrasound* 2002;43(1):50-53.

Lab x Aussie

SEX

Raghavan M, Knapp DW, Dawson MH, et al. Topical flea and tick pesticides and the risk of transitional cell carcinoma of the urinary bladder in Scottish Terriers. *J Am Vet Med Assoc* 2004;225(3):389-94.

Neutered Male

AGE

Schremp DR, Childress MO, Stewart JC, et al. Metronomic administration of chlorambucil for treatment of dogs with urinary bladder transitional cell carcinoma. *J Am Vet Med Assoc* 2013;242(11):1534-38.

14 Years

WEIGHT

Weisse C, Berent A, Todd K, et al Evaluation of palliative stenting for management of malignant urethral obstructions in dogs. *J Am Vet Med Assoc* 2006;229(2):226-34.

56.6 Pounds

INTERPRETED BY

Eric Lindquist, DMV

DABVP, Cert. IVUSS

IMAGING PERFORMED BY

Sara Hansen

HOSPITAL NAME

Linn Vet Hospital

REFERRING VET

Dr. Braat

INVOICE

36987

DATE

4/19/22