



PATIENT PRESENTING CLINICAL SIGNS

PATIENT
Boo Northstar Pet Rescue
Pre-anesthetic CUS for dental. Current meds: Doxy
Abnormal PE/Chem/CBC/UA Results: wnl

SPECIES ULTRASONOGRAPHIC EXAMINATION OF THE HEART

SPECIES
Canine
The echocardiogram in this patient demonstrated normal **left atrial** size based on 3 separate methods of LA evaluation. Trivial, centralized **mitral** valve insufficiency was noted, yet not clinically significant. The **left ventricle** presented thicknesses with linear contour and was not dilated nor restricted. The **myocardium** presented normal echogenicity without subjective evidence of significant fibrotic or ischemic disease. **Contractility** of the ventricular walls was adequate and in normal range for this patient evidenced by the fractional shortening measurement and subjective evaluation of the different regions of the myocardium. Trivial **aortic insufficiency** tract was noted, yet not clinically significant. The **right atrium** and auricle revealed normal size, structure and content. No evidence of masses was noted. **Tricuspid** valvular assessment demonstrated adequate linear morphology and kinesis. The **right ventricle** was of normal size (1/3 diameter of LV), chordae structure, myocardial echogenicity and thickness. **Pulmonary outflow** tract assessment revealed normal valve structure, laminar flow, and diameter (approx. 1:1 pa/ao ratio). No visible **pericardial** or free pleura fluid was noted. The cranial **mediastinum and pericardial and extra-cardiac regions** were free of masses in the visible window.

BREED

Miniature Poodle

SEX

Neutered male

AGE

10 years

WEIGHT

11 lbs

INTERPRETED BY

Eric Lindquist, DMV
DABVP, Cert. IVUSS

IMAGING PERFORMED BY

Shari Reffi, CVT

HOSPITAL NAME

Rockaway AH

CANINE CARDIAC PARAMETERS	MR VMAX (m/s)	TR VMAX (m/s)	LA/AO (Boon method)	LA/AO (Heart Base; Swe)	FS (%)	EF (%)	EPSS (cm)
NORMAL PARAMETER	4.5-5.5	<2.7	1.3	<1.3	28-40	40-100	<0.6
PATIENT			1.0	1.2	36	38	NM
CANINE CARDIAC PARAMETERS	HR (BPM)	AV VMAX (m/s)	PV MAX (m/s)	BODY WEIGHT	LA (2D short axis Base view) (cm)	LVIDd (Avg; 2D and m-mode short axis) (cm)	LVIDs (Avg; 2D and m-mode short axis) (cm)
NORMAL PARAMETER	50-100	0.7-1.7	0.7-1.6				
PATIENT	128	1.0	0.8	11 lbs	2.0 max	2.31	

REFERRING VET ULTRASONOGRAPHIC FINDINGS

Dr. Bednar
Stage B1 valvular disease.
Trivial mitral insufficiency, not clinically significant.

INVOICE

99381

DATE

4/19/22

INTERPRETATION OF THE FINDINGS & FURTHER RECOMMENDATIONS

There is no contraindication to anesthetic procedure.



PATIENT

Boo Northstar Pet Rescue

SPECIES

Canine

BREED

Miniature Poodle

SEX

Neutered male

AGE

10 years

WEIGHT

11 lbs

INTERPRETED BY

Eric Lindquist, DMV
DABVP, Cert. IVUS

IMAGING PERFORMED BY

Shari Reffi, CVT

HOSPITAL NAME

Rockaway AH

REFERRING VET

Dr. Bednar

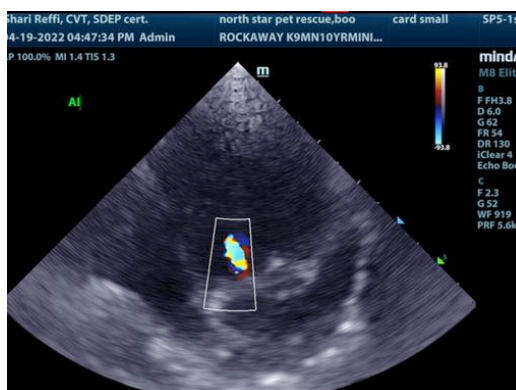
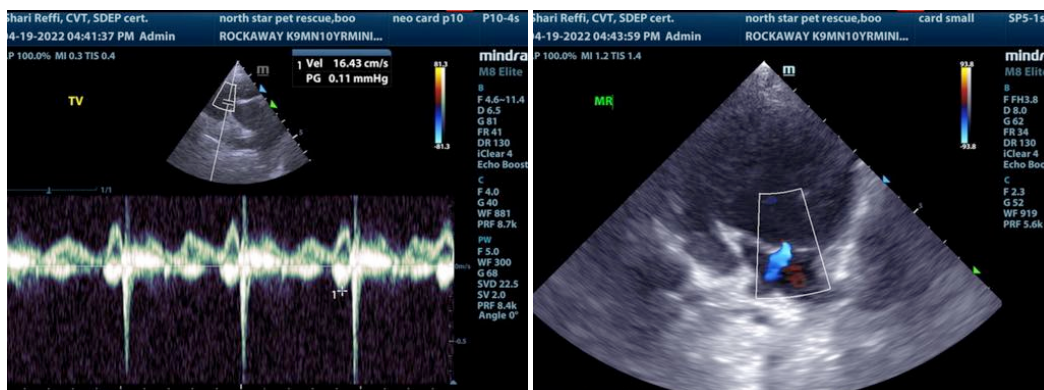
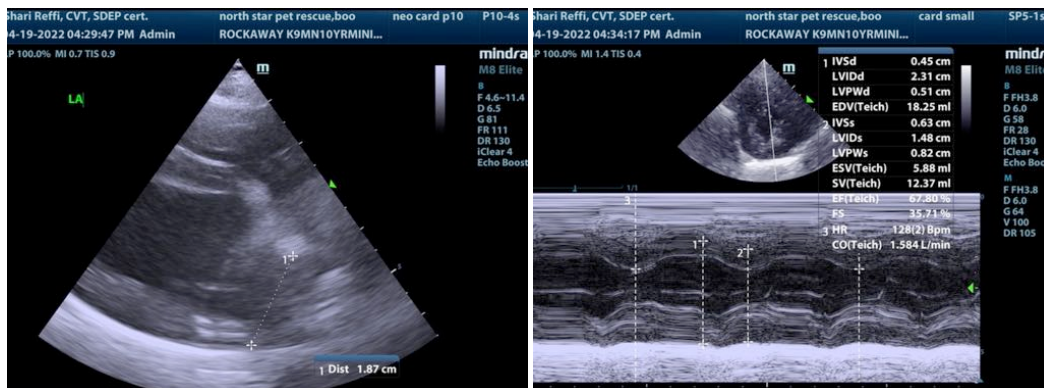
INVOICE

99381

DATE

4/19/22

B1: The heart is stable without clinical disease. No overt contraindication for anesthesia of brief to moderate duration. I suggest Torbutrol premed, Propofol induction, Isoflurane maintenance or similar protocol if anesthesia is desired. Blood pressure recommended if not already performed and target white coat negative systolic pressure of < 160 mmHg. If higher than this ACE-inhibitor is suggested to reach this level. Recheck echocardiogram is recommended in 6 months, earlier if murmur grade increases or clinical signs initiate.



The information and recommendations provided are based on the images presented by the referring veterinarian/sonographer. No evaluation can be communicated regarding pathology that was not visible in the image/video clips provided.

Thank you for this referral. If the clinical or image interpretation does not parallel your findings or if I



PATIENT

can be of any further assistance please contact me.

Boo Northstar Pet
Rescue

Eric Lindquist, DMV, DABVP, Cert. IVUSS, CEO of SonoPath.com
Info@SonoPath.com

SPECIES

Canine

BREED

Miniature Poodle

SEX

Neutered male

AGE

10 years

WEIGHT

11 lbs

INTERPRETED BY

Eric Lindquist, DMV
DABVP, Cert. IVUSS

**IMAGING
PERFORMED BY**

Shari Reffi, CVT

HOSPITAL NAME

Rockaway AH

REFERRING VET

Dr. Bednar

INVOICE

99381

DATE

4/19/22