



PATIENT

Auburn Harper

SPECIES

Feline

BREED

Domestic Shorthair

SEX

Spayed Female

AGE

1 year

WEIGHT

3.76 kg

INTERPRETED BY

Eric Lindquist, DMV
DABVP, Cert. IVUSS

IMAGING PERFORMED BY

CVN

HOSPITAL NAME

Animal Emergency
Hospital Volusia

REFERRING VET

Dr. Nieuwal

INVOICE

99330

DATE

4/18/22

PRESENTING CLINICAL SIGNS

PP for recheck today for vomiting and anorexia. P was seen on 4/15 for similar issue and was hospitalized on IV fluids, IV unasyn, cerenia, metro, and famotidine. DDX gastroenteritis vs pancreatitis vs other. P went home on 4/16 and has seen little improvement. Vitals WNL on presentation today, abdomen tense with gas filled intestines.

ULTRASONOGRAPHIC EXAMINATION OF THE ABDOMEN

Urinary System

The **urinary bladder**, trigone, and pelvic urethra presented normal thicknesses and normal tone. The ureters were not visible which is normal. No uroliths or sediment were visualized and anechoic urine was present. No evidence of inflammatory or neoplastic changes was noted. Ureteral papillae were normal.

The **kidneys** revealed normal size and structure, corticomedullary definition and ratio for this age. The cortices presented largely uniform texture with normal echogenic relationship to liver and spleen. Medullary structure differed distinctly from the cortex and no evidence of pelvic dilation was present. The capsules were acceptably uniform without significant irregularities. The left kidney measured 3.0 cm. The right kidney measured 3.0 cm.

Adrenal Glands

Both **adrenal glands** were visualized and recognized as having normal shape, size, position and echogenicity for this breed. The phrenic vasculature, glandular echogenicity and detail were unremarkable. Capsule, cortex, and medullary definition were normal for this age patient.

Spleen

The **spleen** presented a smooth homogeneous parenchyma hyperechoic to liver and renal cortical parenchyma. The capsule was smooth without noticeable expansion or deviation from within the spleen or adjacent pathology. The splenic vasculature demonstrated normal volume without signs of congestion or thrombosis. No sonographic evidence of acute or chronic inflammatory, neoplastic, or infarctual changes was noted.

Liver

The **liver** images submitted revealed subjectively normal liver size, contour, and structure. Parenchymal echogenicity was naturally coarse and hypoechoic to the spleen. Vascular and biliary tracts were of normal volume with no evidence of congestion. The gallbladder presented acceptably thin walls with primarily anechoic content. The cystic and common bile ducts were normal. No pathological hepatic lymphadenopathy was evident. No overt structural evidence of inflammatory, infiltrative or regenerative pathology was evident.



PATIENT

Gastrointestinal

Auburn Harper

The **gastrointestinal** presentation revealed mild uniform prominence of the gastric mucosa as well as areas of "ropey" small intestinal wall with slight disruption of the normal 1:3 muscularis/mucosal ratio. The intestinal submucosa was slightly irregular, thickened and hyperechoic suggestive of low grade, chronic disease. No concerning lymphadenopathy was visible. No evidence of obstruction was present. Mild reactive mesentery was note and primarily localized in the small intestine.

SPECIES

Feline

BREED

Pancreas

Domestic Shorthair

Minor, heterogenous **pancreatic** changes were noted in the left limb.

SEX

Spayed Female

ULTRASONOGRAPHIC FINDINGS

Minor intestinal and pancreatic inflammation. Inflammatory bowel and pancreatitis is likely.

AGE

1 year

INTERPRETATION OF THE FINDINGS & FURTHER RECOMMENDATIONS

Assessment for underlying infectious agents such as Toxoplasmosis and Bartonella would be recommended. A clinical trial of the following may prove effective.

WEIGHT

3.76 kg

Triaditis/Pancreatitis protocol

INTERPRETED BY

Part or all of this protocol may be considered based on your clinical impression of the patient:

Eric Lindquist, DMV
DABVP, Cert. IVUSS

Recommend pain management when anorexic with **Buprenorphine** (0.01-0.02 mg/kg IM or SC), clinical trial of **Zithromax** (50 mg sid/cat x 10 days, 3 weeks if bartonella +), **Prednisolone** (0.5-2 mg/kg tapering over 1 week to minimal effective dose), and **B12 injections** if weight loss (Cyanobalamine 250 mcg sub-q once-weekly x six weeks, then every other week for six weeks and then once-monthly, long-term if necessary), **novel-protein or hydrolyzed diet** (*Hydrolyzed diets have been shown to be more effective in dietary intolerance case management compared to hypoallergenic diets*) or the **magical Purina DM** (changing protein source is crucial and may need rotation every 6 months if clinical signs recur) Diet trials is a whatever works phenomenon. If vomiting becomes a persistent issue then endoscopy would be warranted and/or recheck sonogram to assess more emerging disease. One diet does not work for all patients so different trials may be necessary or protein source rotation every 6 months as new sensitivities develop.

IMAGING PERFORMED BY

CVN

HOSPITAL NAME

Animal Emergency
Hospital Volusia

REFERRING VET

Dr. Nieuwal

INVOICE

99330

DATE

4/18/22



PATIENT

Auburn Harper

SPECIES

Feline

BREED

Domestic Shorthair

SEX

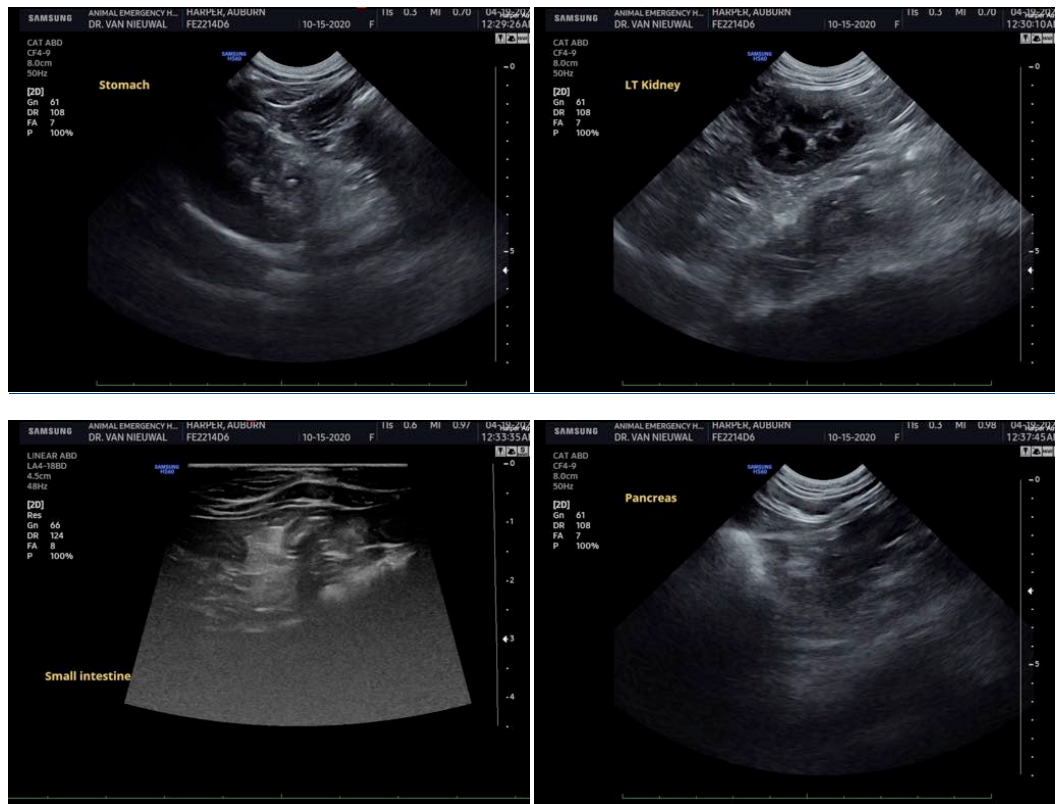
Spayed Female

AGE

1 year

WEIGHT

3.76 kg



INTERPRETED BY

Eric Lindquist, DMV
DABVP, Cert. IVUSS

IMAGING PERFORMED BY

CVN

HOSPITAL NAME

Animal Emergency
Hospital Volusia

REFERRING VET

Dr. Nieuwal

INVOICE

99330

DATE

4/18/22

The information and recommendations provided are based on the images presented by the referring veterinarian/sonographer. No evaluation can be communicated regarding pathology that was not visible in the image/video clips provided.

Thank you for this referral. If the clinical or image interpretation does not parallel your findings or if I can be of any further assistance please contact me.

Eric Lindquist, DMV, DABVP, Cert. IVUSS, CEO of SonoPath.com
info@SonoPath.com