



PATIENT PRESENTING CLINICAL SIGNS

Apollo Foxhill

SPECIES

Canine

BREED

Doberman

SEX

Neutered male

AGE

18 months

WEIGHT

90 lbs

INTERPRETED BY

Eric Lindquist, DMV
DABVP, Cert. IVUSS

IMAGING PERFORMED BY

Dr. Kitz

HOSPITAL NAME

Woodlands AH

REFERRING VET

Dr. Kitz

INVOICE

43879

DATE

4/18/23

History: Patient presented a few weeks ago with history of non-productive hacking cough, and he typically goes to daycare.... suspected infectious tracheobronchitis... cough was not improving until hydrocodone added to the mix, and then he still wasn't getting completely back to normal after a week so the owners brought him back last week for recheck...xrays taken at that time and it was suspected that he had a peritoneal-pericardial diaphragmatic hernia. On presentation today the owner says his cough is improved, but now the other pet in the home is coughing and Apollo is still not eating well. Abnormal PE/Chem/CBC/UA Results: Respiratory PCR panel - all negative See attached xray report for summary ECG normal BP normal at 140 systolic No overt murmur, normal pulses, refill; patient is BAR Discussed with owner that he will need referral to a specialty center for surgical repair if hernia is confirmed, but wanted to take a look and be sure there was no occult heart disease going on prior to referral for CT and surgical consult. He had pre-op labwork for neuter at the end of 2022 and all was normal, no issues with neuter anesthesia or recovery

ULTRASONOGRAPHIC EXAMINATION OF THE ABDOMEN

Urinary System

The **urinary bladder**, trigone, and pelvic urethra presented normal thicknesses and normal tone. The ureters were not visible which is normal. No uroliths or sediment were visualized and anechoic urine was present. No evidence of inflammatory or neoplastic changes was noted. Ureteral papillae were normal.

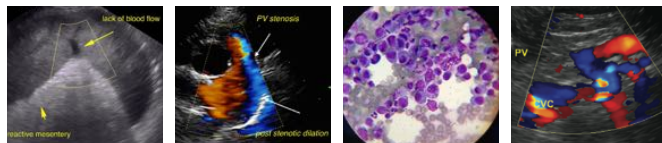
The **kidneys** revealed normal size and structure, corticomedullary definition and ratio for this age. The cortices presented largely uniform texture with normal echogenic relationship to liver and spleen. Medullary structure differed distinctly from the cortex and no evidence of pelvic dilation was present. The capsules were acceptably uniform without significant irregularities. The right kidney measured 7.5 cm. The left kidney measured 7.5 cm.

Adrenal Glands

Both **adrenal glands** were visualized and recognized as having normal shape, size, position and echogenicity for this breed. The phrenic vasculature, glandular echogenicity and detail were unremarkable. Capsule, cortex, and medullary definition were normal for this age patient. The left adrenal gland measured 0.51 cm at the caudal pole and 0.61 cm at the cranial pole. The right adrenal gland measured 0.57 cm at the cranial pole and 0.43 cm at the caudal pole.

Spleen

The **spleen** presented a smooth homogeneous parenchyma hyperechoic to liver and renal cortical parenchyma. The capsule was smooth without noticeable expansion or deviation from within the spleen or adjacent pathology. The splenic vasculature demonstrated normal volume without signs of congestion or thrombosis. No sonographic evidence of acute or chronic inflammatory, neoplastic, or infarctual changes was noted.



PATIENT

Liver

Apollo Foxhill

The **liver** images submitted revealed subjectively normal liver size, contour, and structure. Parenchymal echogenicity was naturally coarse and hypoechoic to the spleen. Vascular and biliary tracts were of normal volume with no evidence of congestion. The gallbladder presented acceptably thin walls with primarily anechoic content. The cystic and common bile ducts were normal. No pathological hepatic lymphadenopathy was evident. No overt structural evidence of inflammatory, infiltrative or regenerative pathology was evident.

SPECIES

Canine

BREED

Doberman

Gastrointestinal

SEX

Neutered male

Examination of the **gastrointestinal tract** revealed a stomach free of stasis, of normal wall thickness, acceptable curvilinear mural detail, and peristaltic activity. The upper duodenum revealed a minor amount of focal stasis, yet not overtly pathological. The duodenal stasis was noted at the flexure. This is likely a positional variant. Soft stool was noted in the colon.

AGE

18 months

Pancreas

WEIGHT

90 lbs

The base and limbs of the **pancreas** were observed to be largely isoechoic to surrounding omental fat. Pancreatic duct and capsular contour were acceptably normal and parenchyma respected normal curvilinear patterns. No overt evidence of active inflammatory or neoplastic disease was noted.

Free Abdomen

INTERPRETED BY

Eric Lindquist, DMV
DABVP, Cert. IVUS

The cranial abdomen revealed a herniated falciform of approximately 5.0 cm into the chest. This appeared to be connected to the pericardium and is consistent with pleural pericardial diaphragmatic hernia of the falciform fat. There was no effect upon the heart from a functional standpoint noted.

IMAGING PERFORMED BY

Dr. Kitz

ULTRASONOGRAPHIC EXAMINATION OF THE HEART

HOSPITAL NAME

Woodlands AH

The echocardiogram in this patient demonstrated normal **left atrial** size based on 3 separate methods of LA evaluation. The cranial and caudal **mitral** valve leaflets presented normal linear structure, extension in systole, and union in diastole with normal kinesis. The **left ventricle** presented thicknesses with linear contour and was not dilated nor restricted. The **myocardium** presented normal echogenicity without subjective evidence of significant fibrotic or ischemic disease. **Contractility** of the ventricular walls was adequate and in normal range for this patient evidenced by the fractional shortening measurement and subjective evaluation of the different regions of the myocardium. The **left ventricular outflow** tract demonstrated normal laminar flow and subjective structural integrity. The **right atrium** and auricle revealed normal size, structure and content. No evidence of masses was noted. **Tricuspid** valvular assessment demonstrated adequate linear morphology and kinesis. The **right ventricle** was of normal size (1/3 diameter of LV), chordae structure, myocardial echogenicity and thickness. **Pulmonary outflow** tract assessment revealed normal valve structure, laminar flow, and diameter (approx. 1:1 pa/ao ratio). No visible **pericardial** or free pleura fluid was noted. The cranial **mediastinum and pericardial and extra-cardiac regions** were free of masses in the visible window.

REFERRING VET

Dr. Kitz

INVOICE

43879

DATE

4/18/23


PATIENT

Apollo Foxhill

SPECIES

Canine

BREED

Doberman

SEX

Neutered male

AGE

18 months

WEIGHT

90 lbs

CANINE CARDIAC PARAMETERS	MR VMAX (m/s)	TR VMAX (m/s)	LA/AO (Boon method)	LA/AO (Heart Base;)	FS (%)	EF (%)	EPSS (cm)
NORMAL PARAMETER	4.5- 5.5	<2.7	1.3	<1.6	28-40	40-100	<0.6
PATIENT			1.0	1.26	25	49	0.1
CANINE CARDIAC PARAMETERS	HR (BPM)	AV VMAX (m/s)	PV MAX (m/s)	BODY WEIGHT	LA 2D short axis Base view (cm)	LVIDd Avg; 2D and m- mode short axis (cm)	LVIDs Avg; 2D and m- mode short axis (cm)
NORMAL PARAMETER	50- 100	0.7-1.7	0.7-1.6	BELOW	BELOW	BELOW	BELOW
PATIENT		1.0 likely underestimated due to acoustic interference	1.46	90 lbs	4.1	4.19	

ULTRASONOGRAPHIC FINDINGS

Normal abdomen, minor focal duodenal stasis.

Normal echocardiogram, no evidence of pathology.

Suspect pericardial diaphragmatic hernia of falciform fat. This is not a functional issue and appears to be stable.

INTERPRETED BY

 Eric Lindquist, DMV
 DABVP, Cert. IVUSS

**IMAGING
PERFORMED BY**

Dr. Kitz

HOSPITAL NAME

Woodlands AH

REFERRING VET

Dr. Kitz

INVOICE

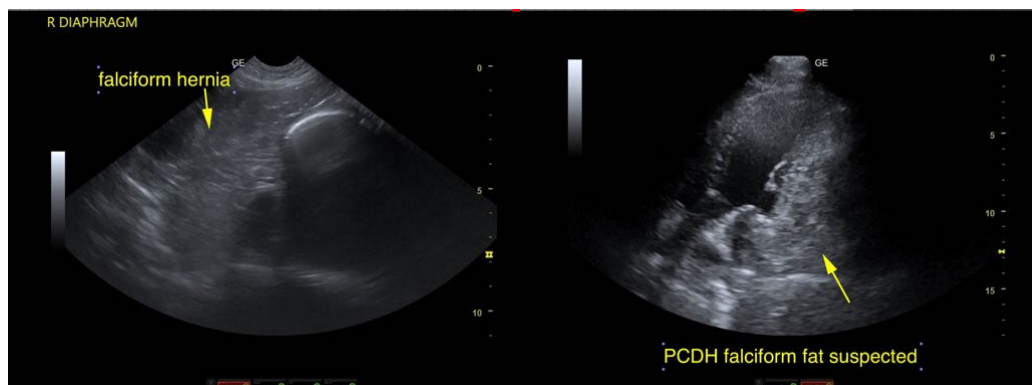
43879

DATE

4/18/23

INTERPRETATION OF THE FINDINGS & FURTHER RECOMMENDATIONS

I recommend reevaluation of the upper GI tract if any GI signs are present. CT evaluation would be warranted for further definition. There is no evidence of cardiac disease that would be contributing to the cough; however, theoretically respiratory expansion is likely hindered owing to the suspected pericardial diaphragmatic hernia. This will exacerbate any respiratory disease.





PATIENT

Apollo Foxhill

SPECIES

Canine

BREED

Doberman

SEX

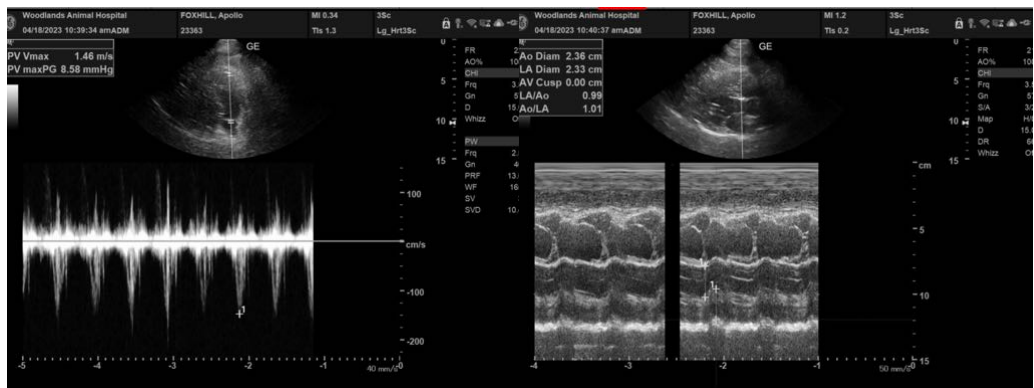
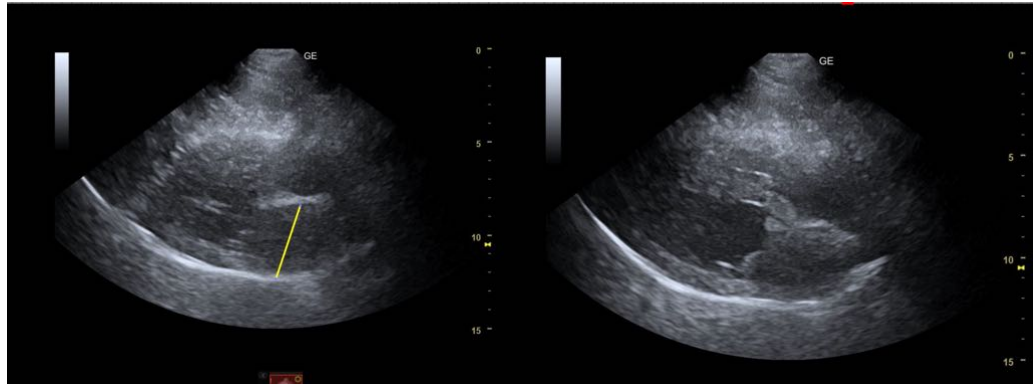
Neutered male

AGE

18 months

WEIGHT

90 lbs



INTERPRETED BY

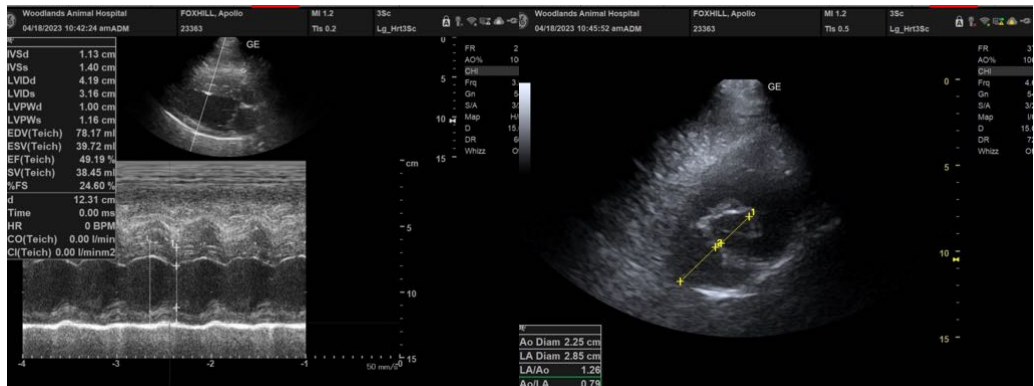Eric Lindquist, DMV
DABVP, Cert. IVUSS

IMAGING PERFORMED BY

Dr. Kitz

HOSPITAL NAME

Woodlands AH



REFERRING VET

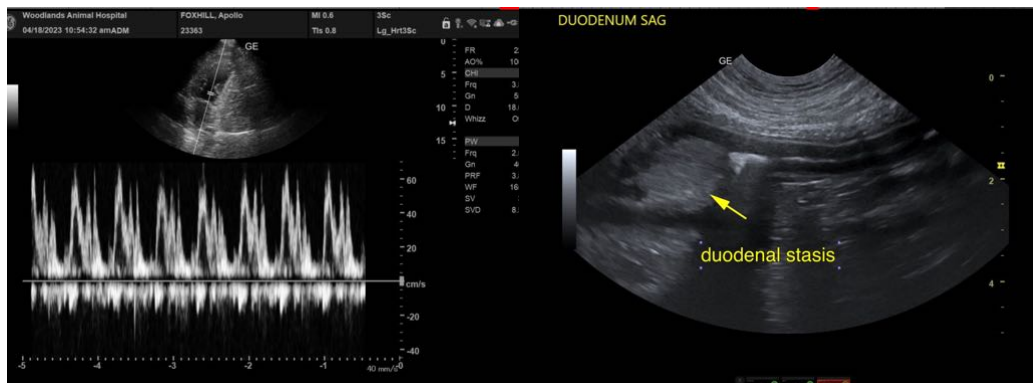Dr. Kitz

INVOICE

43879

DATE

4/18/23





PATIENT

Apollo Foxhill

SPECIES

Canine

BREED

Doberman

SEX

Neutered male

AGE

18 months

WEIGHT

90 lbs

INTERPRETED BY

Eric Lindquist, DMV
DABVP, Cert. IVUSS

IMAGING PERFORMED BY

Dr. Kitz

HOSPITAL NAME

Woodlands AH

REFERRING VET

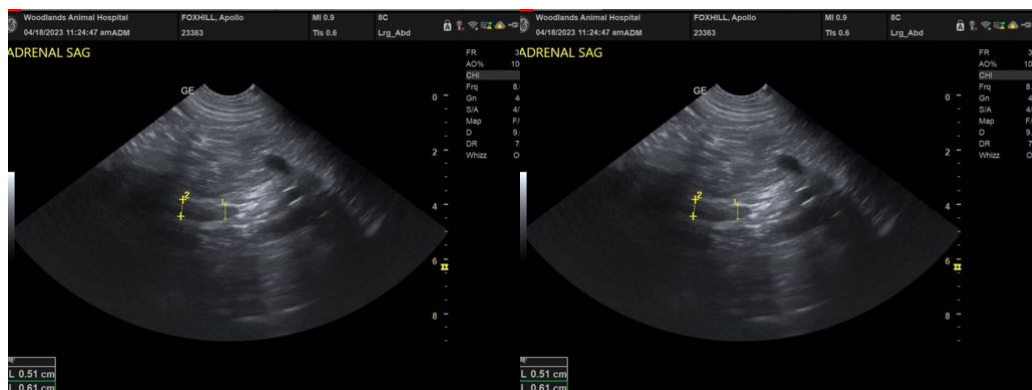
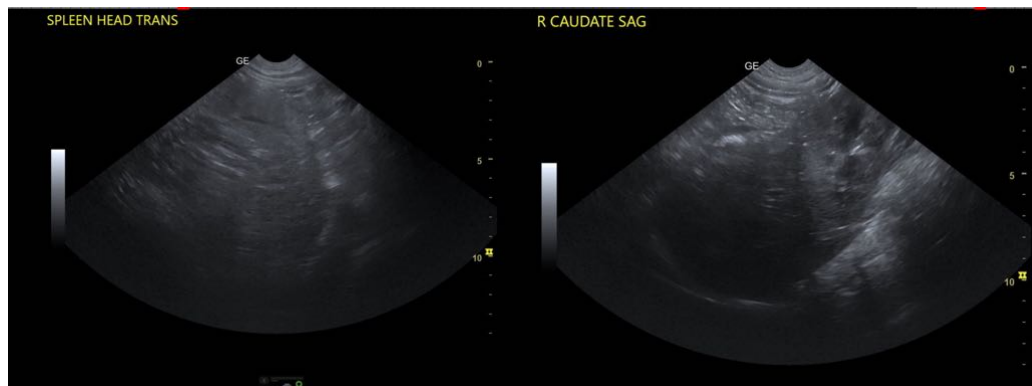
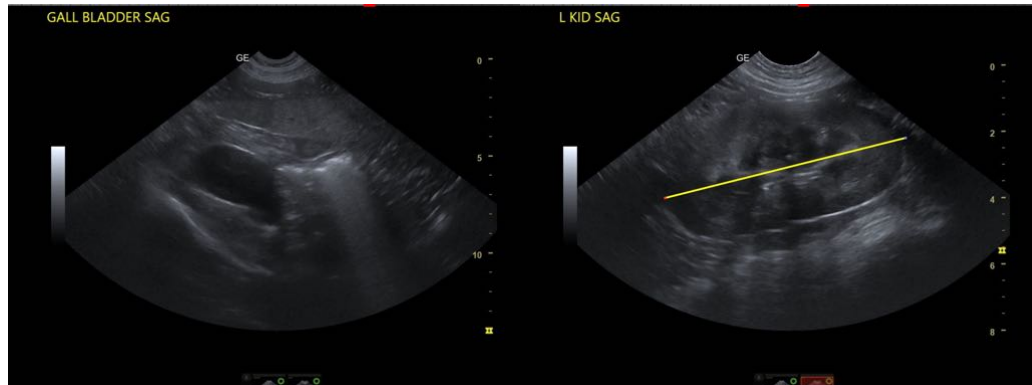
Dr. Kitz

INVOICE

43879

DATE

4/18/23



The information and recommendations provided are based on the images presented by the referring veterinarian/sonographer. No evaluation can be communicated regarding pathology that was not visible in the image/video clips provided.

Thank you for this referral. If the clinical or image interpretation does not parallel your findings or if I can be of any further assistance please contact me.

Eric Lindquist, DMV, DABVP, Cert. IVUSS, CEO of SonoPath.com
info@SonoPath.com