



**PATIENT**

Sugar Sebby

**SPECIES**

Canine

**BREED**

Poodle Cross

**SEX**

Spayed Female

**AGE**

10 years

**WEIGHT**

10.1 lbs

**INTERPRETED BY**

Eric Lindquist, DMV  
DABVP, Cert. IVUSS

**IMAGING PERFORMED BY**

Dr. Rodriguez

**HOSPITAL NAME**

Foxfield VS

**REFERRING VET**

Dr. Rodriguez

**INVOICE**

99334

**DATE**

4/18/22

**PRESENTING CLINICAL SIGNS**

Presented for dry heaving in the past and again yesterday. Normal BM, Decreased appetite. Lethargy. Hx of IMHA and pancreatitis. Began denamarin today and HA wet food  
Abnormal PE/Chem/CBC/UA Results: RET: 170, PLT: 863, RBC: 6.86, HCT: 42, ALT: 169, Alk: 248, GGT: 21

**ULTRASONOGRAPHIC EXAMINATION OF THE ABDOMEN**

**Urinary System**

The **urinary bladder**, trigone, and pelvic urethra presented normal thicknesses and normal tone. The pelvic urethra was imaged 2.0 cm beyond the cystourethral junction. The ureters were not visible which is normal. No uroliths or sediment were visualized and anechoic urine was present. No evidence of inflammatory or neoplastic changes was noted. Ureteral papillae were normal.

The **kidneys** revealed normal size and structure, corticomedullary definition and ratio for this age. The cortices presented largely uniform texture with normal echogenic relationship to liver and spleen. Medullary structure differed distinctly from the cortex and no evidence of pelvic dilation was present. The capsules were acceptably uniform without significant irregularities. The left kidney measured 3.97 cm. The right kidney measured 3.82 cm.

**Adrenal Glands**

Both **adrenal glands** were visualized and recognized as having normal shape, size, position and echogenicity for this breed. The phrenic vasculature, glandular echogenicity and detail were unremarkable. Capsule, cortex, and medullary definition were normal for this age patient. The left adrenal gland measured 1.72 x 0.59 cm. The right adrenal gland measured 1.46 x 0.59 cm.

**Spleen**

The **spleen** presented a smooth homogeneous parenchyma hyperechoic to liver and renal cortical parenchyma. The capsule was smooth without noticeable expansion or deviation from within the spleen or adjacent pathology. The splenic vasculature demonstrated normal volume without signs of congestion or thrombosis. No sonographic evidence of acute or chronic inflammatory, neoplastic, or infarctual changes was noted.

**Liver**

The **liver** revealed mildly increased portal markings with coarse architecture and non-specific hepatic remodeling. Minor gallbladder calculi and sand were noted. This is non-obstructive. The gallbladder wall was slightly echogenic.



**PATIENT**

**Gastrointestinal**

Sugar Sebby

The pylorus was mildly thickened with hypertrophied muscularis and echogenic hypertrophied mucosal changes in the pyloric outflow measuring up to 0.93 cm. There were areas of mucosal speckling were noted in the small intestine.

**SPECIES**

Canine

**Pancreas**

**BREED**

Poodle Cross

The base and limbs of the **pancreas** were observed to be largely isoechoic to surrounding omental fat. Pancreatic duct and capsular contour were acceptably normal and parenchyma respected normal curvilinear patterns. No overt evidence of active inflammatory or neoplastic disease was noted.

**SEX**

Spayed Female

**ULTRASONOGRAPHIC FINDINGS**

Pyloric thickening with hypertrophied mucosal changes. Aspects of hypertrophic pyloric gastropathy.

**AGE**

10 years

Gallbladder calculi and non-specific inflammatory hepatopathy.

**WEIGHT**

10.1 lbs

**INTERPRETATION OF THE FINDINGS & FURTHER RECOMMENDATIONS**

Endoscopy would be ideal in this patient to obtain mucosal biopsies in the pyloric antrum; however, empirical trial of the following may prove effective. B.i.d. wet food is recommended after 24 hour n.p.o. as any bulk will likely cause issues in this patient given the pyloric hypertrophy. Ursodiol therapy can be considered long term in an attempt to dissolve the biliary sand/small calculi that are present. A recheck sonogram is recommended in 3-4 weeks unless clinical signs worsen.

**INTERPRETED BY**

Eric Lindquist, DMV  
DABVP, Cert. IVUSS

**IMAGING PERFORMED BY**

Dr. Rodriguez

**Helicobacter/Gastritis protocol**

A clinical trial of **Zithromax (Dogs: 5-10 mg/kg p.o. q24h. May increase dosing interval to q48h after 3-5 days of treatment)**, **Metronidazole (10-20 mg/kg p.o. b.i.d.)**, **Sucralfate (0.5-2 g/dog PO)** and **Omeprazole (1 mg/kg p.o. s.i.d.)** over the next 3 weeks along with a **novel-protein or hydrolyzed diet** with slurry feeding b.i.d./t.i.d. over the next 2-4 days and then increase to canned diet bid. Dry food should be avoided over the next 4 weeks. A recheck sonogram to assess GI improvement or progression would be ideal in 4 weeks.

**HOSPITAL NAME**

Foxfield VS

**REFERRING VET**

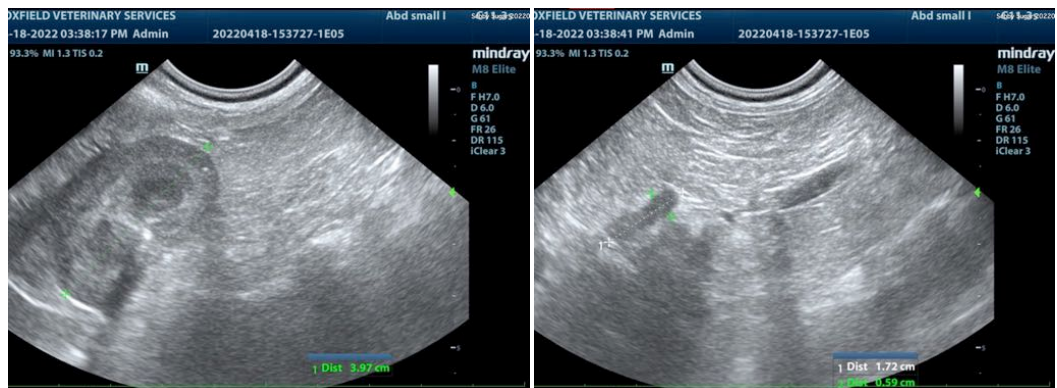
Dr. Rodriguez

**INVOICE**

99334

**DATE**

4/18/22





**PATIENT**

Sugar Sebby

**SPECIES**

Canine

**BREED**

Poodle Cross

**SEX**

Spayed Female

**AGE**

10 years

**WEIGHT**

10.1 lbs

**INTERPRETED BY**

Eric Lindquist, DMV  
DABVP, Cert. IVUSS

**IMAGING PERFORMED BY**

Dr. Rodriguez

**HOSPITAL NAME**

Foxfield VS

**REFERRING VET**

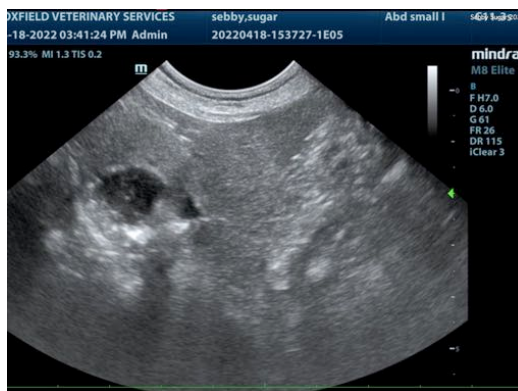
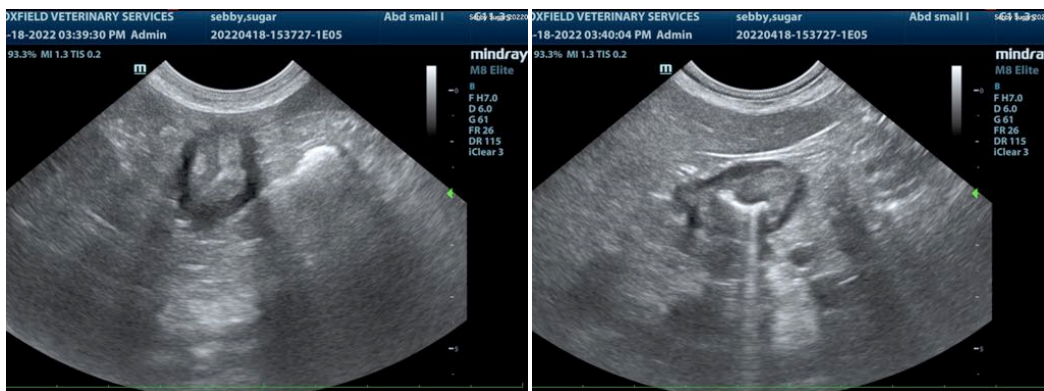
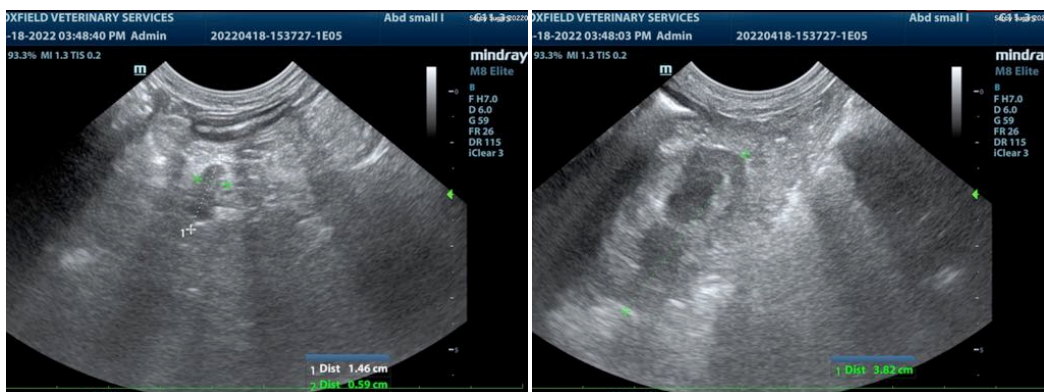
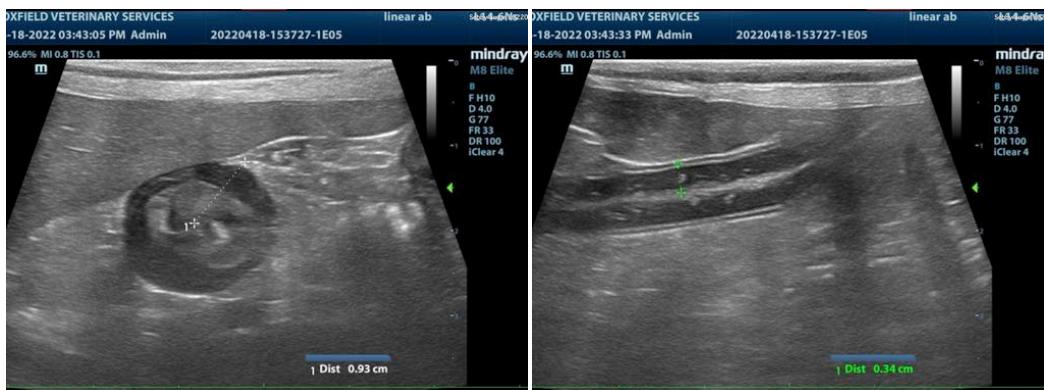
Dr. Rodriguez

**INVOICE**

99334

**DATE**

4/18/22





**PATIENT**

Sugar Sebbby

**SPECIES**

Canine

**BREED**

Poodle Cross

**SEX**

Spayed Female

**AGE**

10 years

**WEIGHT**

10.1 lbs

**INTERPRETED BY**

Eric Lindquist, DMV  
DABVP, Cert. IVUSS

**IMAGING  
PERFORMED BY**

Dr. Rodriguez

**HOSPITAL NAME**

Foxfield VS

**REFERRING VET**

Dr. Rodriguez

**INVOICE**

99334

**DATE**

4/18/22

The information and recommendations provided are based on the images presented by the referring veterinarian/sonographer. No evaluation can be communicated regarding pathology that was not visible in the image/video clips provided.

Thank you for this referral. If the clinical or image interpretation does not parallel your findings or if I can be of any further assistance please contact me.

**Eric Lindquist**, DMV, DABVP, Cert. IVUSS, CEO of SonoPath.com  
info@SonoPath.com