



PATIENT

Lola Russo

SPECIES

Feline

BREED

DSH

SEX

Spayed Female

AGE

12 Years 10 Months

WEIGHT

12.8 pounds

INTERPRETED BY

Eric Lindquist, DMV,
DABVP(CFM), Cert.
IVUSS

IMAGING PERFORMED BY

Chloe Lowe CVT

HOSPITAL NAME

Blairstown Animal
Hospital

REFERRING VET

Dr. Clegg

INVOICE

15174

DATE

04/17/26

PRESENTING CLINICAL SIGNS

Anorexia, abdominal pain. Cerenia and gabapentin

Abnormal PE/Chem/CBC/UA Results: Mg 2.7 K 5.7

ULTRASONOGRAPHIC EXAMINATION OF THE ABDOMEN

Urinary System

The **urinary bladder**, trigone, and pelvic urethra presented normal thicknesses and normal tone. The ureters were not visible which is normal. No uroliths or sediment were visualized, and anechoic urine was present. No evidence of inflammatory or neoplastic changes were noted. Ureteral papillae were normal.

The **kidneys** revealed largely normal size and structure, corticomedullary definition and ratio (cortex 1/3 of medulla) were essentially maintained with some mild age-related loss of curvilinear patterns regarding the capsule and C/M junction. The cortices presented largely uniform texture with some increased echogenicity expected for his age patient. Medullary structure differed distinctly from that of the cortex and no evidence of pelvic dilation was present. The left kidney measured 3.95 cm in length. The right kidney measured 3.55 cm in length.

Adrenal Glands

Both **adrenal glands** were visualized and recognized as having normal shape, size, position and echogenicity for this breed. The phrenic vasculature, glandular echogenicity and detail were unremarkable. Capsule, cortex, and medullary definition were normal for this age patient. The left adrenal gland measured 0.42 cm width. The right adrenal gland measured 0.43 cm width.

Spleen

The **spleen** presented enlarged with scalloping contour and uniform parenchyma measuring 1.8 cm width, which is near double the normal size.

Liver

The **liver** images submitted revealed subjectively normal liver size, contour, and structure. Parenchymal echogenicity was naturally coarse and hypoechoic to the spleen. Vascular and biliary tracts were of normal volume with no evidence of passive congestion. The gallbladder presented acceptably thin walls with primarily anechoic content. The cystic and common bile ducts were normal. No pathological hepatic lymphadenopathy was evident. No overt structural evidence of inflammatory, infiltrative or regenerative pathology was evident.

Gastrointestinal

Examination of the **gastrointestinal tract** revealed a stomach and intestine free of stasis, of normal wall thickness, acceptable curvilinear mural detail, and peristaltic activity. Small and large intestine demonstrated normal luminal chyme and stool consistency respectively. No obstructive or overt infiltrative disease was noted. No associated abnormal lymphatic activity was noted.

Pancreas



PATIENT

Lola Russo

The base and limbs of the **pancreas** were observed to be largely isoechoic to surrounding omental fat. Pancreatic duct and capsular contour were acceptably normal and parenchyma respected normal curvilinear patterns. No overt evidence of active inflammatory or neoplastic disease was noted.

SPECIES

Feline

Free Abdomen

A moderate amount of **free fluid** was noted in the abdomen. Coalesced omentum and nodular changes were noted with enveloping mixed echogenic omentum. The mixed echogenic omentum is enveloping the upper gastrointestinal tract.

BREED

DSH

ULTRASONOGRAPHIC FINDINGS

- Lymphomatosis/carcinomatosis type presentation.

SEX

Spayed Female

INTERPRETATION OF THE FINDINGS & FURTHER RECOMMENDATIONS

Splenic FNA and abdominocentesis with cytospin and immediate slide preparation is recommended. Carcinomatosis and FIP are possible, yet less likely.

AGE

12 Years 10 Months

WEIGHT

12.8 pounds

INTERPRETED BY

Eric Lindquist, DMV,
DABVP(CFM), Cert.
IVUSS

IMAGING PERFORMED BY

Chloe Lowe CVT

HOSPITAL NAME

Blairstown Animal
Hospital

REFERRING VET

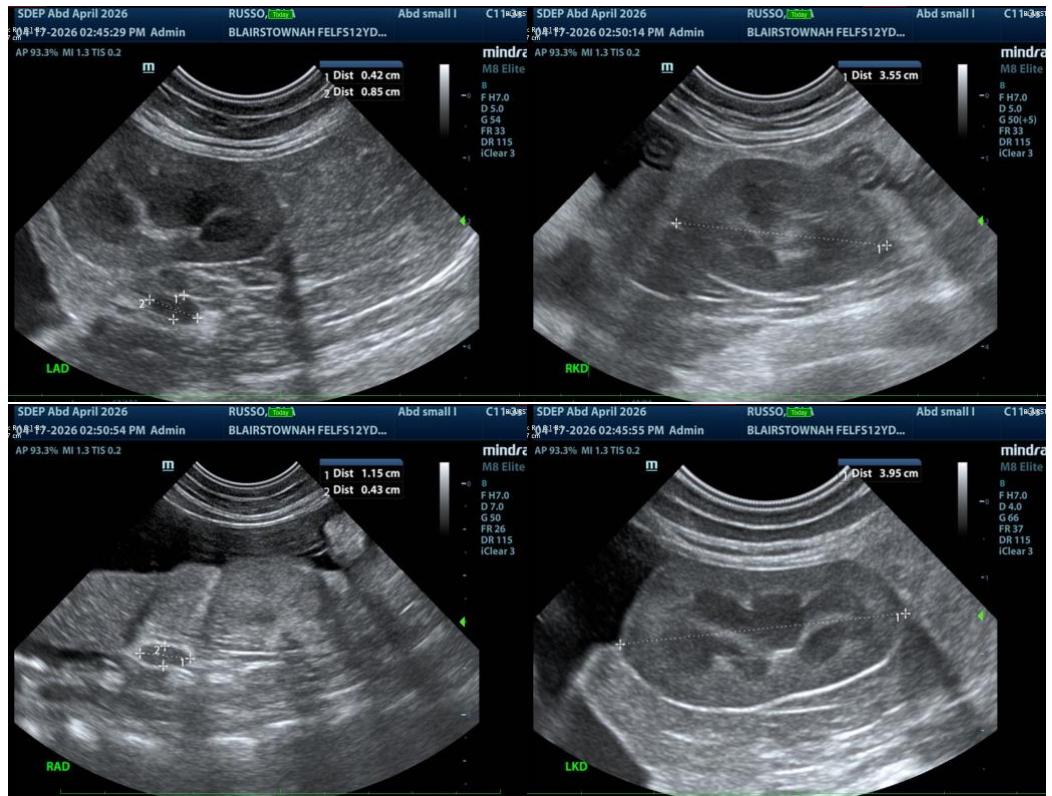
Dr. Clegg

INVOICE

15174

DATE

04/17/26





PATIENT

Lola Russo

SPECIES

Feline

BREED

DSH

SEX

Spayed Female

AGE

12 Years 10 Months

WEIGHT

12.8 pounds

INTERPRETED BY

Eric Lindquist, DMV,
 DABVP(CFM), Cert. IVUSS

IMAGING PERFORMED BY

Chloe Lowe CVT

HOSPITAL NAME

Blairstown Animal Hospital

REFERRING VET

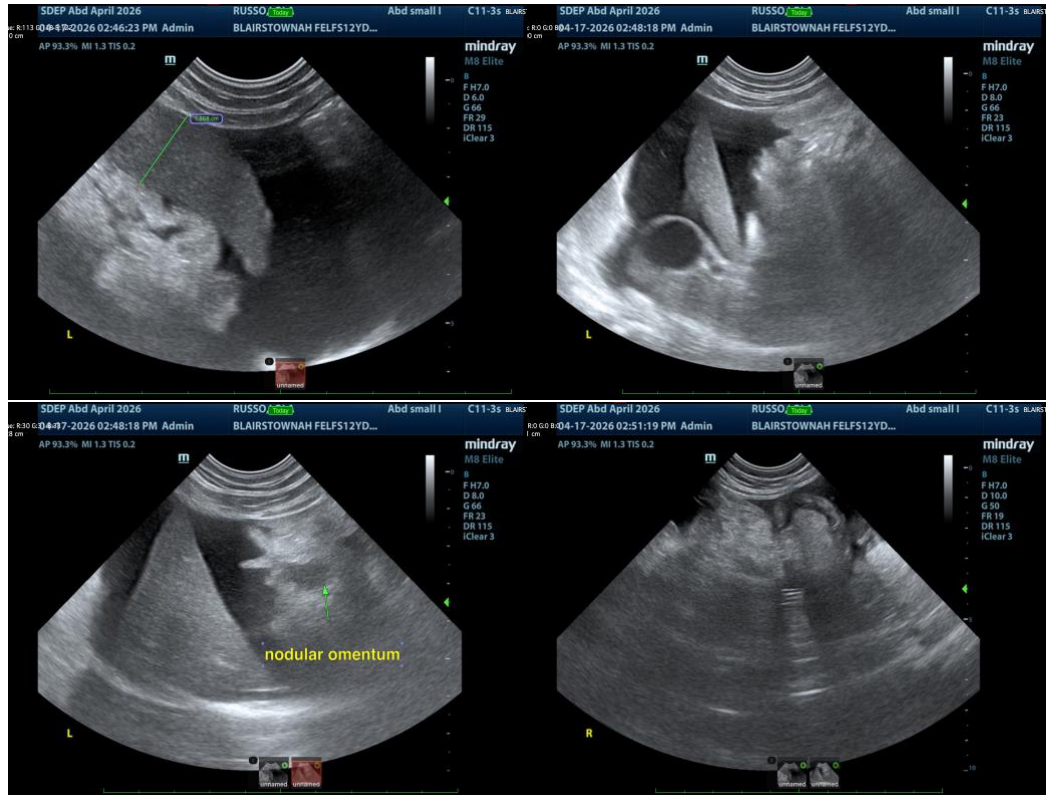
Dr. Clegg

INVOICE

15174

DATE

04/17/26



The information and recommendations provided are based on the images presented by the referring veterinarian/sonographer. No evaluation can be communicated regarding pathology that was not visible in the image/video clips provided.

Thank you for this referral. If the clinical or image interpretation does not parallel your findings or if I can be of any further assistance, please contact me.

Eric Lindquist, DMV, DABVP(CFM), Cert. IVUSS,

CEO, Owner, Founder -- SonoPath.com

info@SonoPath.com