



PATIENT

Rory Strauss

SPECIES

Canine

BREED

Cavalier King Charles
Spaniel

SEX

Neutered Male

AGE

2 Years

WEIGHT

16.5 Pounds

INTERPRETED BY

Eric Lindquist, DMV
DABVP, Cert. IVUSS

**IMAGING
PERFORMED BY**

Jessica Miller

HOSPITAL NAME

Companion AH,
Parsippany

REFERRING VET

Dr. Wolf

INVOICE

22019

DATE

4/17/23

PRESENTING CLINICAL SIGNS

History: Vomiting, diarrhea, possible foreign body

Abnormal PE/Chem/CBC/UA Results: Amylase 4858, PrecPSL 2667

ULTRASONOGRAPHIC EXAMINATION OF THE ABDOMEN

Urinary System

The **urinary bladder**, trigone, and pelvic urethra presented normal thicknesses and normal tone. The ureters were not visible which is normal. No uroliths or sediment were visualized and anechoic urine was present. No evidence of inflammatory or neoplastic changes were noted. Ureteral papillae were normal.

The **kidneys** revealed normal size and structure, corticomedullary definition and ratio for this age. The cortices presented largely uniform texture with normal echogenic relationship to liver and spleen. Medullary structure differed distinctly from the cortex and no evidence of pelvic dilation was present. The capsules were acceptably uniform without significant irregularities. The right kidney measured 4.0 cm. The left kidney measured 5.19 cm.

Adrenal Glands

Both **adrenal glands** were visualized and recognized as having normal shape, size, position and echogenicity for this breed. The phrenic vasculature, glandular echogenicity and detail were unremarkable. Capsule, cortex, and medullary definition were normal for this age patient. The left adrenal gland measured 2.09 cm x 0.25 cm at the caudal pole and 0.38 cm at the cranial pole. The right adrenal gland measured 1.96 cm x 1.26 cm at the cranial pole and 0.51 cm at the caudal pole.

Spleen

The **spleen** presented a smooth homogeneous parenchyma hyperechoic to liver and renal cortical parenchyma. The capsule was smooth without noticeable expansion or deviation from within the spleen or adjacent pathology. The splenic vasculature demonstrated normal volume without signs of congestion or thrombosis. No sonographic evidence of acute or chronic inflammatory, neoplastic, or infarctual changes were noted.

Liver

The **liver** images submitted revealed subjectively normal liver size, contour, and structure. Parenchymal echogenicity was naturally coarse and hypoechoic to the spleen. Vascular and biliary tracts were of normal volume with no evidence of congestion. The gallbladder presented acceptably thin walls with primarily anechoic content. The cystic and common bile ducts were normal. No pathological hepatic lymphadenopathy was evident. No overt structural evidence of inflammatory, infiltrative or regenerative pathology was evident.

Gastrointestinal

The **gastrointestinal tract** revealed approximately 2-3 cm of gastric fundic material, this may be ingesta, medications or possibly a small amount of foreign matter. Hypertrophied gastric wall and fluid filled gastric lumen were noted. The pylorus was patent without evidence of obstruction. The small intestine was empty; however, some minor reactive mesentery was noted, associated with the small intestine. The colon was empty as well.



PATIENT

Pancreas

Rory Strauss

The base and limbs of the **pancreas** were observed to be largely isoechoic to surrounding omental fat. Pancreatic duct and capsular contour were acceptably normal and parenchyma respected normal curvilinear patterns. No overt evidence of active inflammatory or neoplastic disease was noted.

SPECIES

Canine

ULTRASONOGRAPHIC FINDINGS

- Gastritis pattern with 3 cm of gastric fundic material, nonobstructive. This may be ingesta or soft foreign matter.

BREED

Cavalier King Charles Spaniel

INTERPRETATION OF THE FINDINGS & FURTHER RECOMMENDATIONS

Conservative therapy is recommended. Induction of vomiting could also be considered after canned feeding and follow up with ultrasound is recommended. I do not believe this is an immediate surgical issue at this time. Recheck sonogram in 2-4 days depending upon the patient response to medical management.

AGE

2 Years

WEIGHT

16.5 Pounds

INTERPRETED BY

Eric Lindquist, DMV DABVP, Cert. IVUSS

IMAGING PERFORMED BY

Jessica Miller

HOSPITAL NAME

Companion AH, Parsippany

REFERRING VET

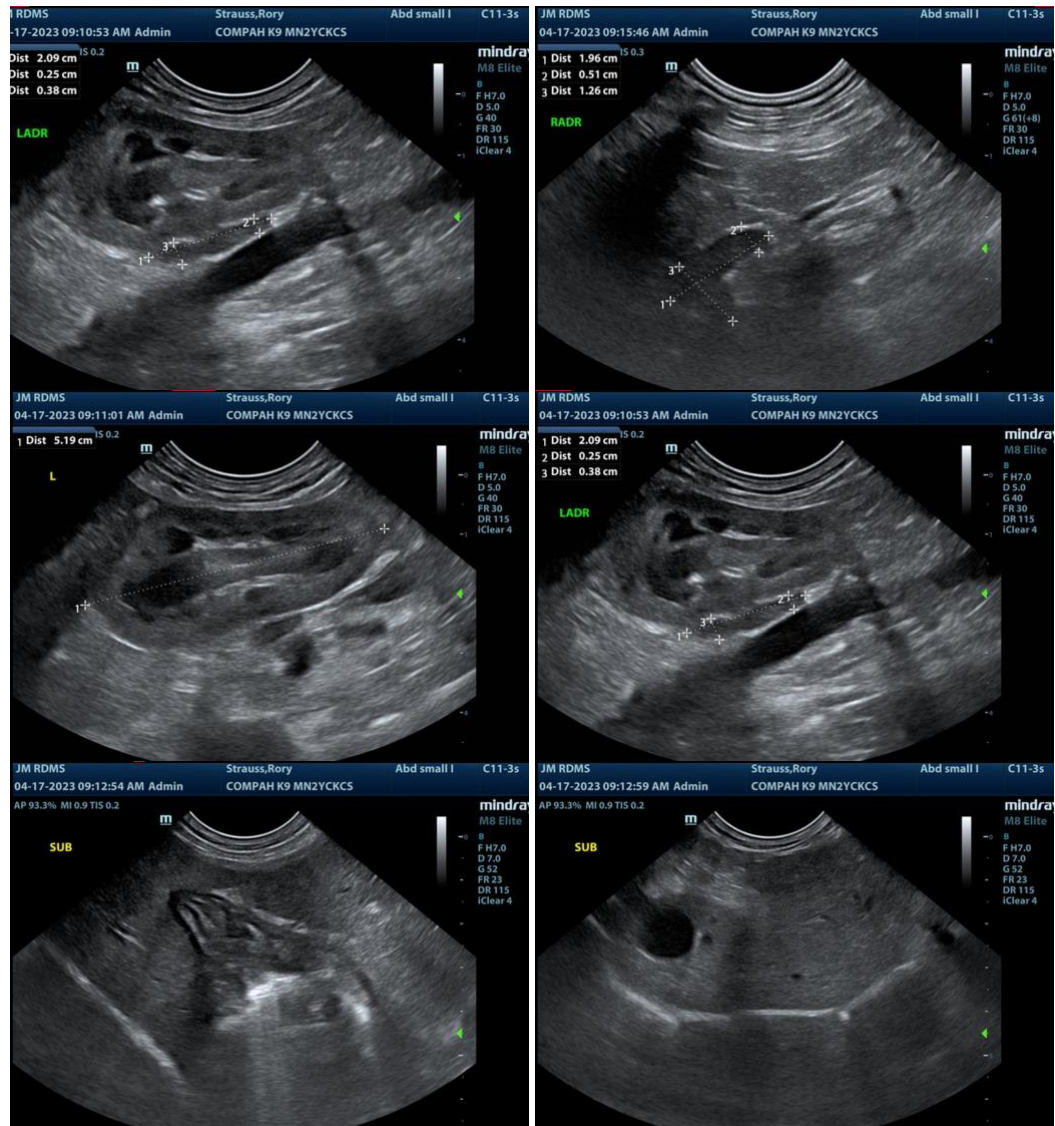
Dr. Wolf

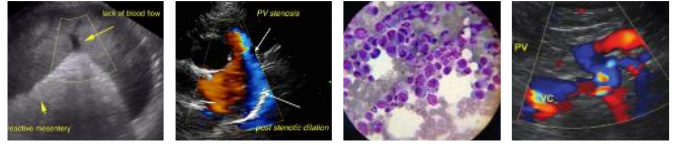
INVOICE

22019

DATE

4/17/23





PATIENT

Rory Strauss

SPECIES

Canine

BREED

Cavalier King Charles
Spaniel

SEX

Neutered Male

AGE

2 Years

WEIGHT

16.5 Pounds

INTERPRETED BY

Eric Lindquist, DMV
DABVP, Cert. IVUSS

**IMAGING
PERFORMED BY**

Jessica Miller

HOSPITAL NAME

Companion AH,
Parsippany

REFERRING VET

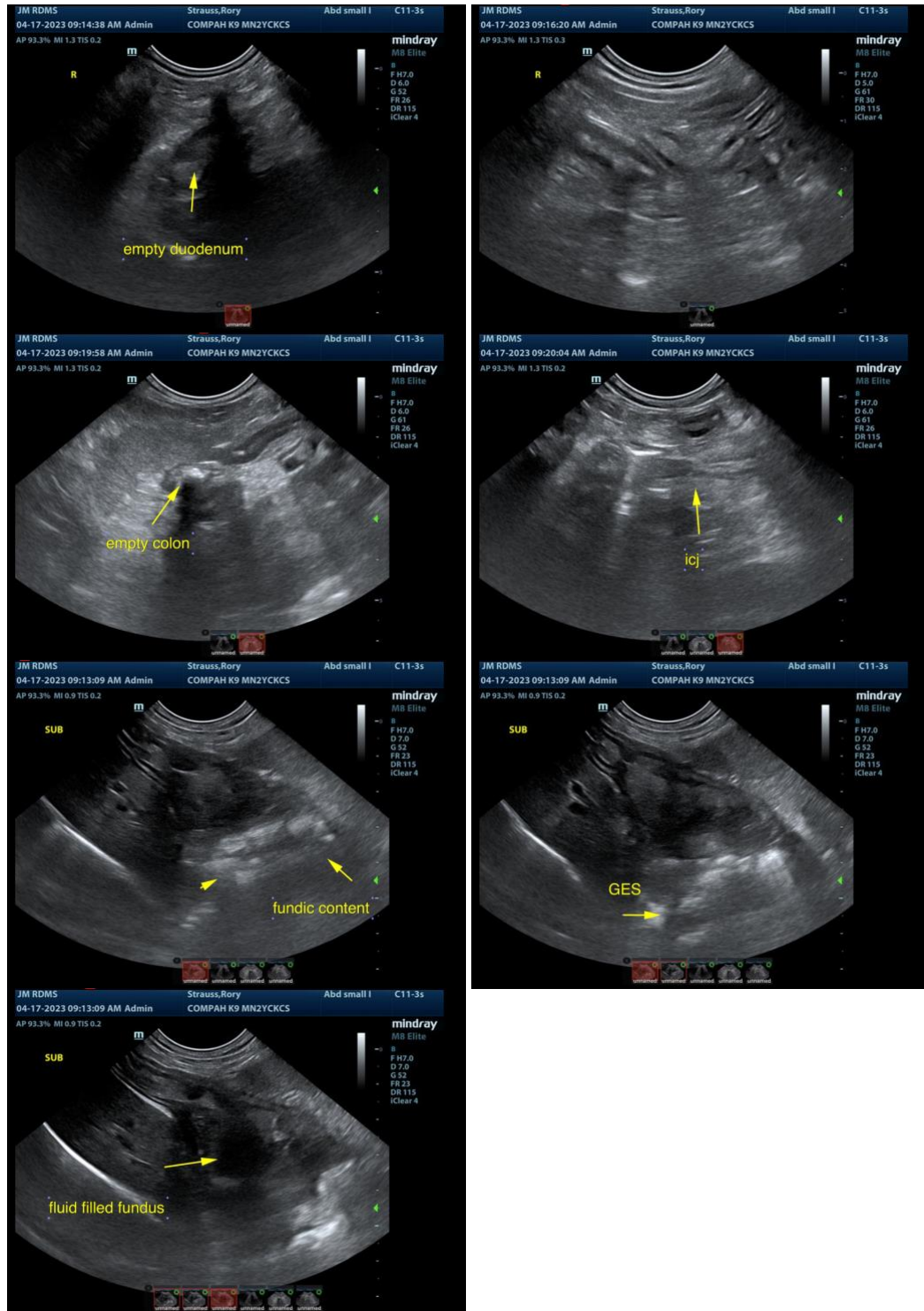
Dr. Wolf

INVOICE

22019

DATE

4/17/23



The information and recommendations provided are based on the images presented by the referring veterinarian. No evaluation can be communicated regarding pathology that was not visible in the image/video clips provided.

Thank you for this referral. If the clinical or image interpretation does not parallel your findings or if I



PATIENT

can be of any further assistance please contact me.

Rory Strauss

SPECIES

Canine

BREED

Cavalier King Charles
Spaniel

SEX

Neutered Male

AGE

2 Years

WEIGHT

16.5 Pounds

INTERPRETED BY

Eric Lindquist, DMV
DABVP, Cert. IVUSS

**IMAGING
PERFORMED BY**

Jessica Miller

HOSPITAL NAME

Companion AH,
Parsippany

REFERRING VET

Dr. Wolf

INVOICE

22019

DATE

4/17/23