



PATIENT

Kitty Hernandez

PRESENTING CLINICAL SIGNS

History: V/D

SPECIES

Canine

ULTRASONOGRAPHIC EXAMINATION OF THE ABDOMEN

BREED

Poodle

Urinary System

The **urinary bladder**, trigone, and pelvic urethra presented normal thicknesses and normal tone. The ureters were not visible which is normal. No uroliths or sediment were visualized and anechoic urine was present. No evidence of inflammatory or neoplastic changes were noted. Ureteral papillae were normal. The pelvic urethra was imaged 2.0 cm beyond the cystourethral junction.

SEX

Spayed Female

The **kidneys** revealed largely normal size and structure, corticomedullary definition and ratio (cortex 1/3 of medulla) were essentially maintained with some mild to moderate age-related loss of curvilinear patterns regarding the capsule and C/M junction. The cortices presented largely uniform texture with some increased echogenicity expected for his age patient. Medullary structure differed distinctly from that of the cortex and no evidence of pelvic dilation was present. The right kidney measured 4.7 cm. The left kidney measured 4.68 cm.

AGE

12

Adrenal Glands

The **left adrenal gland** was slightly irregular, measuring 1.64 cm x 1.15 cm at the cranial pole and 0.6 cm at the caudal pole.

WEIGHT

21

The **right adrenal gland** was visualized and recognized as having normal shape, size, position and echogenicity for this breed. The phrenic vasculature, glandular echogenicity and detail were unremarkable. Capsule, cortex, and medullary definition were normal for this age patient. The right adrenal gland measured 2.41 cm x 0.51 cm at the caudal pole and 0.75 cm at the cranial pole.

INTERPRETED BY

Eric Lindquist, DMV
DABVP, Cert. IVUSS

Spleen

The **spleen** presented a smooth homogeneous parenchyma hyperechoic to liver and renal cortical parenchyma. The capsule was smooth without noticeable expansion or deviation from within the spleen or adjacent pathology. The splenic vasculature demonstrated normal volume without signs of congestion or thrombosis. No sonographic evidence of acute or chronic inflammatory, neoplastic, or infarctual changes were noted.

IMAGING PERFORMED BY

Jenn

HOSPITAL NAME

Rockaway AH

Liver

The **liver** itself was unremarkable. The gallbladder was overdistended with peripheral inflammation and striating bile, consistent with inflamed mucocele. The common bile duct appeared to be dilated yet somewhat obscured by regional inflammation.

REFERRING VET

Dr. Bednar

Gastrointestinal

The **stomach** revealed a minor amount of fluid filled lumen. Hypertrophied gastric wall was noted without loss of mural detail. Enhanced mesentery was noted around the stomach with hyperperistalsis. The small intestine and colon were unremarkable.

INVOICE

22031

Pancreas

DATE

4/17/23



PATIENT

Kitty Hernandez

The base and limbs of the **pancreas** were observed to be largely isoechoic to surrounding omental fat. Pancreatic duct and capsular contour were acceptably normal and parenchyma respected normal curvilinear patterns. No overt evidence of active inflammatory or neoplastic disease was noted.

SPECIES

Canine

ULTRASONOGRAPHIC FINDINGS

- Inflamed gallbladder mucocele- This is a surgical emergency.
- Irregular left adrenal gland- hyperplasia vs emerging carcinoma or pheochromocytoma
- Hypertrophied gastric wall, enhanced mesentery around the stomach and hyperperistalsis
- Age-related renal changes

BREED

Poodle

INTERPRETATION OF THE FINDINGS & FURTHER RECOMMENDATIONS

SEX

Immediate cholecystectomy and common bile duct lavage are indicated. Prognosis is guarded.

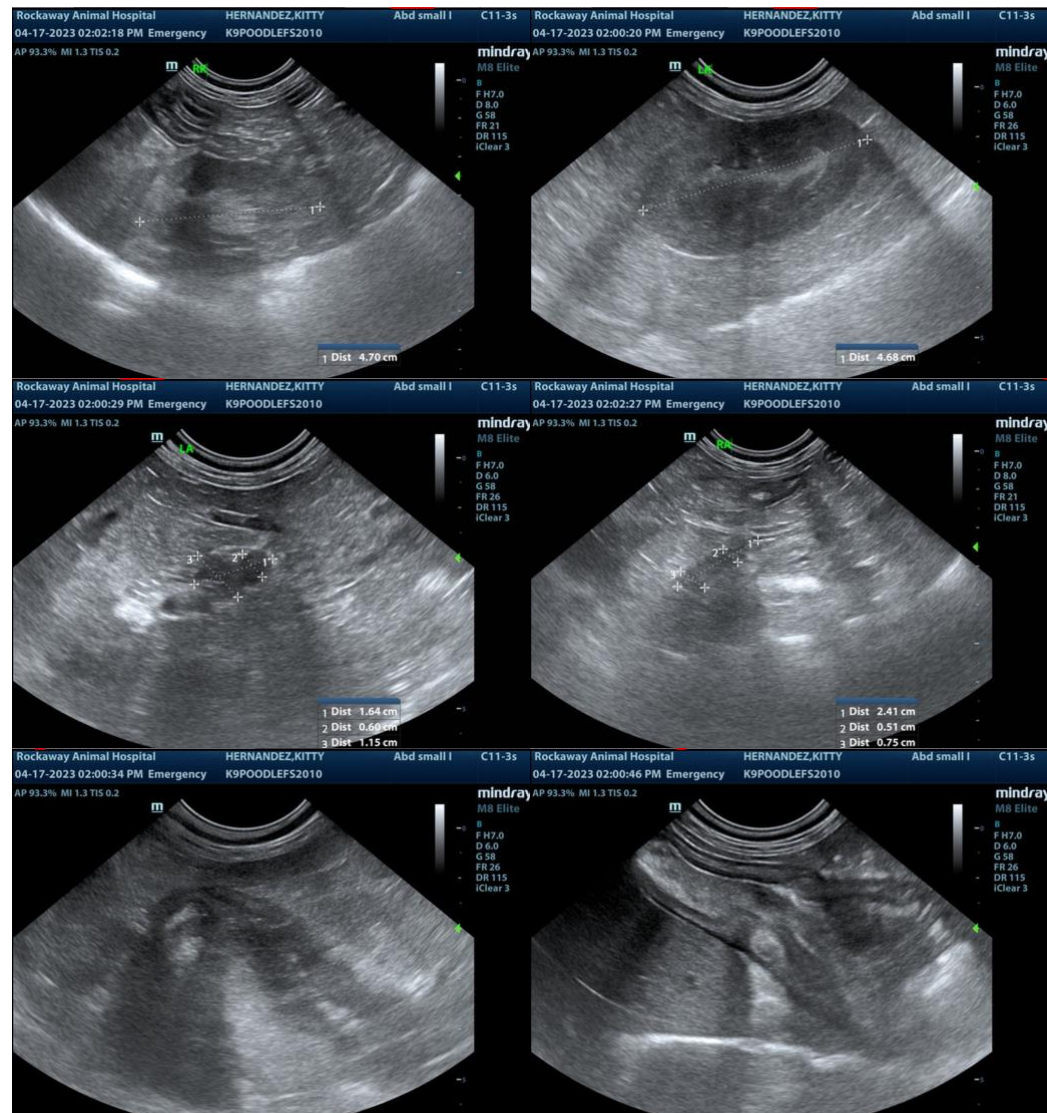
Spayed Female

AGE

12

WEIGHT

21



INTERPRETED BY

Eric Lindquist, DMV
DABVP, Cert. IVUSS

IMAGING PERFORMED BY

Jenn

HOSPITAL NAME

Rockaway AH

REFERRING VET

Dr. Bednar

INVOICE

22031

DATE

4/17/23



PATIENT

Kitty Hernandez

SPECIES

Canine

BREED

Poodle

SEX

Spayed Female

AGE

12

WEIGHT

21

INTERPRETED BY

Eric Lindquist, DMV
DABVP, Cert. IVUSS

IMAGING PERFORMED BY

Jenn

HOSPITAL NAME

Rockaway AH

REFERRING VET

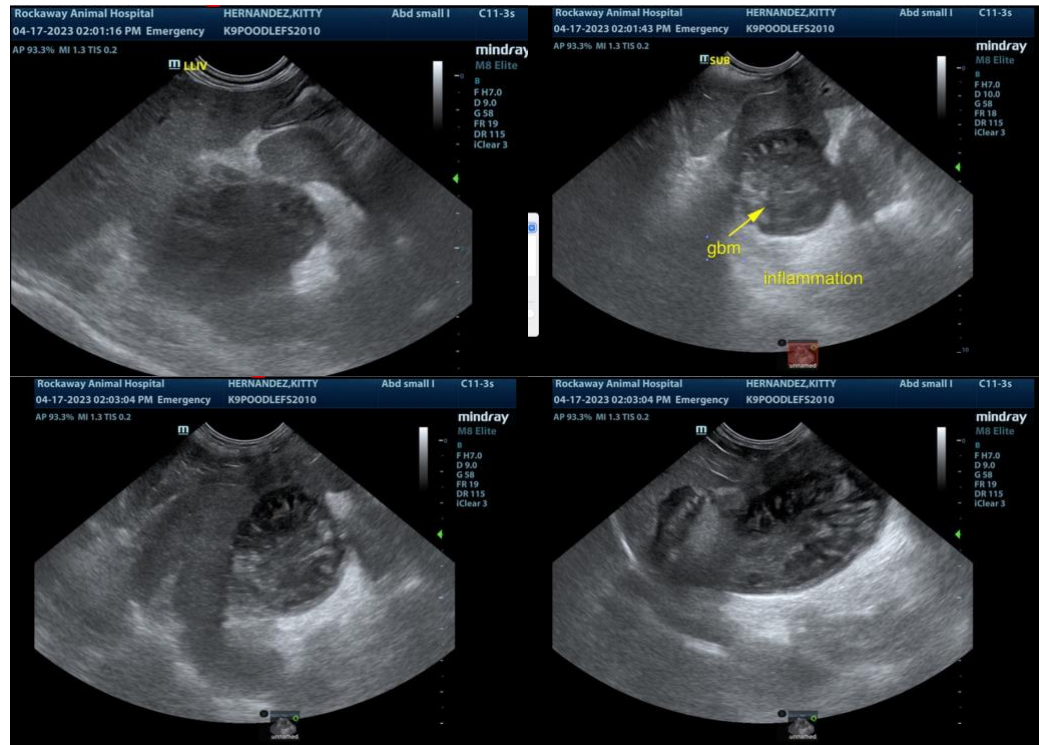
Dr. Bednar

INVOICE

22031

DATE

4/17/23



The information and recommendations provided are based on the images presented by the referring veterinarian. No evaluation can be communicated regarding pathology that was not visible in the image/video clips provided.

Thank you for this referral. If the clinical or image interpretation does not parallel your findings or if I can be of any further assistance please contact me.

Eric Lindquist, DMV, DABVP, Cert. IVUSS, CEO of SonoPath.com
info@SonoPath.com

Gallbladder Mucoceles

<http://www.sonopath.com/GBMucocele>

<http://www.sonopath.com/GBMucoceleSurvey>

<http://www.sonopath.com/SxBiliaryDisease>

Description: A gallbladder mucocele occurs when the gallbladder becomes overly distended with an excessive accumulation of mucus secondary to cystic mucosal hyperplasia. Previously, pathologists noted this finding at necropsy and considered it an incidental or age-related lesion. In



PATIENT

Kitty Hernandez

SPECIES

Canine

BREED

Poodle

SEX

Spayed Female

AGE

12

WEIGHT

21

INTERPRETED BY

Eric Lindquist, DMV
DABVP, Cert. IVUSS

IMAGING PERFORMED BY

Jenn

HOSPITAL NAME

Rockaway AH

REFERRING VET

Dr. Bednar

INVOICE

22031

DATE

4/17/23

the last decade, however, it has become evident that not all gallbladder mucoceles remain clinically silent and that they can in fact be associated with extrahepatic bile duct obstruction (EHBDO), cholecystitis, and gallbladder wall rupture. Approximately 50% of mucoceles may result in necrosis and rupture, typically at the neck or fundic region of the gallbladder. The etiology of these mucoceles remains unknown, but researchers suspect that it is related to disordered cholestasis and/or lipid metabolism. Suggested causes include: primary or secondary gallbladder motility disorder; dyslipidemia/hypercholesterolemia; extrahepatic bile duct obstruction; and primary or secondary disorders of mucus-producing cells, such as cystic mucosal hyperplasia of the gallbladder wall. Clinical correlation is also seen with cholangitis, cholecystitis, cholelithiasis, biliary obstruction from cholelithiasis or neoplasia, and pancreatitis. Abnormal adrenal hormones may also play a causal role in altering gallbladder mucus secretion. Hypothyroid dogs are three times more likely to develop a mucocele, and Cushinoid dogs are twenty-nine times more likely to do so. Vacuolar hepatopathy frequently co-occurs with mucoceles; practitioners are therefore advised to investigate underlying disorders associated with vacuolar hepatopathy. Bacterial infection of the gallbladder has been associated with increased mucin production in dogs; this condition may also become pathological and lead to excessive mucus accumulation. In humans, hypercortisolism is related to chronic cholecystitis and changes the biochemical composition of bile. The latter, however, was not substantiated by two studies evaluating bile composition, bacterial infection, and sludge formation during a three-month period of exogenous administration of hydrocortisone administration in dogs. There is a marked increase in the prevalence of mucocele formation in dogs with naturally occurring hyperadrenocorticism, but a definitive correlational mechanism has yet not been ascertained.

Mucoceles are most commonly seen in middle-aged to older dogs (median age of 10 years); however, researchers have reported mucocele development in dogs as young as 3 years old. Certain breeds—Miniature Schnauzers, Shetland Sheepdogs, Cocker Spaniels, Shih-tzus, Pugs, Bichon Frisés, Schipperkes, West Highland White Terriers, and Scottish Terriers—appear to be overrepresented among canine patients. Significant predisposition to mucocele formation in Shelties prompted an investigation that uncovered a specific genetic mutation in the ABCB4 gene, which functions in the translocation of phosphatidylcholine across hepatocyte cell membranes. In the future, we may be able to screen young Shelties for this mutation, which would allow us to monitor gallbladder mucocele development with ultrasound over time and thereby offer early dietary and medical management, or even surgical intervention as needed. Felines are less commonly affected.

Clinical Signs: According to several retrospective studies, the most common clinical signs include vomiting (87%), abdominal pain (87%), anorexia (78%), lethargy, icterus (57%), and fever (26%). The average duration of illness is 5 days. Focal pain upon examining the gallbladder is common and referred to as a positive Murphy sign. Patients may also be asymptomatic, despite biochemical abnormalities, even in the face of ultrasonographic evidence of a mucocele. Patients with fully formed mucoceles are at risk of further complications, such as gallbladder rupture, peritonitis, sepsis, and related coagulopathies, and should be considered for surgical intervention.

Diagnostics: Biochemical analyses may indicate leukocytosis, with or without a left shift, and most commonly reveal elevated hepatic enzymes (SAP 100%, GGT 86%, ALT 77%, AST 60%) and bilirubin (63%). Ultrasonographic findings may include: a distended gallbladder with centrally suspended luminal content and a hypochoic intraluminal rim; a thickened gallbladder wall;



PATIENT

Kitty Hernandez

SPECIES

Canine

BREED

Poodle

SEX

Spayed Female

AGE

12

WEIGHT

21

INTERPRETED BY

Eric Lindquist, DMV
DABVP, Cert. IVUSS

IMAGING PERFORMED BY

Jenn

HOSPITAL NAME

Rockaway AH

REFERRING VET

Dr. Bednar

INVOICE

22031

DATE

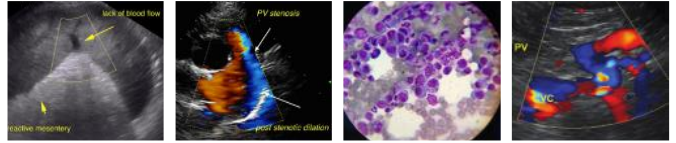
4/17/23

intraluminal stellate; echogenic striations (the “kiwi fruit sign”); and/or the presence of non-dependent intraluminal contents or sludge. (Note: The presence of the “kiwi fruit sign” is not essential for the diagnosis of a gall bladder mucocele, as many mucocele variations do not demonstrate a complete stellate pattern.) A hypochoic ring seen around the gallbladder may indicate wall edema or early rupture. Presence of free fluid, as well as localized, echogenic hepatic parenchyma and intra-abdominal fat, are also consistent with bile leakage and peritonitis. Pain is often noted upon interrogation of the area. Dilation of the common bile duct may also be present.

Since there exists an association between hypercholesterolemia/hyperlipidemia and gallbladder mucoceles, patients that exhibit both should be screened for hypothyroidism, adrenal hyperplasia syndromes (Cushing’s disease and sex hormone dysregulation), diabetes mellitus, pancreatitis, exogenous exposure to glucocorticoids, and necroinflammatory liver disease.

Treatment: Surgical intervention is recommended due to the significant risk of peritonitis and sepsis associated with rupture, and since medical management on its own may not be effective. Candidates for surgery must be adequately stabilized prior to surgery, and a coagulation panel should be assessed beforehand. Use of ursodeoxycholic acid (Actigall) is not recommended if any sonographic aspects of wall inflammation or emergent perforation are present. Percutaneous centesis of the gallbladder is also not advised in the presence of a mucocele. Some studies that have investigated a relatively small number of dogs have found medical therapy with Actigall and SAME to be somewhat effective at a very early subclinical stage. Yet, there are no definitive guidelines for ascertaining whether certain sonographic or laboratory findings permit the differentiation of a clinically significant mucocele versus a non-clinical, stable mucocele that may become clinically significant in the future. For this reason, each patient must be assessed individually. It may be the case that very dramatic mucoceles do not cause any overt clinical signs, whereas other patients may have minor mucoceles that lead to significant clinical signs and necessitate urgent cholecystectomy to avoid the onset of bile peritonitis due to rupture. It is generally advised that dogs with clinical signs, elevated liver enzymes, elevated WBC counts, and sonographic evidence of a mucocele be treated surgically. However, if a clinically silent mucocele is found incidentally on ultrasound, careful observation and monitoring is reasonable, provided there are no underlying diseases that may promote degradation (e.g., hyperadrenocorticism). Owners should be instructed to carefully monitor their pets for the development of clinical signs that may signal progression of the disease.

Antibiotic therapy directed towards gram-negative, enteric bacteria (i.e., *E. coli*, *Klebsiella*, *Enterobacter*, etc.) and anaerobic bacteria is indicated, and will likely be necessary for several weeks following surgery. Culture and sensitivity results should guide long-term treatment. Cholecystectomy with a possible bile duct transposition is the procedure of choice. The bile duct is often flushed to remove sludge and debris to help avoid post-surgical obstruction. Cholecystotomy for removing gallbladder contents is not advised as studies have shown that mucocele concretions have reformed in several dogs treated in this manner. At the time of surgery, one should obtain liver biopsies as well as submit cultures and sensitivity of the gallbladder contents. Liver biopsies may show normal tissue, cholangiohepatitis, biliary hyperplasia, vacuolar hepatopathy, or mild to moderate portal hepatitis/fibrosis with bile duct proliferation. Ultrasound-guided cholecystocentesis is not recommended in dogs with mature mucoceles due to the risk of gallbladder rupture and seeding the abdomen with bacteria. Rupture of the gallbladder constitutes a surgical emergency and carries a worse prognosis for survival. Several investigators have noted that, upon



PATIENT

Kitty Hernandez

surgical exploration of asymptomatic mucocele patients, there is evidence of prior localized peritonitis and fibrosis, likely resulting from tears in the gallbladder's neck, which lead to minute amounts of bile leakage.

SPECIES

Canine

Conclusion: Possible etiological explanations for gallbladder mucoceles are quite varied, and underlying diseases must be treated. The treatment of choice is cholecystectomy, with surgical intervention especially recommended for patients with clinical signs or significantly elevated liver enzymes so as to avoid gallbladder rupture and subsequent peritonitis.

BREED

Poodle

References:

SEX

Spayed Female

Aguirre AL, Center SA, Randolph JF, et al. Gallbladder disease in Shetland Sheepdogs: 38 cases (1995-2005). *J Am Vet Med Assoc* 2007;231(1):79-88.

AGE

12

Besso JG, Wrigley RH, Gliatto JM, Webster CR. Ultrasonographic appearance and clinical findings in 14 dogs with gallbladder mucocele. *Vet Radiol Ultrasound* 2000;41(3):261-71.

WEIGHT

21

Cornejo L, Webster CRL. Canine gallbladder mucoceles. *Compend Contin Educ Vet* 2005;27:912-30.

INTERPRETED BY

Eric Lindquist, DMV
DABVP, Cert. IVUSS

Crews LJ, Feeney DA, Jessen CR, et al. Clinical, ultrasonographic, and laboratory findings associated with gallbladder disease and rupture in dogs: 45 cases (1997-2007). *J Am Vet Med Assoc* 2009;234(3):359-66.

IMAGING PERFORMED BY

Jenn

Kook PH, Schellenberg S, Grest P, et al. Microbiologic evaluation of gallbladder bile of healthy dogs and dogs with iatrogenic hypercortisolism: a pilot study. *J Vet Intern Med* 2010;24(1):224-28.

HOSPITAL NAME

Rockaway AH

Kook PH, Schellenberg S, Rentsch KM, et al. Effects of iatrogenic hypercortisolism on gallbladder sludge formation and biochemical bile constituents in dogs. *Vet J* 2012;191(2):225-30.

REFERRING VET

Dr. Bednar

Malek S, Sinclair E, Hosgood G, et al. Clinical findings and prognostic factors for dogs undergoing cholecystectomy for gallbladder mucocele. *Vet Surg* 2013;42(4):418-26.

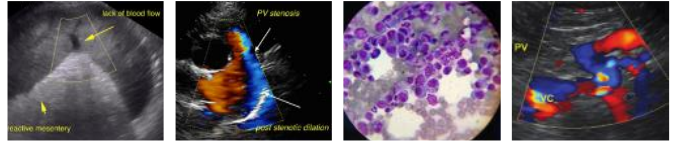
INVOICE

22031

Mealey KL, Minch JD, White SN, et al. An insertion mutation in ABCB4 is associated with gallbladder mucocele formation in dogs. *Comp Hepatol* 2010;9:6.

DATE

4/17/23



PATIENT

Kitty Hernandez

Mehler SJ, Bennett RA. Canine Extrahepatic Biliary Tract Disease and Surgery. *Compend Contin Educ Vet* 2006;28(4):302-15.

SPECIES

Canine

Pike FS, Berg J, King NW, et al. Gallbladder mucocele in dogs: 30 cases (2000-2002). *J Am Vet Med Assoc* 2004;224(10):1615-22.

BREED

Poodle

Walter R, Dunn ME, d'Anjou MA, L'Écuyer M. Nonsurgical resolution of gallbladder mucocele in two dogs. *J Am Vet Med Assoc* 2008;232(11):1688-93.

SEX

Spayed Female

Worley DR, Hottinger HA, Lawrence HJ. Surgical management of gallbladder mucocoeles in dogs: 22 cases (1999-2003). *J Am Vet Med Assoc* 2004;225(9):1418-22.

AGE

12

WEIGHT

21

INTERPRETED BY

Eric Lindquist, DMV
DABVP, Cert. IVUSS

**IMAGING
PERFORMED BY**

Jenn

HOSPITAL NAME

Rockaway AH

REFERRING VET

Dr. Bednar

INVOICE

22031

DATE

4/17/23