



PATIENT

Jorge Smebakken

SPECIES

Canine

BREED

Mixed

SEX

Neutered Male

AGE

6 Years 7 Months

WEIGHT

8.8 Pounds

PRESENTING CLINICAL SIGNS

History: E/D- normal V/D,C/S,L/B-none Meds-none Concerns- holds up RH leg, has since O adopted him a few years ago PE: significant (5-6/6) systolic murmur, severe dental disease, bilateral patellar luxation

ULTRASONOGRAPHIC EXAMINATION OF THE HEART

CANINE CARDIAC PARAMETERS	MR VMAX (m/s)	TR VMAX (m/s)	LA/AO (Boon method)	LA/AO (Heart Base; Swe)	FS (%)	EF (%)	EPSS (cm)
NORMAL PARAMETER	4.5-5.5	<2.7	1.3	<1.3	28-40	40-100	<0.6
PATIENT	--	--	NM	1.3	--	--	NM
CANINE CARDIAC PARAMETERS	HR (BPM)	AV VMAX (m/s)	PV MAX (m/s)	BODY WEIGHT (kg)	LA 2D short axis Base view (cm)	LVIDd Avg; 2D and m-mode short axis (cm)	LVIDs Avg; 2D and m-mode short axis (cm)
NORMAL PARAMETER	50-100	0.7-1.7	0.7-1.6				
PATIENT	--	--	--	--	2.2	2.4	--

INTERPRETED BY

Eric Lindquist, DMV
DABVP, Cert. IVUSS

IMAGING PERFORMED BY

Dr. Jessie Evoniuk

HOSPITAL NAME

State Avenue VC

REFERRING VET

Dr. Jessie Evoniuk

INVOICE

22027

DATE

4/17/23

Cardiac Presentation

The echocardiogram in this patient demonstrated normal **left atrial** size based on 3 different LA measurement methods. Prolapse of the anterior mitral valve leaflet was noted. Doppler indicated measurable insufficiency. The **left ventricle** presented thicknesses with linear contour and was not dilated nor restricted. The **myocardium** presented normal echogenicity without subjective evidence of significant fibrotic or ischemic disease. **Contractility** of the ventricular walls was adequate and in normal range for this patient evidenced by the fractional shortening measurement and subjective evaluation of the different regions of the myocardium. The **left ventricular outflow tract** demonstrated normal laminar flow and subjective structural integrity. The **right atrium** and auricle revealed normal size, structure and content. No evidence of masses was noted or chamber overload. **Tricuspid** valvular assessment demonstrated adequate linear morphology. The **right ventricle** was of normal size (1/3 diameter of LV), chordae structure, myocardial echogenicity and thickness. **Pulmonic** tract assessment revealed normal valve structure, laminar flow, and diameter (approx.1:1 pa/ao ratio). No visible **pericardial** or free pleura fluid was noted. No echographically detectable evidence of infiltrative disease was visible. The cranial **mediastinum and pericardial regions** were free of masses in the visible window.

ULTRASONOGRAPHIC FINDINGS

- Mitral insufficiency
- Stage b-1 valvular disease
- No evidence of volume overload



PATIENT

Jorge Smebakken

SPECIES

Canine

BREED

Mixed

SEX

Neutered Male

AGE

6 Years 7 Months

WEIGHT

8.8 Pounds

INTERPRETED BY

Eric Lindquist, DMV
DABVP, Cert. IVUSS

IMAGING PERFORMED BY

Dr. Jessie Evoniuk

HOSPITAL NAME

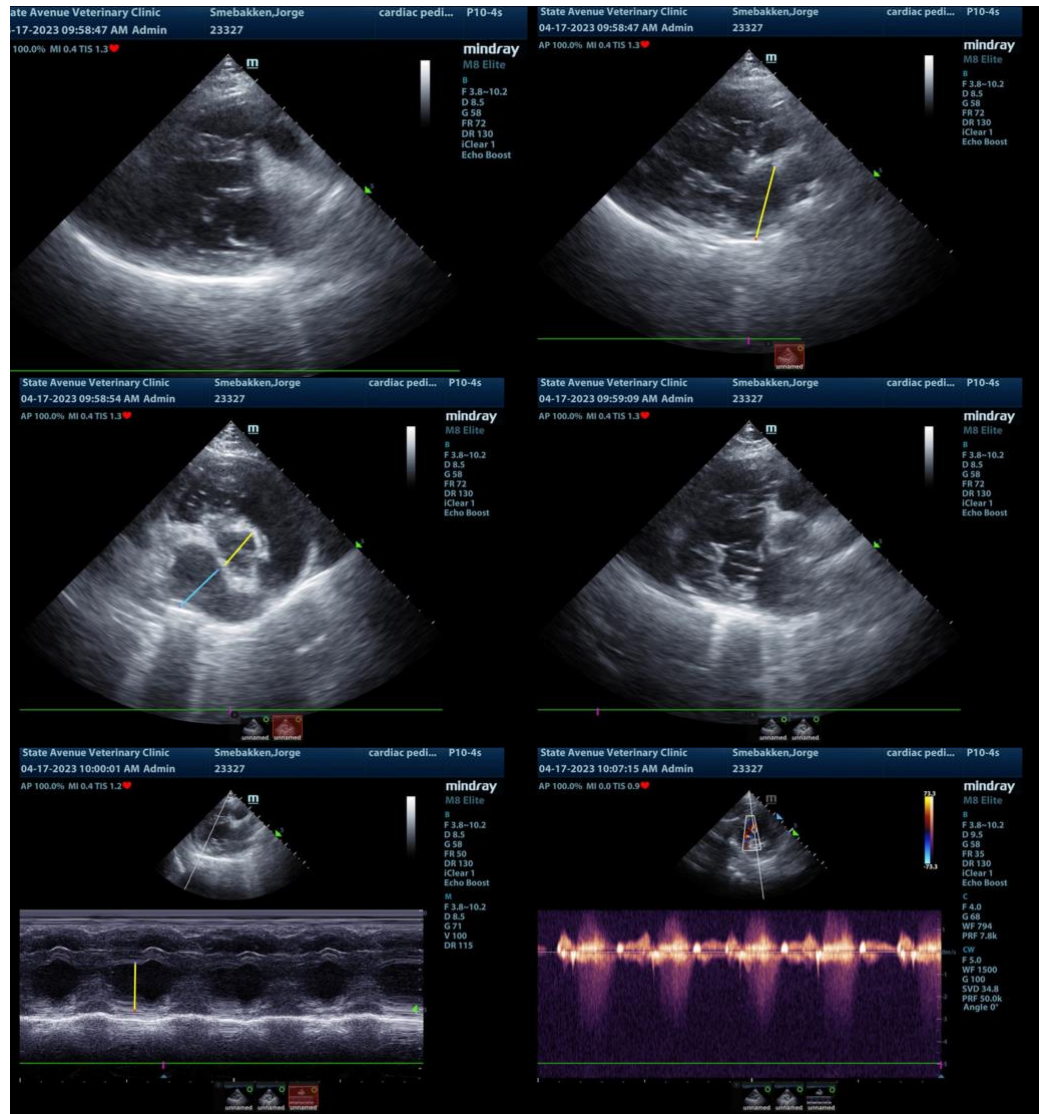
State Avenue VC

REFERRING VET

Dr. Jessie Evoniuk

INTERPRETATION OF THE FINDINGS & FURTHER RECOMMENDATIONS

The patient should not have any overt clinical signs related to cardiac disease at this time. The heart is stable without clinical disease. No overt contraindication for anesthesia of brief to moderate duration. I suggest Torbutrol premed, Propofol induction, Isoflor maintenance or similar protocol if anesthesia is desired. Blood pressure recommended if not already performed and target white coat negative systolic pressure of < 160 mmHg. If higher than this ACE-inhibitor is suggested to reach this level. Recheck echocardiogram is recommended in 6 months, earlier if murmur grade increases or clinical signs initiate.



INVOICE

22027

DATE

4/17/23

The information and recommendations provided are based on the images presented by the referring veterinarian. No evaluation can be communicated regarding pathology that was not visible in the image/video clips provided.

Thank you for this referral. If the clinical or image interpretation does not parallel your findings or if I can be of any further assistance please contact me.



PATIENT

Jorge Smebakken

Eric Lindquist, DMV, DABVP, Cert. IVUSS, CEO of SonoPath.com
info@SonoPath.com

SPECIES

Canine

BREED

Mixed

SEX

Neutered Male

AGE

6 Years 7 Months

WEIGHT

8.8 Pounds

INTERPRETED BY

Eric Lindquist, DMV
DABVP, Cert. IVUSS

**IMAGING
PERFORMED BY**

Dr. Jessie Evoniuk

HOSPITAL NAME

State Avenue VC

REFERRING VET

Dr. Jessie Evoniuk

INVOICE

22027

DATE

4/17/23