



**PATIENT**

Tasha Picinic

**SPECIES**

Canine

**BREED**

Havanese

**SEX**

Spayed Female

**AGE**

13 Years 11 Months

**WEIGHT**

15.7 pounds

**INTERPRETED BY**

Eric Lindquist, DMV,  
 DABVP(CFM), Cert.  
 IVUSS

**IMAGING PERFORMED BY**

Kerri Becker

**HOSPITAL NAME**

Legacy Animal Hospital

**REFERRING VET**

Dr. Potenzzone

**INVOICE**

15158

**DATE**

04/16/26

**PRESENTING CLINICAL SIGNS**

Last echo 9/16/25 recheck heart dz

meds- pimo, denamarin, benaz, clop, spiron, Lasix

Abnormal PE/Chem/CBC/UA Results: sdma-19 bun-74 alp-252 lipase-1694

**ULTRASONOGRAPHIC EXAMINATION OF THE HEART**

CANINE CARDIAC PARAMETERS	MR VMAX (m/s)	TR VMAX (m/s)	LA/AO (M-Mode)	LA/AO (Heart Base; Swe)	FS (%)	EF (%)	EPSS (cm)
NORMAL PARAMETER	4.5-5.5	<2.7	1.3	Up to 1.6	28-40	40-100	<0.6
PATIENT	6.0		NM	2.0			0.3
CANINE CARDIAC PARAMETERS	HR (BPM)	AV VMAX (m/s)	PV MAX (m/s)	BODY WEIGHT (kg)	LAD LA MAX 4 Chamber	LVIDd Avg; 2D and m-mode short axis (cm)	LVIDs Avg; 2D and m-mode short axis (cm)
NORMAL PARAMETER	50-100	0.7-1.7	0.7-1.6				
PATIENT	160	1.3	0.9	15.7	5.5		

**Cardiac Presentation**

Rapid echocardiogram was performed owing to the precarious nature of the patient's disease. Arrhythmogenic activity was noted. Mitral and tricuspid insufficiency was present with moderate left atrial enlargement. Volume overload of the left atrium and left ventricle was present. Contractility was not quite compensatory. The mitral insufficiency was severe with prolapse of the anterior mitral valve leaflet. Aortic valve insufficiency was also present. The left ventricular outflow velocity was normal. The right heart was slightly prominent with mild right atrial enlargement. Mild hepatic vein dilation was present.

**ULTRASONOGRAPHIC FINDINGS**

- Partially compensated valvular disease.

**INTERPRETATION OF THE FINDINGS & FURTHER RECOMMENDATIONS**

Recommend increasing Lasix by 1.0 mg/kg BID. Management of cough with Hycodan if present. Primary respiratory disease may also be playing a role. Prognosis is extremely guarded.



**PATIENT**

Tasha Picinic

**SPECIES**

Canine

**BREED**

Havanese

**SEX**

Spayed Female

**AGE**

13 Years 11 Months

**WEIGHT**

15.7 pounds

**INTERPRETED BY**

Eric Lindquist, DMV,  
 DABVP(CFM), Cert.  
 IVUSS

**IMAGING PERFORMED BY**

Kerri Becker

**HOSPITAL NAME**

Legacy Animal Hospital

**REFERRING VET**

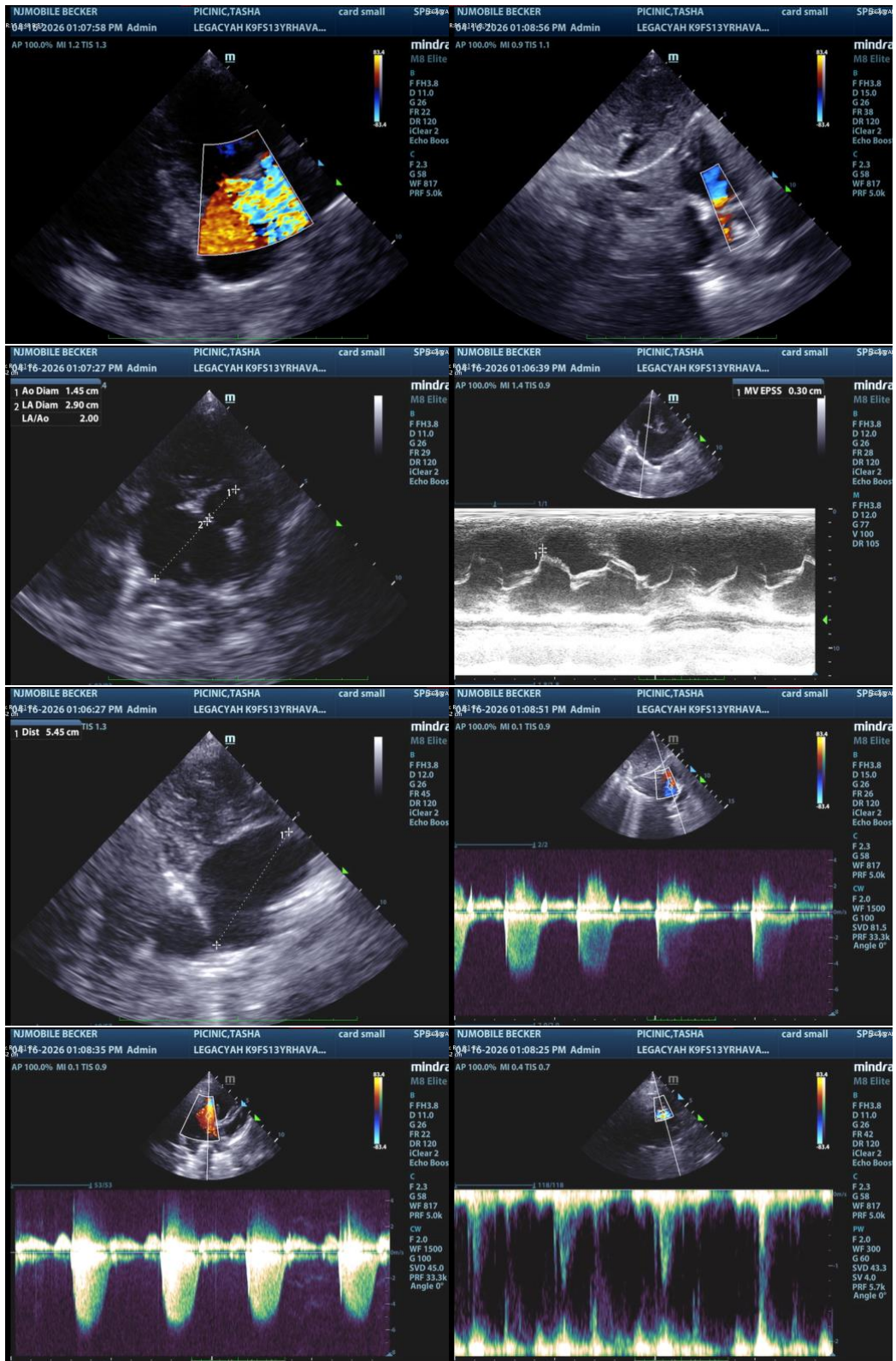
Dr. Potenzzone

**INVOICE**

15158

**DATE**

04/16/26





**PATIENT**

Tasha Picinic

**SPECIES**

Canine

**BREED**

Havanese

**SEX**

Spayed Female

**AGE**

13 Years 11 Months

**WEIGHT**

15.7 pounds

**INTERPRETED BY**

Eric Lindquist, DMV,  
 DABVP(CFM), Cert.  
 IVUSS

**IMAGING PERFORMED BY**

Kerri Becker

**HOSPITAL NAME**

Legacy Animal Hospital

**REFERRING VET**

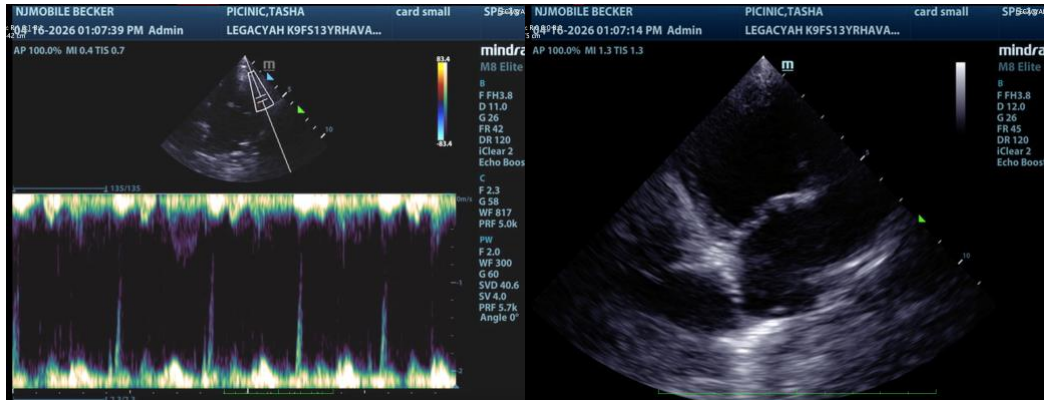
Dr. Potenzzone

**INVOICE**

15158

**DATE**

04/16/26



The information and recommendations provided are based on the images presented by the referring veterinarian/sonographer. No evaluation can be communicated regarding pathology that was not visible in the image/video clips provided.

Thank you for this referral. If the clinical or image interpretation does not parallel your findings or if I can be of any further assistance, please contact me.

**Eric Lindquist, DMV, DABVP(CFM), Cert. IVUSS,**

CEO, Owner, Founder -- SonoPath.com

[info@SonoPath.com](mailto:info@SonoPath.com)