



**PATIENT**

Romeo Patel

**SPECIES**

Canine

**BREED**

Toy Poodle

**SEX**

Male

**AGE**

13 Years 3 Months

**WEIGHT**

5.3 kg

**INTERPRETED BY**

Eric Lindquist, DMV,  
DABVP(CFM), Cert.  
IVUSS

**IMAGING PERFORMED BY**

Vincent Ravancho CVT

**HOSPITAL NAME**

Banfield Bridgewater

**REFERRING VET**

Dr. Sousa

**INVOICE**

15161

**DATE**

04/16/26

**PRESENTING CLINICAL SIGNS**

Coughing. Cardiomegaly causing dorsal displacement of trachea from radiographs 12/18/25. Current medications - Pimobendan 5mg 1/4th tab BID. Enalapril 2.5mg 1 tab in AM + 1/2 tab in PM. Lasix 12.5 mg 1.5-tab BID.

Abnormal PE/Chem/CBC/UA Results: Undefined Azotemia (increase crea+BUN). Progressive ALT elevation (hepatopathy vs GI vs other). Hepatomegaly on radiographs. Heart murmur 3/6.

**ULTRASONOGRAPHIC EXAMINATION OF THE HEART & ABDOMEN**

CANINE CARDIAC PARAMETERS	MR VMAX (m/s)	TR VMAX (m/s)	LA/AO (M-Mode)	LA/AO (Heart Base; Swe)	FS (%)	EF (%)	EPSS (cm)
NORMAL PARAMETER	4.5-5.5	<2.7	1.3	Up to 1.6	28-40	40-100	<0.6
PATIENT	5.0	2.2	1.2	1.4	47	81	NM
CANINE CARDIAC PARAMETERS	HR (BPM)	AV VMAX (m/s)	PV MAX (m/s)	BODY WEIGHT (kg)	LAD LA MAX 4 Chamber	LVIDd Avg; 2D and m-mode short axis (cm)	LVIDs Avg; 2D and m-mode short axis (cm)
NORMAL PARAMETER	50-100	0.7-1.7	0.7-1.6				
PATIENT	152	1.3	1.06	5.3	2.6	2.67	--

**Cardiac Presentation**

The echocardiogram in this patient demonstrated normal **left atrial** size based on 3 different LA measurement methods. Chamber volumes and echogenicity were normal. The cranial and caudal **mitral** valve leaflets presented vegetative thickening consistent with endocardiosis. Doppler indicated measurable insufficiency. The **left ventricle** presented normal thicknesses with linear contour and was not dilated nor restricted. The **myocardium** presented normal echogenicity without subjective evidence of significant fibrotic or ischemic disease. **Contractility** of the ventricular walls was adequate and in normal range for this patient evidenced by the fractional shortening measurement and subjective evaluation of the different regions of the myocardium. The **left ventricular outflow** tract demonstrated normal laminar flow and subjective structural integrity. The **right atrium** and auricle revealed normal size, structure and content. No evidence of masses was noted or chamber overload. **Tricuspid** valvular assessment demonstrated measurable insufficiency. The **right ventricle** was of normal size (1/3 diameter of LV), chordae structure, myocardial echogenicity and thickness. **Pulmonic** tract assessment revealed normal valve structure, laminar flow, and diameter (approx.1:1 pa/ao ratio). No visible **pericardial** or free pleura fluid was noted. No echographically detectable evidence of infiltrative disease was visible. The cranial **mediastinum and pericardial regions** were free of masses in the visible window. Period arrhythmia was noted in this patient.



**PATIENT**

**Urinary System**

Romeo Patel

The **urinary bladder**, trigone, and pelvic urethra presented normal thicknesses and normal tone. The ureters were not visible which is normal. No uroliths or sediment were visualized, and anechoic urine was present. No evidence of inflammatory or neoplastic changes were noted. Ureteral papillae were normal.

**SPECIES**

Canine

**BREED**

Toy Poodle

The **prostate** was uniformly enlarged with lobar swelling appeared to impinge upon the urethra and mildly deviate the descending colon. The prostatic tissue was hyperechoic containing focal areas of decreased echogenicity. These changes are suggestive of either chronic inflammatory episodes, benign cystic pathology or both. Underlying neoplasia cannot be completely ruled-out but is lower on the differential list. This presentation is most consistent with benign prostatic hyperplasia with possible active prostatitis. Neutering or off-label Finasteride (Propecia) (0.1-0.5 mg/kg Sid) treatment is indicated +/- FNA or prostatic wash cytology and culture. The prostate measured 2.6 cm width.

**SEX**

Male

The testicles were imaged and found to be uniform.

**AGE**

13 Years 3 Months

The **kidneys** revealed largely normal size and structure, corticomedullary definition and ratio (cortex 1/3 of medulla) were essentially maintained with some mild age-related loss of curvilinear patterns regarding the capsule and C/M junction. The cortices presented largely uniform texture with some increased echogenicity expected for his age patient. Medullary structure differed distinctly from that of the cortex. Slight areas of mineralization were present with slight left kidney pyelectasia. The left kidney measured 3.6 cm in length. The right kidney measured 4.0 cm in length.

**WEIGHT**

5.3 kg

**INTERPRETED BY**

**Adrenal Glands**

Eric Lindquist, DMV,  
 DABVP(CFM), Cert.  
 IVUSS

Both **adrenal glands** were visualized and recognized as having normal shape, size, position and echogenicity for this breed. The phrenic vasculature, glandular echogenicity and detail were unremarkable. Capsule, cortex, and medullary definition were normal for this age patient. The right adrenal gland measured 0.42 cm width at the caudal pole and 0.60 cm width at the cranial pole. The left adrenal gland measured 2.0 cm x 0.50 cm width.

**IMAGING PERFORMED BY**

**Spleen**

Vincent Ravancho CVT

The **spleen** presented a smooth homogeneous parenchyma hyperechoic to liver and renal cortical parenchyma. The capsule was smooth without noticeable expansion or deviation from within the spleen or adjacent pathology. The splenic vasculature demonstrated normal volume without signs of congestion or thrombosis. No sonographic evidence of acute or chronic inflammatory, neoplastic, or infarctual changes were noted.

**HOSPITAL NAME**

Banfield Bridgewater

**REFERRING VET**

Dr. Sousa

**Liver**

**INVOICE**

15161

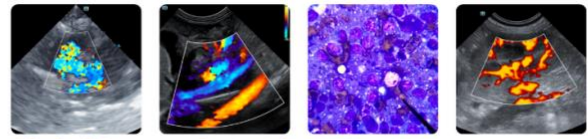
The dorsal cranial **liver** revealed a cyst measuring 3.8 cm by 3.1 cm yet does not appear pathological. The liver revealed slight hepatic vein dilation with mild increased portal markings. The cystic structure was nonvascular. The gallbladder was mildly over distended with suspended and dependent debris, yet not to the level of emerging mucocele, yet sludge appears to be mildly excessive. No adjunctive inflammation was noted.

**DATE**

04/16/26

**Gastrointestinal**

Examination of the **gastrointestinal tract** revealed a stomach and intestine free of stasis, of normal wall thickness, acceptable curvilinear mural detail, and peristaltic activity. Small and large intestine



**PATIENT**

Romeo Patel

**SPECIES**

Canine

**BREED**

Toy Poodle

**SEX**

Male

**AGE**

13 Years 3 Months

**WEIGHT**

5.3 kg

**INTERPRETED BY**

Eric Lindquist, DMV,  
DABVP(CFM), Cert.  
IVUSS

**IMAGING PERFORMED BY**

Vincent Ravancho CVT

**HOSPITAL NAME**

Banfield Bridgewater

**REFERRING VET**

Dr. Sousa

**INVOICE**

15161

**DATE**

04/16/26

demonstrated normal luminal chyme and stool consistency respectively. No obstructive or overt infiltrative disease was noted. No associated abnormal lymphatic activity was noted.

**Pancreas**

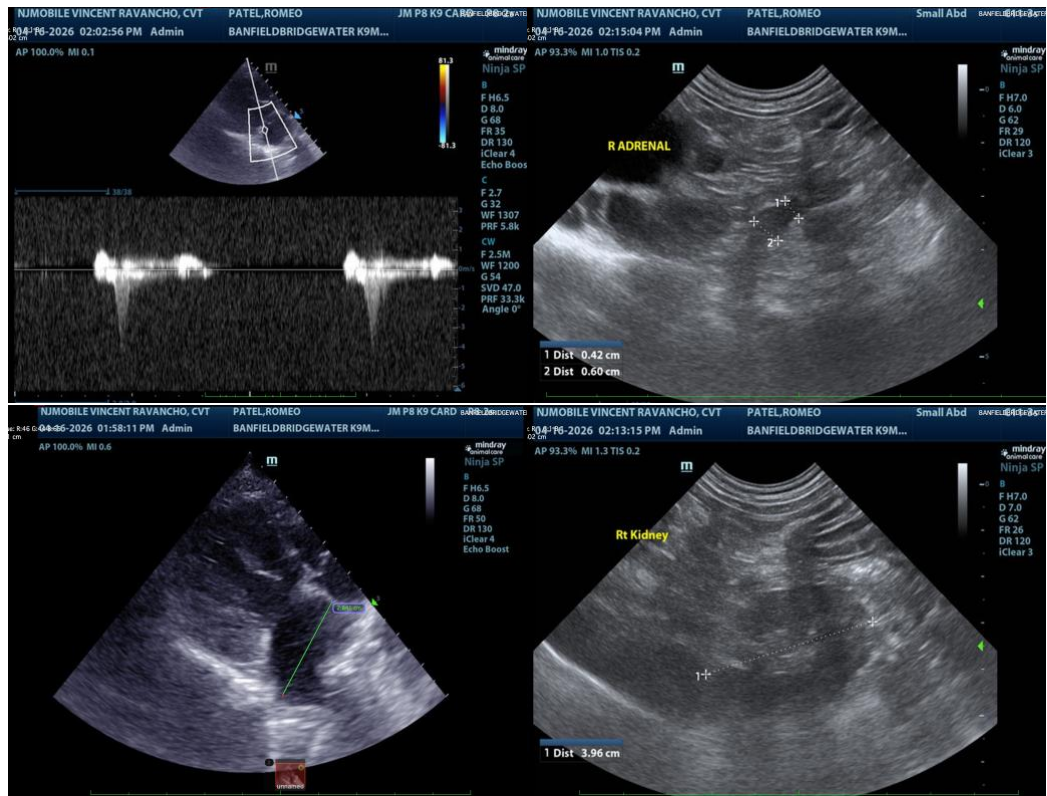
The base and limbs of the **pancreas** were observed to be largely isoechoic to surrounding omental fat. Pancreatic duct and capsular contour were acceptably normal and parenchyma respected normal curvilinear patterns. No overt evidence of active inflammatory or neoplastic disease was noted.

**ULTRASONOGRAPHIC FINDINGS**

- Stable valvular disease- no evidence of volume overload.
- Age-related renal changes with mineralizations and left kidney pyelectasia.
- Benign prostatic hyperplasia pattern.
- Hepatic cyst- benign.
- Mild gallbladder debris.

**INTERPRETATION OF THE FINDINGS & FURTHER RECOMMENDATIONS**

Ursodiol therapy could be justified. The cough is non-cardiogenic at this time.





**PATIENT**

Romeo Patel

**SPECIES**

Canine

**BREED**

Toy Poodle

**SEX**

Male

**AGE**

13 Years 3 Months

**WEIGHT**

5.3 kg

**INTERPRETED BY**

Eric Lindquist, DMV,  
 DABVP(CFM), Cert.  
 IVUSS

**IMAGING PERFORMED BY**

Vincent Ravancho CVT

**HOSPITAL NAME**

Banfield Bridgewater

**REFERRING VET**

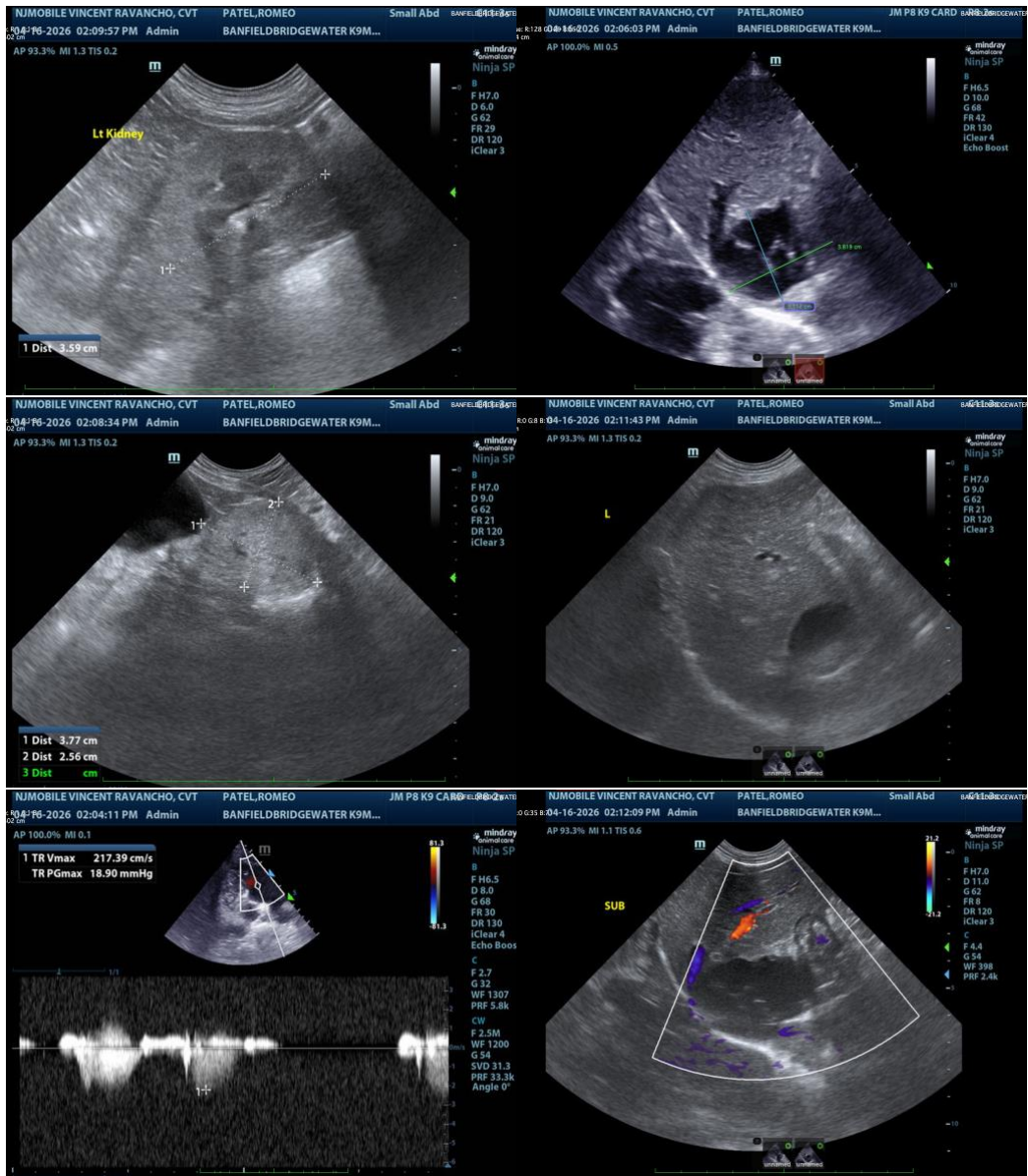
Dr. Sousa

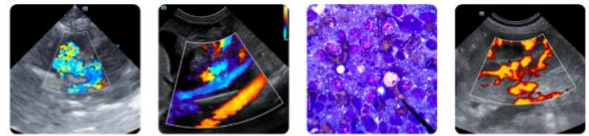
**INVOICE**

15161

**DATE**

04/16/26





**PATIENT**

Romeo Patel

**SPECIES**

Canine

**BREED**

Toy Poodle

**SEX**

Male

**AGE**

13 Years 3 Months

**WEIGHT**

5.3 kg

**INTERPRETED BY**

Eric Lindquist, DMV,  
DABVP(CFM), Cert. IVUSS

**IMAGING PERFORMED BY**

Vincent Ravancho CVT

**HOSPITAL NAME**

Banfield Bridgewater

**REFERRING VET**

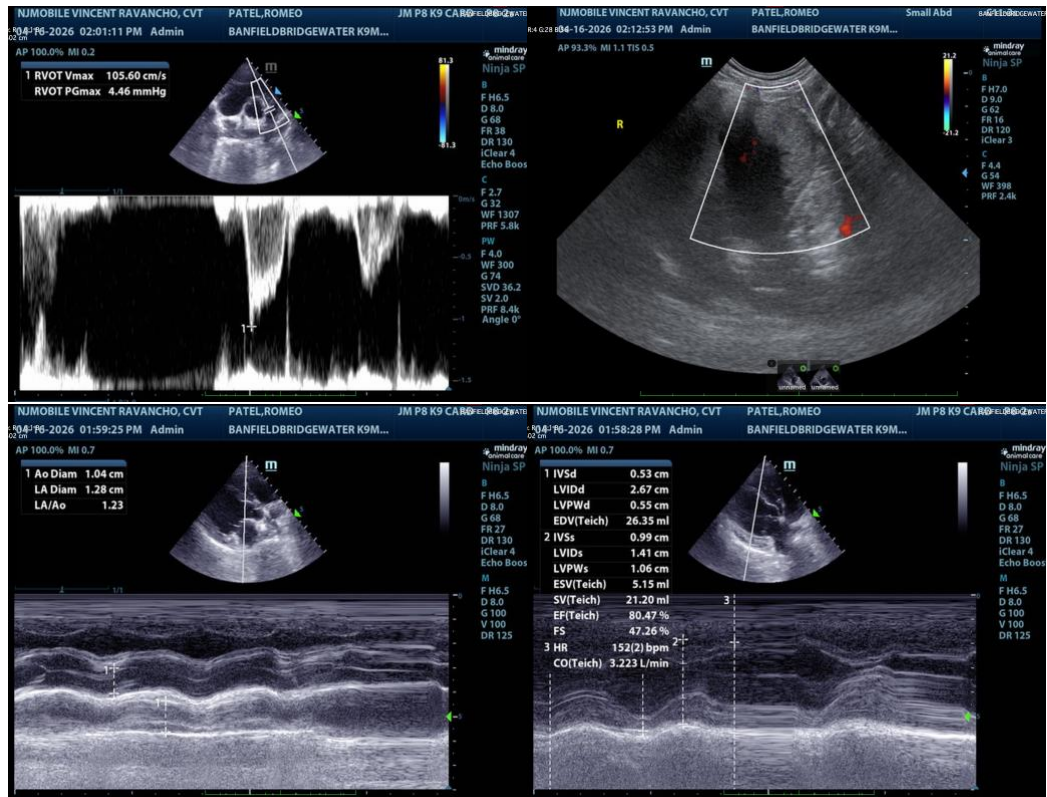
Dr. Sousa

**INVOICE**

15161

**DATE**

04/16/26



The information and recommendations provided are based on the images presented by the referring veterinarian/sonographer. No evaluation can be communicated regarding pathology that was not visible in the image/video clips provided.

Thank you for this referral. If the clinical or image interpretation does not parallel your findings or if I can be of any further assistance, please contact me.

**Eric Lindquist, DMV, DABVP(CFM), Cert. IVUSS,**

CEO, Owner, Founder -- SonoPath.com

[info@SonoPath.com](mailto:info@SonoPath.com)