



**PATIENT**

Nutmeg DeBlanc

**SPECIES**

Feline

**BREED**

DSH

**SEX**

Neutered Male

**AGE**

7 Years

**WEIGHT**

9 pounds

**INTERPRETED BY**

Eric Lindquist, DMV,  
DABVP(CFM), Cert.  
IVUSS

**IMAGING PERFORMED BY**

Rebecca Hamilton

**HOSPITAL NAME**

All Creatures Great &  
Small Denville

**REFERRING VET**

Dr. Silas Ashmore

**INVOICE**

15160

**DATE**

04/16/26

**PRESENTING CLINICAL SIGNS**

Routine cardiac and abdomen for sx, Chronic gastritis, Xrays stomach and small bowels thicker than normal. meds: Cerenia

**ULTRASONOGRAPHIC EXAMINATION OF THE HEART & ABDOMEN**

FELINE CARDIAC PARAMETERS	BODY WEIGHT (lbs)	HR (BPM)	IVSd (cm)	LVIDd (cm)	LVWd (cm)	FS (%)	EF (%)
NORMAL PARAMETER	-----	150-240	0.3-0.6	1.0-2.1	0.25-0.6	35-67	80-100
PATIENT	9.0	200	0.45	1.6	0.44	54	88
FELINE CARDIAC PARAMETERS	LA/AO (M-mode)	LA/AO HEART BASE (Sisson)	LAD LA MAX 4 Chamber	LVOT VEL. (m/s)	RVOT VEL. (m/s)	IVRT (m/)	
NORMAL PARAMETER	<1.5	1.6	0.7-1.7	<1.6	<1.3	40-60	
PATIENT	1.17	--	1.2	1.1	0.9	NM	
Adapted from June Boon, Veterinary Echocardiography, 1998 Sisson D et al. JVIM 1991; 5: 232, Jacobs et al. Am J Vet Res 1985; 46:1705							

E-wave velocity: 0.9 // EPSS: 0.1

**Cardiac Presentation**

The echocardiogram in this patient demonstrated normal **left atrial** size based on 3 separate LA measurements. The cranial and caudal **mitral** valve leaflets presented normal linear structure and kinetics.. The **left ventricle** presented normal thicknesses with linear contour and was not dilated nor restricted. The **myocardium** presented normal echogenicity without subjective evidence of significant fibrotic or ischemic disease. **Contractility** of the ventricular walls was adequate and in normal range for this patient evidenced by the fractional shortening measurement and subjective evaluation of the different regions and angles of the myocardium. The **left ventricular outflow** tract demonstrated normal laminar flow and subjective structural integrity. The **right atrium** and auricle revealed normal size, structure and content. No evidence of masses was noted or chamber overload. **Tricuspid** valvular assessment demonstrated adequate linear morphology and kinetics. The **right ventricle** was of normal size (1/3 diameter of LV), chordae structure, myocardial echogenicity and thickness. **Pulmonic** tract assessment revealed normal valve structure, laminar flow, and diameter (approx.1:1 pa/ao ratio). No visible **pericardial** or free pleura fluid was noted or extra cardiac pathology in the visible planes. The cranial **mediastinum** and **pericardial** regions were free of masses in the visible window.

**Urinary System**

The **urinary bladder**, trigone, and pelvic urethra presented normal thicknesses and normal tone. The ureters were not visible which is normal. No uroliths or sediment were visualized, and anechoic urine was present. No evidence of inflammatory or neoplastic changes were noted. Ureteral papillae were normal.



**PATIENT**

Nutmeg DeBlanc

**SPECIES**

Feline

**BREED**

DSH

**SEX**

Neutered Male

**AGE**

7 Years

**WEIGHT**

9 pounds

**INTERPRETED BY**

Eric Lindquist, DMV,  
DABVP(CFM), Cert.  
IVUSS

**IMAGING PERFORMED BY**

Rebecca Hamilton

**HOSPITAL NAME**

All Creatures Great &  
Small Denville

**REFERRING VET**

Dr. Silas Ashmore

**INVOICE**

15160

**DATE**

04/16/26

The **kidneys** revealed normal size and structure, corticomedullary definition and ratio for this age. The cortices presented largely uniform texture with normal echogenic relationship to liver and spleen. Medullary structure differed distinctly from the cortex and no evidence of pelvic dilation was present. The capsules were acceptably uniform without significant irregularities. The left kidney measured 3.92 cm in length. The right kidney measured 3.72 cm in length.

**Adrenal Glands**

Both **adrenal glands** were visualized and recognized as having normal shape, size, position and echogenicity for this breed. The phrenic vasculature, glandular echogenicity and detail were unremarkable. Capsule, cortex, and medullary definition were normal for this age patient. The left adrenal gland measured 0.38 cm width. The right adrenal gland measured 0.38 cm width.

**Spleen**

The **spleen** presented a smooth homogeneous parenchyma hyperechoic to liver and renal cortical parenchyma. The capsule was smooth without noticeable expansion or deviation from within the spleen or adjacent pathology. The splenic vasculature demonstrated normal volume without signs of congestion or thrombosis. No sonographic evidence of acute or chronic inflammatory, neoplastic, or infarctual changes were noted.

**Liver**

The **liver** revealed slight coarse architecture with a minor amount of hepatic remodeling. The gallbladder and common bile duct were unremarkable.

**Gastrointestinal**

Examination of the **gastrointestinal tract** revealed a stomach and intestine free of stasis, of normal wall thickness, acceptable curvilinear mural detail, and peristaltic activity. Small and large intestine demonstrated normal luminal chyme and stool consistency respectively. No obstructive or overt infiltrative disease was noted. No associated abnormal lymphatic activity was noted.

**Pancreas**

The base and limbs of the **pancreas** were observed to be largely isoechoic to surrounding omental fat. Some mild parenchymal remodeling, however, with mild deviation from curvilinear normalcy was observed. Pancreatic duct and capsular irregularities were present consistent with age related changes. If pain upon imaging (+ Murphy sign) was present or if the patient is focally painful in subxiphoid palpation then low-grade smoldering chronic pancreatitis should be suspected.

**Free Abdomen**

Some reactive mesentery was noted in the mesenteric root in this patient with potential steatitis. This may be remodeling owing to prior episodes of steatitis.

**ULTRASONOGRAPHIC FINDINGS**

- Mild pancreatic/hepatic remodeling.
- Age-related abdominal changes otherwise.
- Normal echocardiogram.

**INTERPRETATION OF THE FINDINGS & FURTHER RECOMMENDATIONS**



**PATIENT**

Mid abdominal palpation is recommended. No evidence of visceral pathology.

Nutmeg DeBlanc

**SPECIES**

Feline

**BREED**

DSH

**SEX**

Neutered Male

**AGE**

7 Years

**WEIGHT**

9 pounds

**INTERPRETED BY**

Eric Lindquist, DMV,  
 DABVP(CFM), Cert.  
 IVUSS

**IMAGING PERFORMED BY**

Rebecca Hamilton

**HOSPITAL NAME**

All Creatures Great &  
 Small Denville

**REFERRING VET**

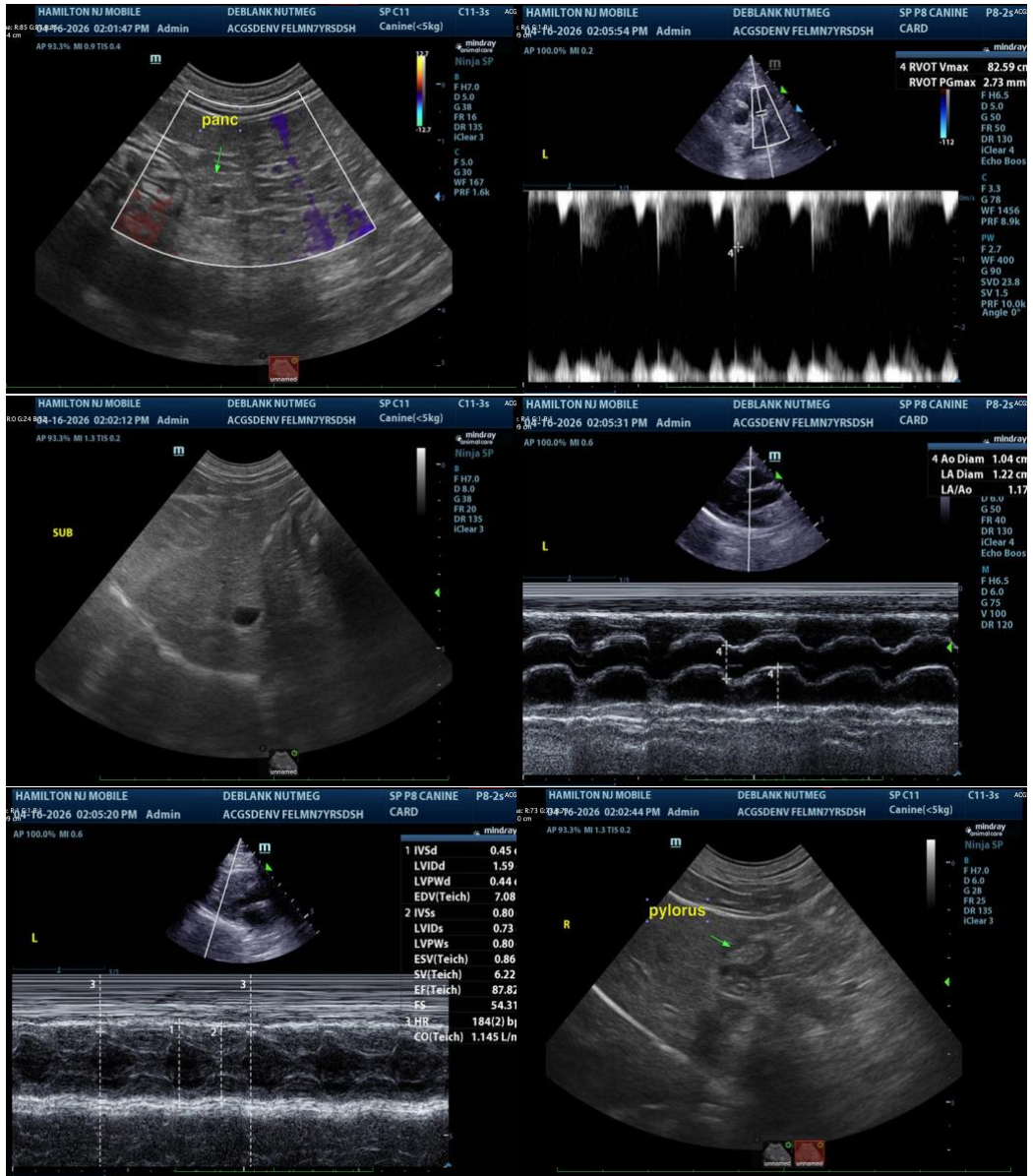
Dr. Silas Ashmore

**INVOICE**

15160

**DATE**

04/16/26





**PATIENT**

Nutmeg DeBlanc

**SPECIES**

Feline

**BREED**

DSH

**SEX**

Neutered Male

**AGE**

7 Years

**WEIGHT**

9 pounds

**INTERPRETED BY**

Eric Lindquist, DMV,  
 DABVP(CFM), Cert.  
 IVUSS

**IMAGING PERFORMED BY**

Rebecca Hamilton

**HOSPITAL NAME**

All Creatures Great &  
 Small Denville

**REFERRING VET**

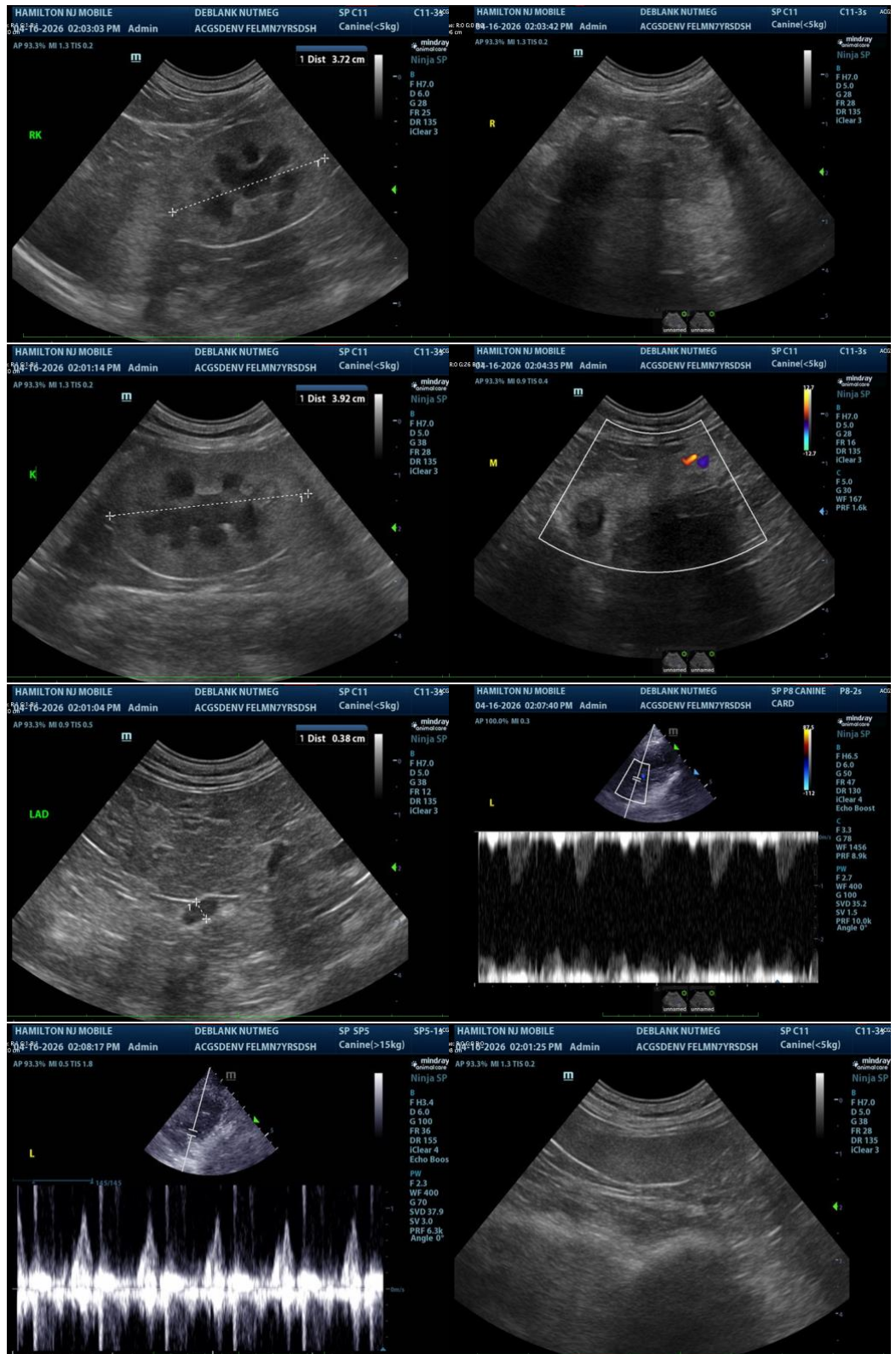
Dr. Silas Ashmore

**INVOICE**

15160

**DATE**

04/16/26





**PATIENT**

Nutmeg DeBlanc

**SPECIES**

Feline

**BREED**

DSH

**SEX**

Neutered Male

**AGE**

7 Years

**WEIGHT**

9 pounds

**INTERPRETED BY**

Eric Lindquist, DMV,  
DABVP(CFM), Cert.  
IVUSS

**IMAGING  
PERFORMED BY**

Rebecca Hamilton

**HOSPITAL NAME**

All Creatures Great &  
Small Denville

**REFERRING VET**

Dr. Silas Ashmore

**INVOICE**

15160

**DATE**

04/16/26

The information and recommendations provided are based on the images presented by the referring veterinarian/sonographer. No evaluation can be communicated regarding pathology that was not visible in the image/video clips provided.

Thank you for this referral. If the clinical or image interpretation does not parallel your findings or if I can be of any further assistance, please contact me.

**Eric Lindquist, DMV, DABVP(CFM), Cert. IVUSS,**

CEO, Owner, Founder -- SonoPath.com

[info@SonoPath.com](mailto:info@SonoPath.com)