



PATIENT

Murry Sullivan

SPECIES

Feline

BREED

DSH

SEX

Neutered Male

AGE

15

WEIGHT

9.6 pounds

INTERPRETED BY

Eric Lindquist, DMV,
DABVP(CFM), Cert.
IVUSS

IMAGING PERFORMED BY

Dr. Shark

HOSPITAL NAME

Kew Gardens Animal
Hospital

REFERRING VET

Dr. Nader Shafik

INVOICE

15151

DATE

04/16/26

PRESENTING CLINICAL SIGNS

Pancreatitis, lethargic, anorexia, hyperthyroidism.

Abnormal PE/Chem/CBC/UA Results: mild pancreatitis, high WBCs, Neutrophilia

ULTRASONOGRAPHIC EXAMINATION OF THE ABDOMEN

Urinary System

The **urinary bladder**, trigone, and pelvic urethra presented normal thicknesses and normal tone. The ureters were not visible which is normal. No uroliths or sediment were visualized, and anechoic urine was present. No evidence of inflammatory or neoplastic changes were noted. Ureteral papillae were normal.

The **kidneys** revealed largely normal size and structure, corticomedullary definition and ratio (cortex 1/3 of medulla) were essentially maintained with some moderate age-related loss of curvilinear patterns regarding the capsule and C/M junction. The cortices presented largely uniform texture with some increased echogenicity expected for his age patient. Medullary structure differed distinctly from that of the cortex. Dystrophic mineralization was noted and non-obstructive at this time. The left kidney measured 3.1 cm in length. The right kidney measured 3.1 cm in length.

Adrenal Glands

Both **adrenal glands** were not visualized.

Spleen

The **spleen** presented nodular, irregular and mildly enlarged.

Liver

The **liver** images from right and left intercostal as well as subcostal views revealed subjectively normal liver size, contour, and structure. Some mild age-related parenchymal remodeling was noted but likely not clinically significant at this time. Vascular and biliary tracts were of normal volume and no evidence of congestion was noted. The gallbladder presented some dependent debris with essentially normal contour. The cystic and common bile ducts were normal. No overt evidence of active inflammatory, infiltrative or regenerative pathology was noted but should be paired with current or past LE elevations regarding any clinical significance to this presentation. The hepatic lymph nodes were unremarkable.

Gastrointestinal

The **gastrointestinal tract** appeared unremarkable yet was enveloped by the nodular mesentery.

Pancreas

An overt mass was noted in the region of the **pancreas**.

Free Abdomen

Echogenic free fluid was noted in the abdomen. The omentum presented with diffuse nodular changes with coalesced mesentery around the pancreas.



PATIENT

Murry Sullivan

SPECIES

Feline

BREED

DSH

SEX

Neutered Male

AGE

15

WEIGHT

9.6 pounds

INTERPRETED BY

Eric Lindquist, DMV,
DABVP(CFM), Cert.
IUUSS

IMAGING PERFORMED BY

Dr. Shark

HOSPITAL NAME

Kew Gardens Animal
Hospital

REFERRING VET

Dr. Nader Shafik

INVOICE

15151

DATE

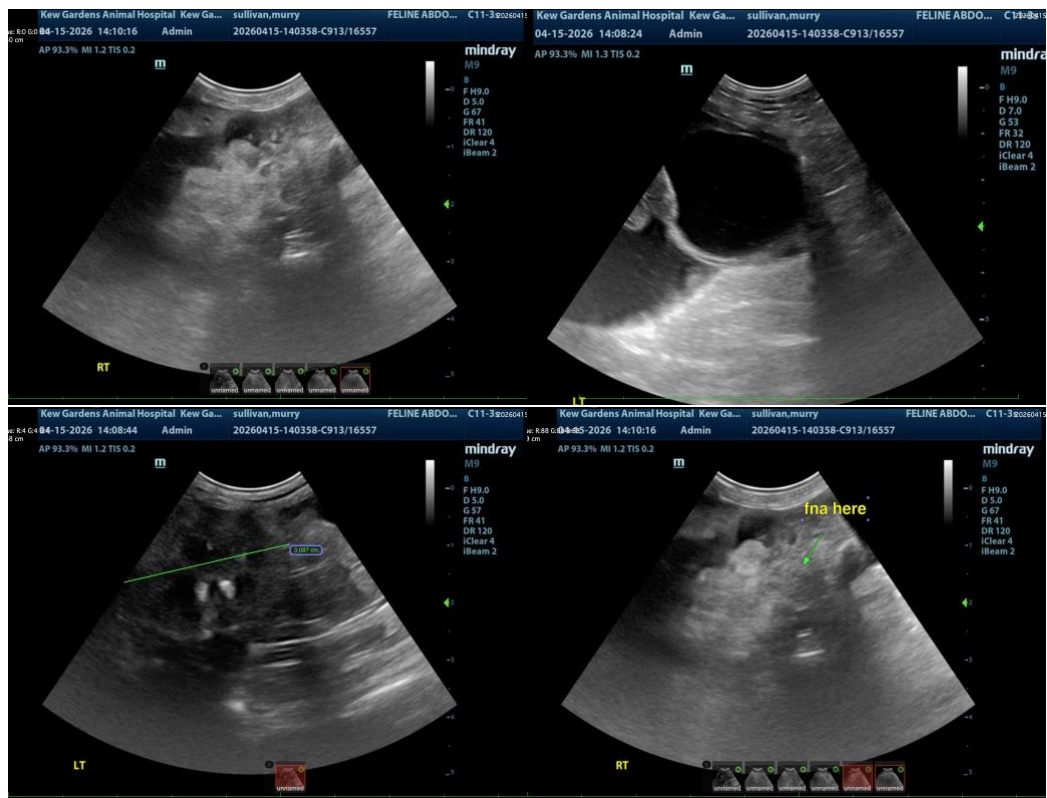
04/16/26

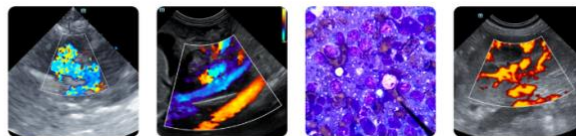
ULTRASONOGRAPHIC FINDINGS

- Pancreatic mesenteric mass enveloping the upper gastrointestinal tract- pancreatic carcinomatosis, lymphomatosis or similar.
- Nodular spleen.
- Hepatic remodeling.
- Secondary ascites owing to lymphatic obstruction and perineoplastic effusion.

INTERPRETATION OF THE FINDINGS & FURTHER RECOMMENDATIONS

Ultrasound guided FNA of the mass should prove effective on definitive diagnosis or cytospin of the free fluid. Prognosis is poor.





PATIENT

Murry Sullivan

SPECIES

Feline

BREED

DSH

SEX

Neutered Male

AGE

15

WEIGHT

9.6 pounds

INTERPRETED BY

Eric Lindquist, DMV,
DABVP(CFM), Cert.
IVUSS

IMAGING PERFORMED BY

Dr. Shark

HOSPITAL NAME

Kew Gardens Animal
Hospital

REFERRING VET

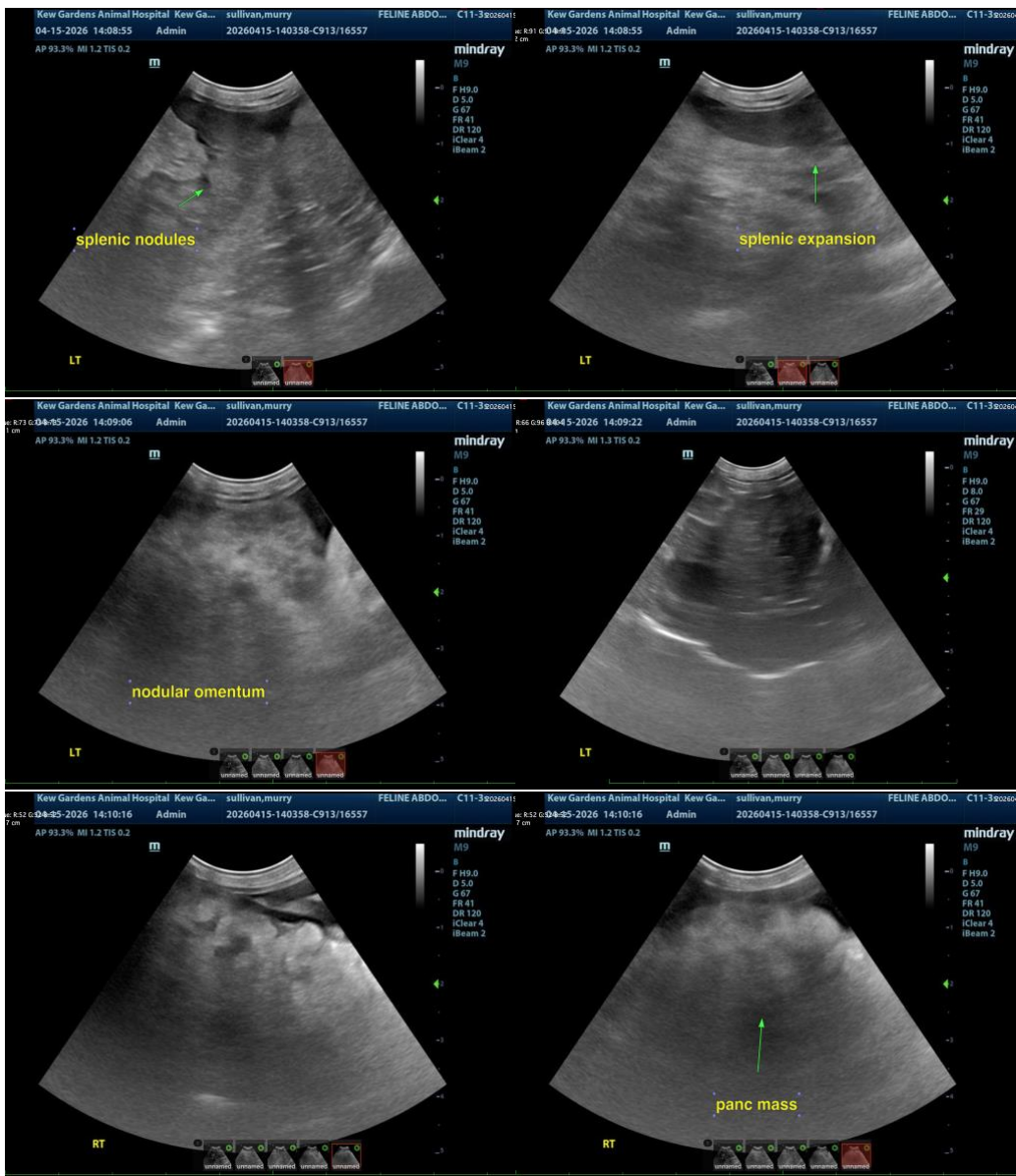
Dr. Nader Shafik

INVOICE

15151

DATE

04/16/26



The information and recommendations provided are based on the images presented by the referring veterinarian/sonographer. No evaluation can be communicated regarding pathology that was not visible in the image/video clips provided.

Thank you for this referral. If the clinical or image interpretation does not parallel your findings or if I can be of any further assistance, please contact me.

Eric Lindquist, DMV, DABVP(CFM), Cert. IVUSS,

CEO, Owner, Founder -- SonoPath.com

info@SonoPath.com



PATIENT

Murry Sullivan

SPECIES

Feline

BREED

DSH

SEX

Neutered Male

AGE

15

WEIGHT

9.6 pounds

INTERPRETED BY

Eric Lindquist, DMV,
DABVP(CFM), Cert.
IVUSS

IMAGING PERFORMED BY

Dr. Shark

HOSPITAL NAME

Kew Gardens Animal
Hospital

REFERRING VET

Dr. Nader Shafik

INVOICE

15151

DATE

04/16/26