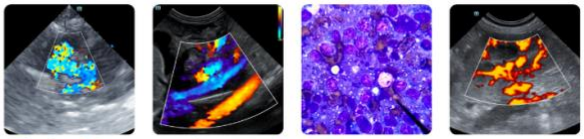

PATIENT
Mollie Niquette

SPECIES
Canine

BREED
Shih Tzu

SEX
Spayed Female

AGE
14 Years 9 Months

WEIGHT
20.2 pounds

INTERPRETED BY
Eric Lindquist, DMV, DABVP(CFM), Cert. IVUSS

IMAGING PERFORMED BY
Hannah Shelley, DVM

HOSPITAL NAME
Malletts Bay Veterinary Hospital

REFERRING VET
Hannah Shelley, DVM

INVOICE
15171

DATE
04/16/26

PRESENTING CLINICAL SIGNS

Acute lethargy and anorexia starting 4/14/26, progression to vomiting 4/16/26. Unintentional wt loss (2lb over the past 9 mos).

PE: icteric, 5-7% dehydration, cranial abd discomfort, CH17: mild eosinopenia, marked elevation of ALT/ALP/GGT, mildly high bilirubin 4DX: neg qPL: <30 (<200) AXR: unremarkable

ULTRASONOGRAPHIC EXAMINATION OF THE ABDOMEN

Urinary System

The **urinary bladder**, trigone, and pelvic urethra to a depth of 2.0 cm presented normal thicknesses and normal tone. The ureters were not visible which is normal. No uroliths or sediment were visualized, and anechoic urine was present. No evidence of inflammatory or neoplastic changes were noted. Ureteral papillae were normal.

The **kidneys** revealed normal size and structure, corticomedullary definition and ratio for this age. The cortices presented largely uniform texture with normal echogenic relationship to liver and spleen. Medullary structure differed distinctly from the cortex and no evidence of pelvic dilation was present. The capsules were acceptably uniform without significant irregularities. The left kidney measured 4.9 cm in length. The right kidney measured 5.6 cm in length.

Adrenal Glands

The **left adrenal gland** was slightly enlarged and uniform measuring 0.90 cm width.

The right adrenal gland was mildly enlarged and slightly nodular measuring 1.1 cm width at the cranial pole and 0.80 cm width at the caudal pole.

Spleen

The **spleen** presented a smooth homogeneous parenchyma hyperechoic to liver and renal cortical parenchyma. The capsule was smooth without noticeable expansion or deviation from within the spleen or adjacent pathology. The splenic vasculature demonstrated normal volume without signs of congestion or thrombosis. No sonographic evidence of acute or chronic inflammatory, neoplastic, or infarctual changes were noted.

Liver

The **liver** presented with multifocal hypoechoic nodular changes and appear nondisruptive, however, a minor microcystic nodule was noted in the mid liver measuring 1.0 cm. Slight increased portal markings and mild irregular contour was also present. The gallbladder and common bile duct were unremarkable.

Gastrointestinal

The **gastric** wall was mildly thickened with some early loss of mural detail in the pyloric antrum. The small intestine and colon were unremarkable.

Pancreas

Superimposing the **pancreas** was a cystic nodule measuring 1.8 cm, yet more likely a superimposing lymph node. A larger microcystic nodule was present measuring 3.1 cm x 2.56 cm.

SonoPath
FOSTERING THE ART OF VETERINARY MEDICINE™

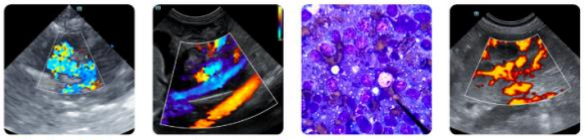

Clinical Sonography & Telecytology
Educational Teleconsultation Services™

SonoPath.com info@sonopath.com 1.800.838.4268

PATIENT

Mollie Niquette

SPECIES

Canine

BREED

Shih Tzu

SEX

Spayed Female

AGE

14 Years 9 Months

WEIGHT

20.2 pounds

INTERPRETED BY

Eric Lindquist, DMV, DABVP(CFM), Cert. IVUSS

IMAGING PERFORMED BY

Hannah Shelley, DVM

HOSPITAL NAME

Malletts Bay Veterinary Hospital

REFERRING VET

Hannah Shelley, DVM

INVOICE

15171

DATE

04/16/26

ULTRASONOGRAPHIC FINDINGS

- Bilateral adrenal hypertrophy, potential emerging PDH.
- Nodular liver.
- Superimposing cystic lymph nodes- chronic lymphadenitis versus possibility of round cell neoplasia.
- Gastric wall thickening.

INTERPRETATION OF THE FINDINGS & FURTHER RECOMMENDATIONS

Ultrasound guided FNA is indicated. There is an adjacent vessel to avoid during sampling. Cytology and culture is indicated of the presumed cystic and nodular lymph nodes as well as the liver. If the patient has PU/PD and urinary incontinence arrives less than 1020, eventual workup for PDH is indicated

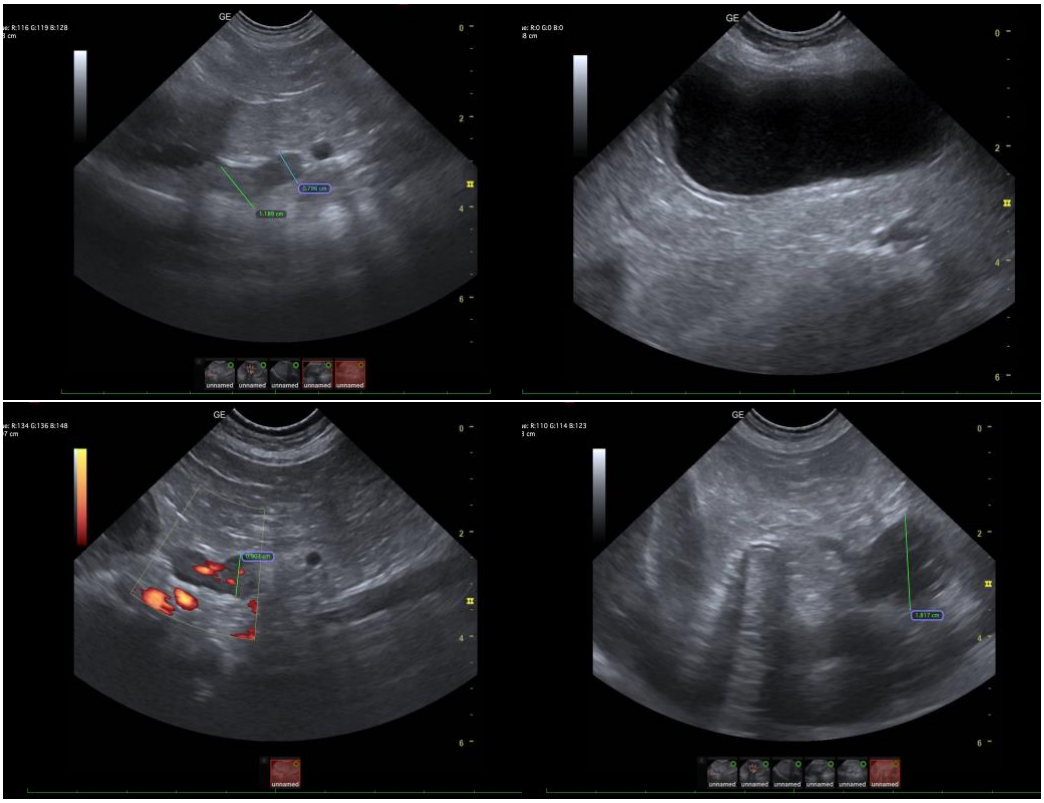

SonoPath
FOSTERING THE ART OF VETERINARY MEDICINE™

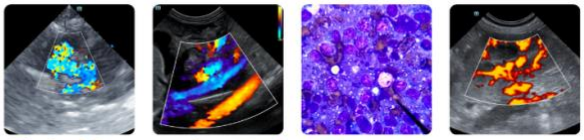

Clinical Sonography & Telecytology
Educational Teleconsultation Services™

SonoPath.com info@sonopath.com 1.800.838.4268

PATIENT

Mollie Niquette

SPECIES

Canine

BREED

Shih Tzu

SEX

Spayed Female

AGE

14 Years 9 Months

WEIGHT

20.2 pounds

INTERPRETED BY

Eric Lindquist, DMV, DABVP(CFM), Cert. IVUSS

IMAGING PERFORMED BY

Hannah Shelley, DVM

HOSPITAL NAME

Malletts Bay Veterinary Hospital

REFERRING VET

Hannah Shelley, DVM

INVOICE

15171

DATE

04/16/26

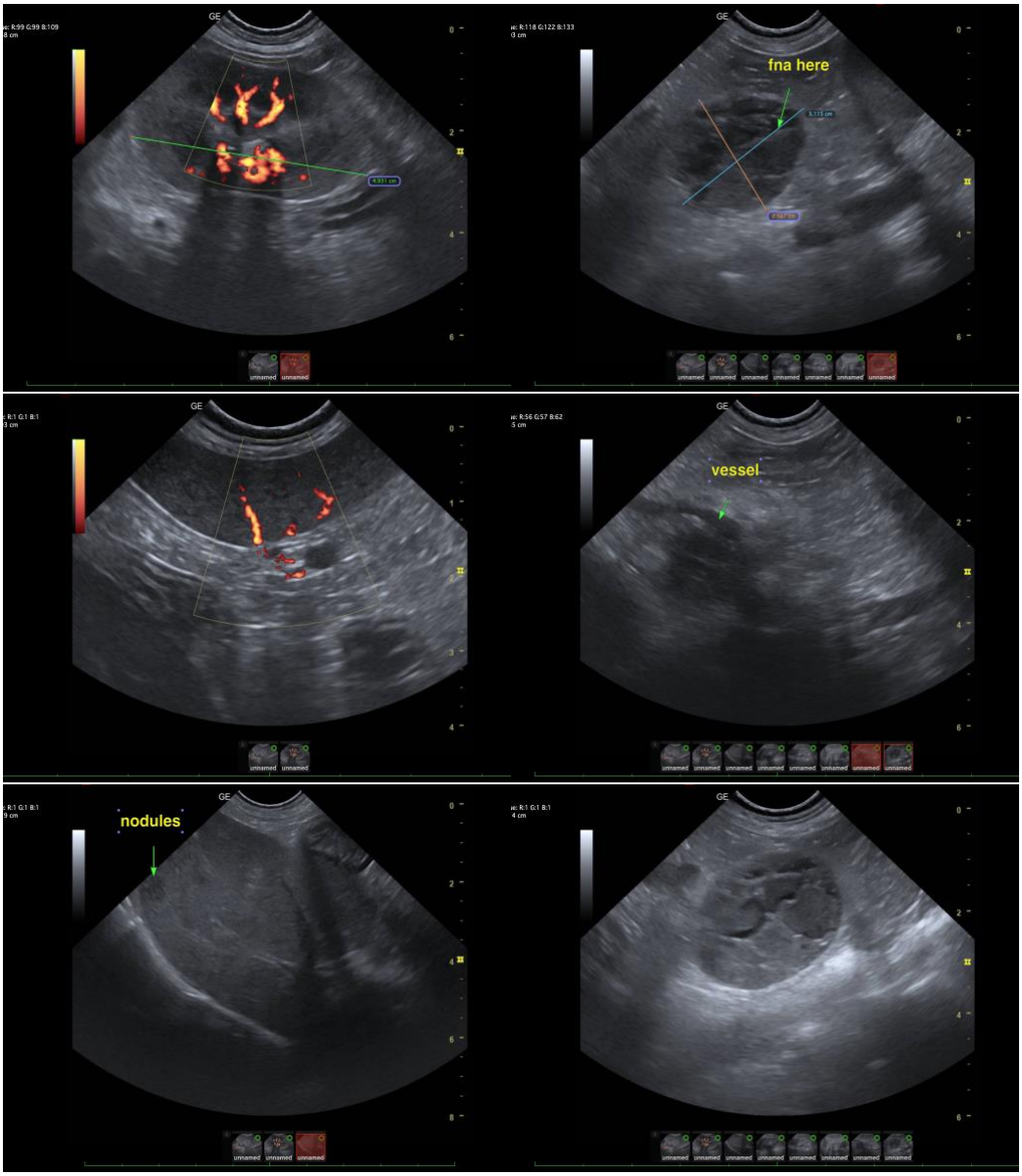

SonoPath
FOSTERING THE ART OF VETERINARY MEDICINE™

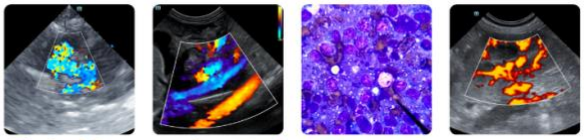

Clinical Sonography & Telecytology
Educational Teleconsultation Services™

SonoPath.com info@sonopath.com 1.800.838.4268

PATIENT

Mollie Niquette

SPECIES

Canine

BREED

Shih Tzu

SEX

Spayed Female

AGE

14 Years 9 Months

WEIGHT

20.2 pounds

INTERPRETED BY

Eric Lindquist, DMV, DABVP(CFM), Cert. IVUSS

IMAGING PERFORMED BY

Hannah Shelley, DVM

HOSPITAL NAME

Malletts Bay Veterinary Hospital

REFERRING VET

Hannah Shelley, DVM

INVOICE

15171

DATE

04/16/26

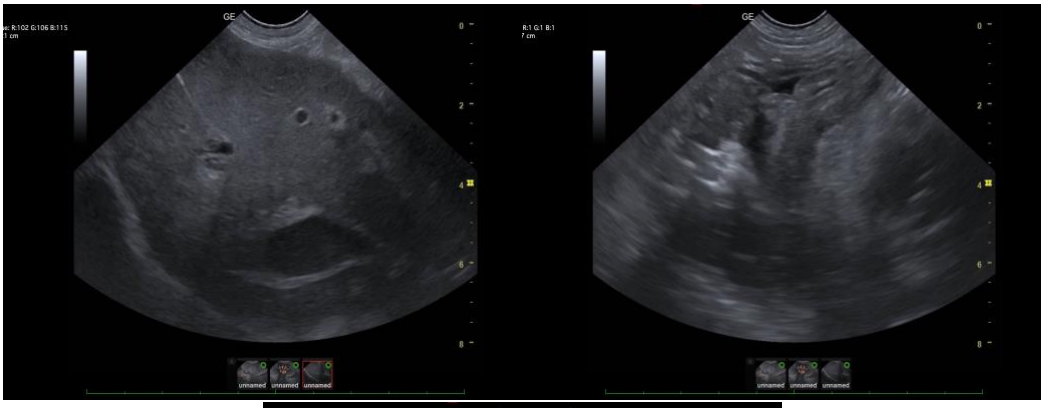

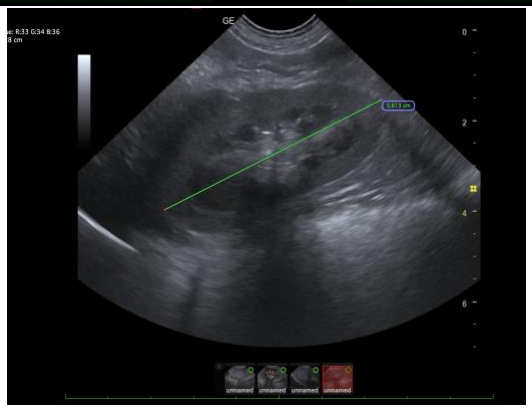

The information and recommendations provided are based on the images presented by the referring veterinarian/sonographer. No evaluation can be communicated regarding pathology that was not visible in the image/video clips provided.

Thank you for this referral. If the clinical or image interpretation does not parallel your findings or if I can be of any further assistance, please contact me.

Eric Lindquist, DMV, DABVP(CFM), Cert. IVUSS,

CEO, Owner, Founder -- SonoPath.com

info@SonoPath.com