



PATIENT

Zoey Hunt

SPECIES

Canine

BREED

Pembroke Welsh Corgi

SEX

Spayed female

AGE

9 years

WEIGHT

22 lbs

INTERPRETED BY

Eric Lindquist, DMV
DABVP, Cert. IVUSS

IMAGING PERFORMED BY

Dr. Levy

HOSPITAL NAME

Court Street VH

REFERRING VET

Dr. Levy

INVOICE

74508

DATE

4/15/26

PRESENTING CLINICAL SIGNS

History: Asymptomatic
Persistent elevation of ALT (264 U/L), even after starting Denamarin

ULTRASONOGRAPHIC EXAMINATION OF THE ABDOMEN

Urinary System

The **urinary bladder**, trigone, and pelvic urethra presented normal thicknesses and normal tone. The ureters were not visible which is normal. No uroliths or sediment were visualized and anechoic urine was present. No evidence of inflammatory or neoplastic changes was noted. Ureteral papillae were normal.

The **kidneys** revealed normal size and structure, corticomedullary definition and ratio for this age. The cortices presented largely uniform texture with normal echogenic relationship to liver and spleen. Medullary structure differed distinctly from the cortex and no evidence of pelvic dilation was present. The capsules were acceptably uniform without significant irregularities. The left kidney measured 4.0 cm. The right kidney measured 4.2 cm.

Adrenal Glands

The **left adrenal gland** was not overtly visualized. However, the regions of the left adrenal gland appeared unremarkable. The **right adrenal gland** was uniform and measured 0.5 cm.

Spleen

The **spleen** presented a smooth homogeneous parenchyma hyperechoic to liver and renal cortical parenchyma. The capsule was smooth without noticeable expansion or deviation from within the spleen or adjacent pathology. The splenic vasculature demonstrated normal volume without signs of congestion or thrombosis. No sonographic evidence of acute or chronic inflammatory, neoplastic, or infarctual changes was noted.

Liver

The **liver** revealed dilated hepatic veins, which could be normal if the patient was sedated at the time of the sonogram. Mildly increased portal markings were noted in the liver. The gallbladder presented acceptably thin walls with primarily anechoic content. The cystic and common bile ducts were normal. No pathological hepatic lymphadenopathy was evident.



PATIENT

Zoey Hunt

SPECIES

Canine

BREED

Pembroke Welsh Corgi

SEX

Spayed female

AGE

9 years

WEIGHT

22 lbs

INTERPRETED BY

Eric Lindquist, DMV
DABVP, Cert. IVUSS

IMAGING PERFORMED BY

Dr. Levy

HOSPITAL NAME

Court Street VH

REFERRING VET

Dr. Levy

INVOICE

74508

DATE

4/15/26

Gastrointestinal

Examination of the **gastrointestinal tract** revealed a stomach and intestine free of stasis, of normal wall thickness, acceptable curvilinear mural detail, and peristaltic activity. Small and large intestine demonstrated normal luminal chyme and stool consistency respectively. No obstructive or overt infiltrative disease was noted. No associated abnormal lymphatic activity was noted.

Pancreas

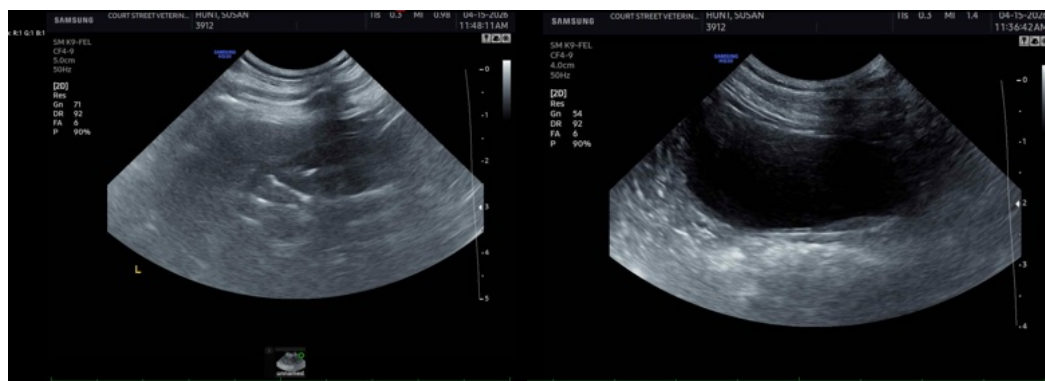
The base and limbs of the **pancreas** were observed to be largely isoechoic to surrounding omental fat. Pancreatic duct and capsular contour were acceptably normal and parenchyma respected normal curvilinear patterns. No overt evidence of active inflammatory or neoplastic disease was noted.

ULTRASONOGRAPHIC FINDINGS

Non-specific chronic inflammatory hepatopathy.

INTERPRETATION OF THE FINDINGS & FURTHER RECOMMENDATIONS

Ultrasound-guided FNA of the liver is indicated to assess inflammatory cell type. Leptospirosis titers are indicated to rule out occult disease.





PATIENT

Zoey Hunt

SPECIES

Canine

BREED

Pembroke Welsh Corgi

SEX

Spayed female

AGE

9 years

WEIGHT

22 lbs

INTERPRETED BY

Eric Lindquist, DMV
DABVP, Cert. IVUSS

IMAGING PERFORMED BY

Dr. Levy

HOSPITAL NAME

Court Street VH

REFERRING VET

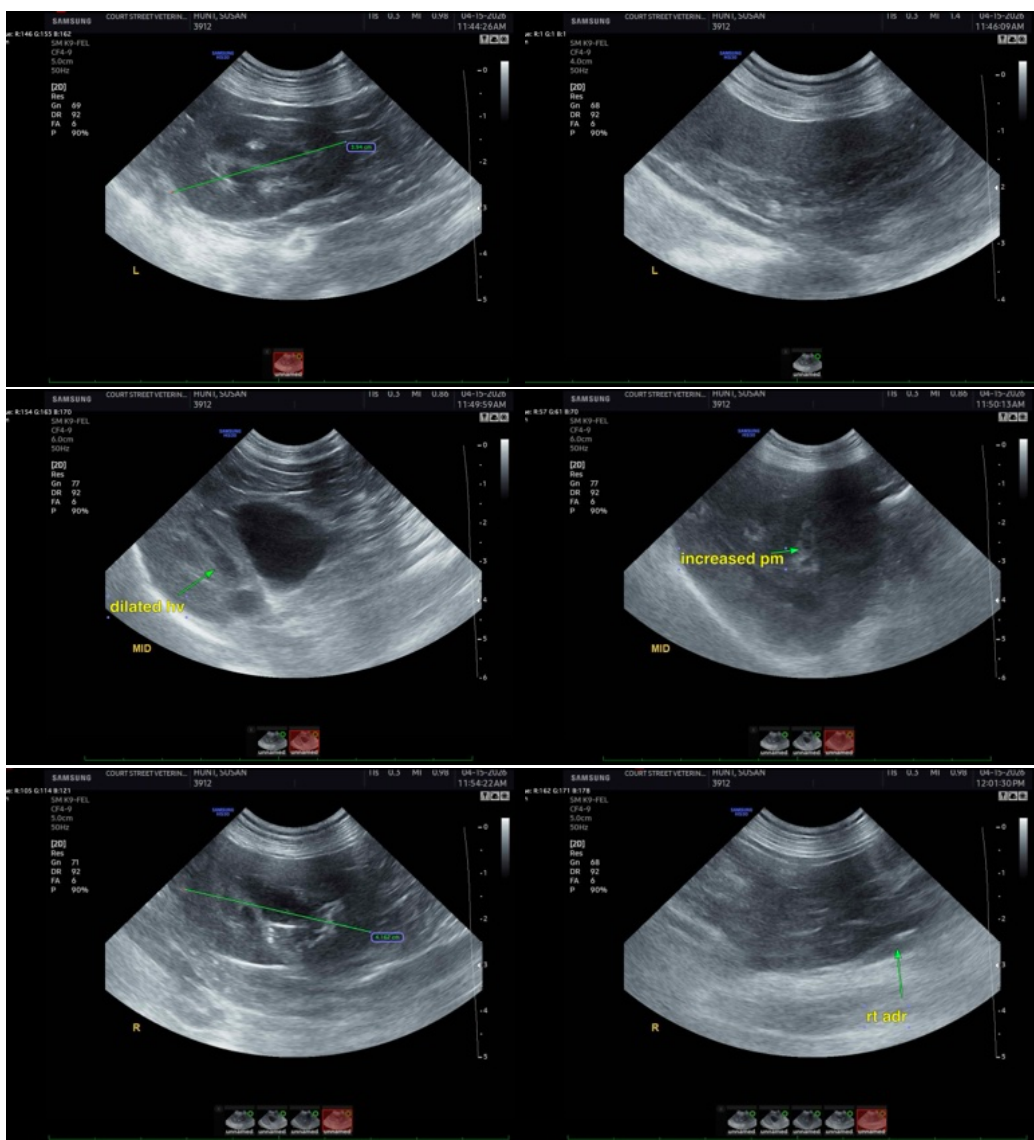
Dr. Levy

INVOICE

74508

DATE

4/15/26



The information and recommendations provided are based on the images presented by the referring veterinarian/sonographer. No evaluation can be communicated regarding pathology that was not visible in the image/video clips provided.

Thank you for this referral. If the clinical or image interpretation does not parallel your findings or if I can be of any further assistance please contact me.

Eric Lindquist, DMV, DABVP (CFM), Cert. IVUSS, CEO of SonoPath.com

info@SonoPath.com