



**PATIENT**

Toby Kimball Stanley

**SPECIES**

Canine

**BREED**

Mix

**SEX**

Male

**AGE**

8 years

**WEIGHT**

42 lbs

**INTERPRETED BY**

Eric Lindquist, DMV  
DABVP, Cert. IVUSS

**IMAGING PERFORMED BY**

Alex Klein

**HOSPITAL NAME**

Alison AH

**REFERRING VET**

Dr. Klein

**INVOICE**

74478

**DATE**

4/15/26

**PRESENTING CLINICAL SIGNS**

History: This is a very anxious dog on Clomicalm and pulsed here and there with Gabapentin. I have known the dog/owners for several years. Recently had dental work, very routine anesthetic event. Owner reported an episode of syncope during excitement at home over the spring break holiday. This sounded to me what might have been a vasovagal event but offered the cursory echo out of an abundance of caution.

Abnormal PE/Chem/CBC/UA Results: All BW WNL in November

**PRE-ANESTHETIC ECHOCARDIOGRAM**

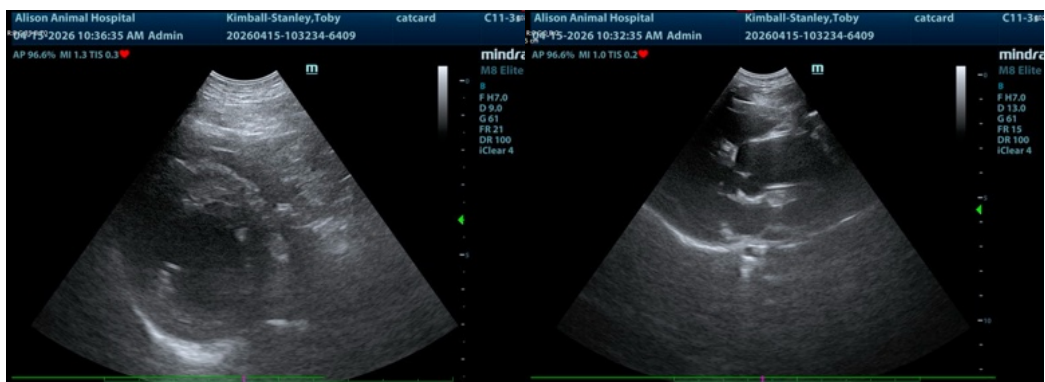
8 efficiency video clips from SDEP protocol provided.

All four chambers revealed normal volumes and contractility. No pericardial or pleural effusion noted. No gross abnormalities that would preclude anesthesia.

**INTERPRETATION OF THE FINDINGS & FURTHER RECOMMENDATIONS**

Anesthetic risk is considered normal to mild. No gross abnormalities noted on SDEP Screening Echo to contraindicate anesthesia. Minimal to no left atrial enlargement noted on images presented.

- a. However, judicious fluid administration is advised with careful RR/RE monitoring to screen for fluid overload.
- b. Monitoring of blood pressure, SpO2, CO2, and auscultation of heart and lungs during anesthesia should be done during every procedure.





## PATIENT

Toby Kimball Stanley

## SPECIES

Canine

## BREED

Mix

## SEX

Male

## AGE

8 years

## WEIGHT

42 lbs

## INTERPRETED BY

Eric Lindquist, DMV  
DABVP, Cert. IVUSS

## IMAGING PERFORMED BY

Alex Klein

## HOSPITAL NAME

Alison AH

## REFERRING VET

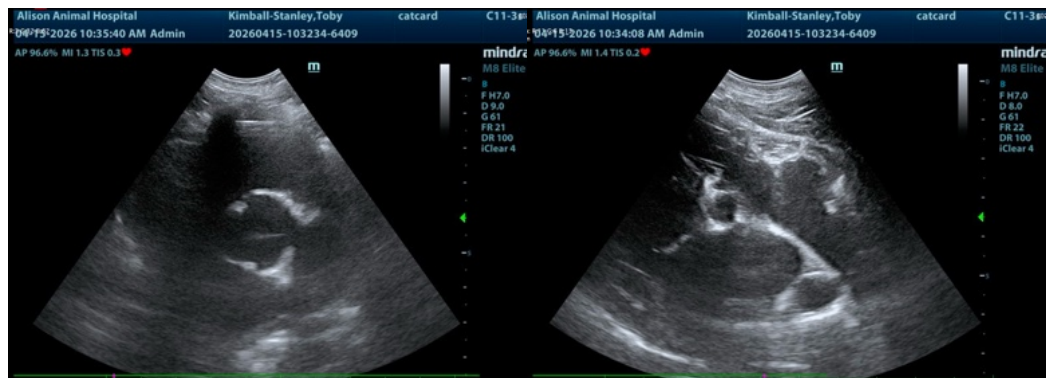
Dr. Klein

## INVOICE

74478

## DATE

4/15/26



The information and recommendations provided are based on the images presented by the referring veterinarian/sonographer. No evaluation can be communicated regarding pathology that was not visible in the image/video clips provided.

Thank you for this referral. If the clinical or image interpretation does not parallel your findings or if I can be of any further assistance please contact me.

Eric Lindquist, DMV, DABVP (CFM), Cert. IVUSS, CEO of SonoPath.com

[info@SonoPath.com](mailto:info@SonoPath.com)