

PATIENT

Sammy Nunez

SPECIES

Canine

BREED

Yorkie

SEX

Male

AGE

9 years

WEIGHT

13 lbs

INTERPRETED BY

Eric Lindquist, DMV
DABVP, Cert. IVUSS

IMAGING PERFORMED BY

Dr. Alex Klein

HOSPITAL NAME

Alison AH

REFERRING VET

Dr. Klein

INVOICE

74479

DATE

4/15/26

PRESENTING CLINICAL SIGNS

History: This is a nine year old healthy active dog in for a routine screening. No coughing or lethargy or murmur.

Abnormal PE/Chem/CBC/UA Results: BW all WNL

ULTRASONOGRAPHIC EXAMINATION OF THE ABDOMEN

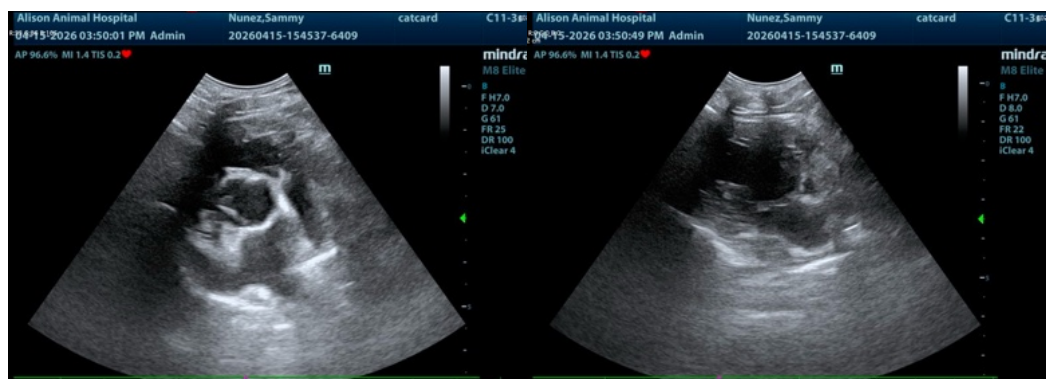
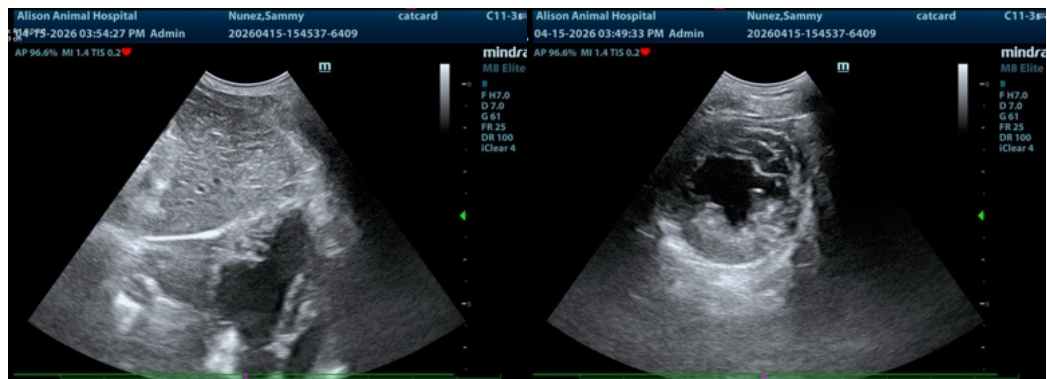
8 efficiency video clips from SDEP protocol provided.

All four chambers revealed normal volumes and contractility. No pericardial or pleural effusion noted. o gross abnormalities that would preclude anesthesia.

INTERPRETATION OF THE FINDINGS & FURTHER RECOMMENDATIONS

Anesthetic risk is considered normal to mild: No gross abnormalities noted on SDEP^R Screening Echo to contraindicate anesthesia. Minimal to no left atrial enlargement noted on images presented.

1. However, judicious fluid administration is advised with careful RR/RE monitoring to screen for fluid overload.
2. Monitoring of blood pressure, SpO₂, CO₂, and auscultation of heart and lungs during anesthesia should be done during every procedure.





PATIENT

Sammy Nunez

SPECIES

Canine

BREED

Yorkie

SEX

Male

AGE

9 years

WEIGHT

13 lbs

INTERPRETED BY

Eric Lindquist, DMV
DABVP, Cert. IVUSS

IMAGING PERFORMED BY

Dr. Alex Klein

HOSPITAL NAME

Alison AH

REFERRING VET

Dr. Klein

INVOICE

74479

DATE

4/15/26

The information and recommendations provided are based on the images presented by the referring veterinarian/sonographer. No evaluation can be communicated regarding pathology that was not visible in the image/video clips provided.

Thank you for this referral. If the clinical or image interpretation does not parallel your findings or if I can be of any further assistance please contact me.

Eric Lindquist, DMV, DABVP (CFM), Cert. IVUSS, CEO of SonoPath.com

info@SonoPath.com