



PATIENT

Amari Duran

SPECIES

Canine

BREED

Pit Bull

SEX

Spayed Female

AGE

10 Years

WEIGHT

63.7 lbs

INTERPRETED BY

Eric Lindquist, DMV,
DABVP (CFM), Cert.
IVUSS

IMAGING PERFORMED BY

Sara Hansen

HOSPITAL NAME

Paws Animal Hospital

REFERRING VET

Dr. Johnson

INVOICE

74475

DATE

4/15/26

PRESENTING CLINICAL SIGNS

History of mast cell tumors. One not completely excised on left front limb. 2 firm masses in area of right pre-scapular lymph node.

ABNORMAL Labwork Values: 3/15/26 WBC 5.9 low, HGB 18.6 high

Current Medications: Carprofen, Benadryl, Famotidine, Sertraline, and Incurin

LIMITED ULTRASONOGRAPHIC EXAMINATION

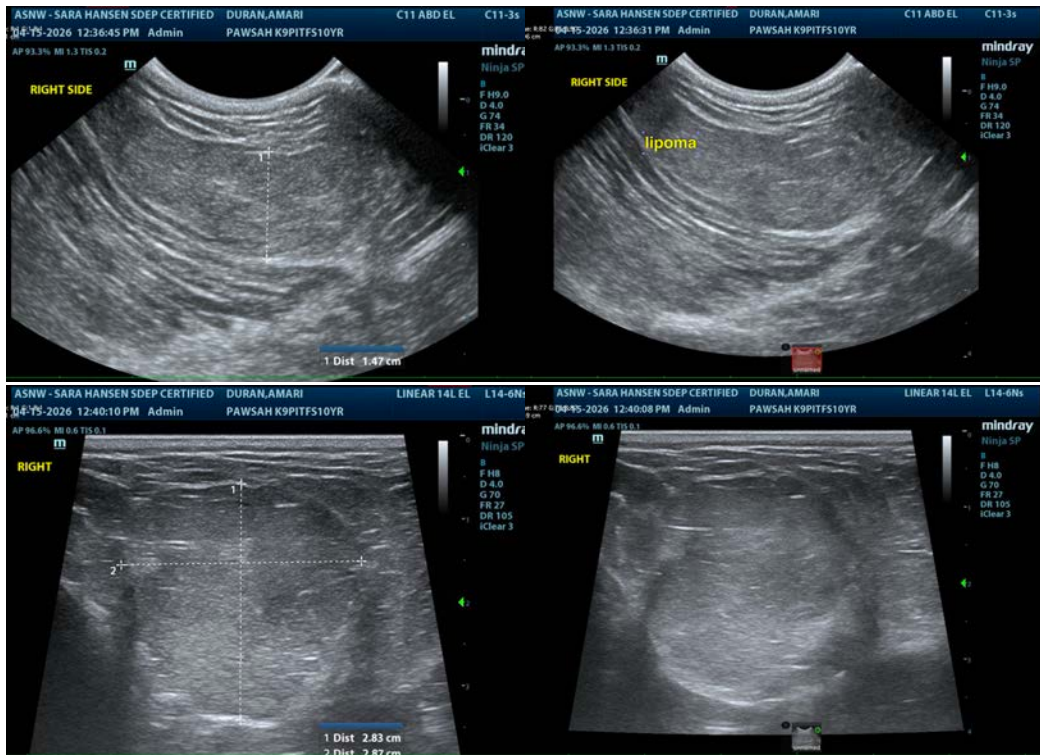
The right side of the thorax in this patient revealed a 2.9 cm isoechoic mass, most consistent with a lipoma. No significant disruption of architecture. The lesion was uniform and isoechoic to surrounding fat.

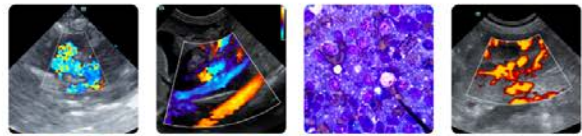
ULTRASONOGRAPHIC FINDINGS

- Body wall lipoma.

INTERPRETATION OF THE FINDINGS & FURTHER RECOMMENDATIONS

No evidence of pathology. FNA could be considered for further definition. Liposarcoma minor potential.





PATIENT

Amari Duran

The information and recommendations provided are based on the images presented by the referring veterinarian/sonographer. No evaluation can be communicated regarding pathology that was not visible in the image/video clips provided.

SPECIES

Canine

Thank you for this referral. If the clinical or image interpretation does not parallel your findings or if I can be of any further assistance please contact me.

BREED

Pit Bull

Eric Lindquist, DMV, DABVP(CFM), Cert. IVUSS,
CEO, Owner, Founder -- SonoPath.com
info@SonoPath.com

SEX

Spayed Female

AGE

10 Years

WEIGHT

63.7 lbs

INTERPRETED BY

Eric Lindquist, DMV,
DABVP (CFM), Cert.
IVUSS

IMAGING PERFORMED BY

Sara Hansen

HOSPITAL NAME

Paws Animal Hospital

REFERRING VET

Dr. Johnson

INVOICE

74475

DATE

4/15/26