

**DATE**

4/15/22

**PRESENTING CLINICAL SIGNS**

History: Blood in urine, first noticed on October 2021.

**PATIENT**

Rufus Dalzell

Current Medications: Baytril in October, currently on Carprofen 75mg BID.

Radiographs: Enlarged prostate.

Date of Previous IntraPet Ultrasound: No previous.

Sedation: Not required to complete full diagnostic ultrasound.

**SPECIES**

Canine

Stat Report: Not requested.

Imaging Performed By: Rachel Brillhart, RDMS.

**BREED**

Borzoi

**ULTRASONOGRAPHIC EXAMINATION OF THE ABDOMEN****SEX**

Intact Male

**Urinary System**

The **urinary bladder**, trigone, and pelvic urethra presented normal thicknesses and normal tone. The ureters were not visible which is normal. No uroliths or sediment were visualized and anechoic urine was present. No evidence of inflammatory or neoplastic changes were noted. Ureteral papillae were normal.

**AGE**

10/28/15

The **prostate** was uniformly enlarged with moderate lobar swelling appeared to impinge upon the urethra and mildly deviate the descending colon. The prostatic tissue was hyperechoic containing focal areas of decreased echogenicity. These changes are suggestive of either chronic inflammatory episodes, benign cystic pathology or both. Underlying neoplasia cannot be completely ruled-out but is lower on the differential list. This presentation is most consistent with benign prostatic hyperplasia with possible active prostatitis. Neutering or off-label Finasteride (Propecia) (0.1-0.5 mg/kg Sid) treatment is indicated +/- FNA or prostatic wash cytology and culture. The largest cyst measured 2.0 cm x 2.0 cm. The prostate measured 5.0 cm in width.

**WEIGHT**

80 Pounds

**INTERPRETED BY**Eric Lindquist, DMV  
DABVP, Cert. IVUSS

The **kidneys** revealed normal size and structure, corticomedullary definition and ratio for this age. The cortices presented largely uniform texture with normal echogenic relationship to liver and spleen. Medullary structure differed distinctly from the cortex and no evidence of pelvic dilation was present. The capsules were acceptably uniform without significant irregularities. The right kidney measured 8.17 cm. The left kidney measured 7.8 cm.

**HOSPITAL NAME**

Madonna VC

**Adrenal Glands**

Both **adrenal glands** were visualized and recognized as having normal shape, size, position and echogenicity for this breed. The phrenic vasculature, glandular echogenicity and detail were unremarkable. Capsule, cortex, and medullary definition were normal for this age patient. The right adrenal gland measured 3.32 cm x 0.64 cm at the caudal pole and 0.78 cm at the cranial pole. The left adrenal gland measured 2.35 cm x 0.84 cm at the caudal pole and 0.83 cm at the cranial pole.

**REFERRING VET**

Dr. Brockett

**Spleen**

The **spleen** presented a smooth homogeneous parenchyma hyperechoic to liver and renal cortical parenchyma. The capsule was smooth without noticeable expansion or deviation from within the spleen or adjacent pathology. The splenic vasculature demonstrated normal volume without signs of congestion or thrombosis. No sonographic evidence of acute or chronic inflammatory, neoplastic, or infarctual changes were noted.

**INVOICE**

14765

**Liver**

The **liver** images submitted revealed subjectively normal liver size, contour, and structure. Parenchymal echogenicity was naturally coarse and hypoechoic to the spleen. Vascular and biliary tracts were of normal volume with no evidence of congestion. The gallbladder presented acceptably thin walls with primarily anechoic content. The cystic and common bile ducts were normal. No pathological hepatic lymphadenopathy was evident. No overt structural evidence of inflammatory, infiltrative or regenerative pathology was evident.

### **Gastrointestinal**

Examination of the **gastrointestinal tract** revealed a stomach and intestine free of stasis, of normal wall thickness, acceptable curvilinear mural detail, and peristaltic activity. Small and large intestine demonstrated normal luminal chyme and stool consistency respectively. No obstructive or overt infiltrative disease was noted. No associated abnormal lymphatic activity was noted.

### **Pancreas**

The base and limbs of the **pancreas** were observed to be largely isoechoic to surrounding omental fat. Pancreatic duct and capsular contour were acceptably normal and parenchyma respected normal curvilinear patterns. No overt evidence of active inflammatory or neoplastic disease was noted.

### **Other**

The **testicles** were imaged and found to be uniform.

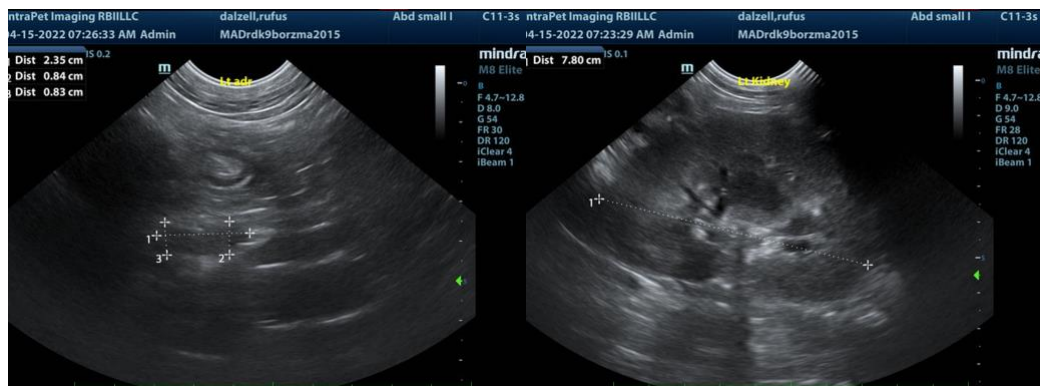
## **ULTRASONOGRAPHIC FINDINGS**

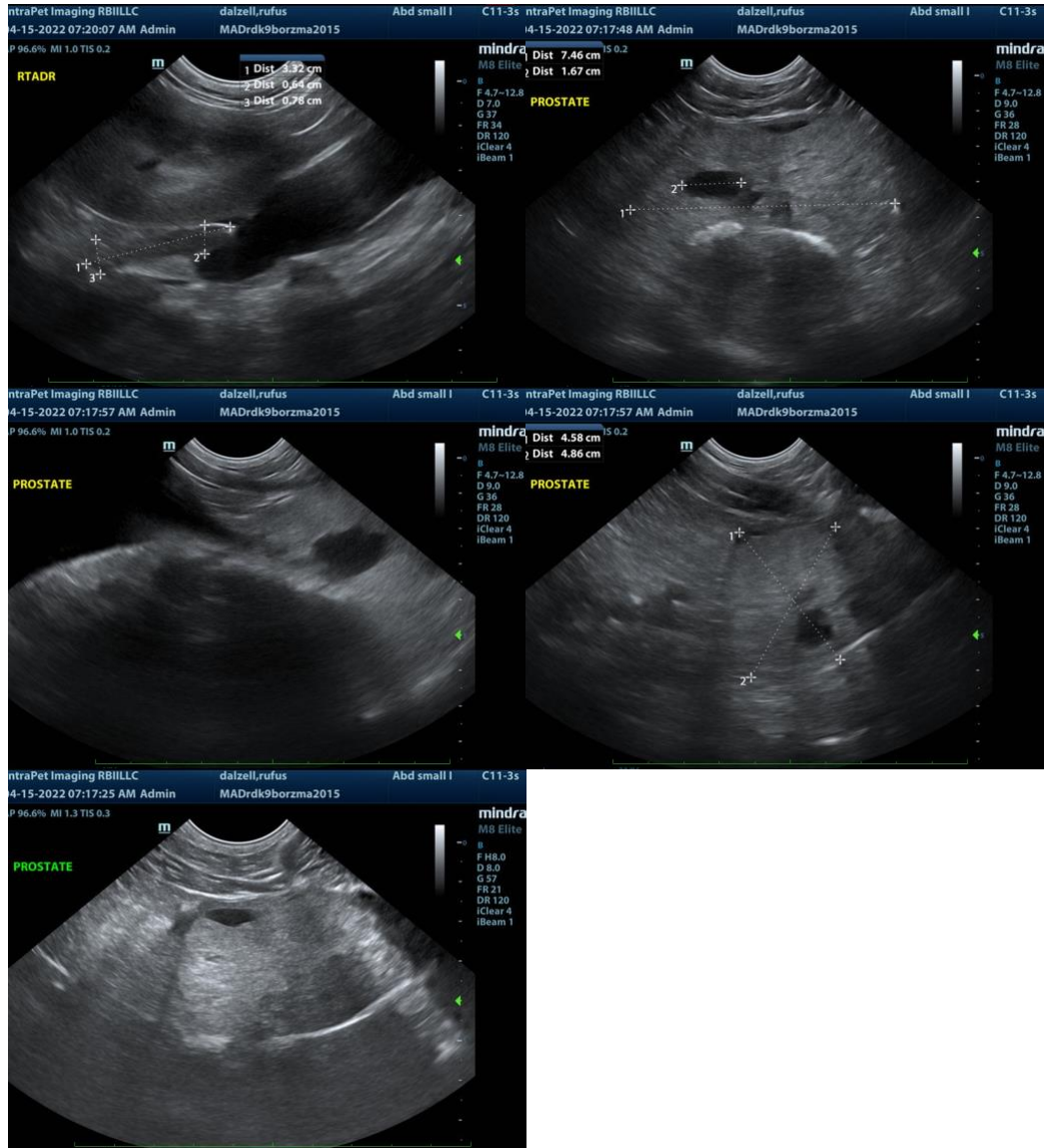
- BPH prostate

## **INTERPRETATION OF THE FINDINGS & FURTHER RECOMMENDATIONS**

Ultrasound guided drainage of the cystic portions and culture to assess for abscessation indicated as well as neuter. If neutering is absolutely not an option, then the following off-label protocol could be considered.

Finasteride at 1 mg/kg/day can be utilized as an off-label approach to reducing prostatic size in BPH cases. Coverage for prostatitis would also likely be appropriate with Fluoroquinolone/Baytril or similar. A recheck sonogram is recommended in 3-4 weeks with reassessment of the urinalysis and evaluation of any inflammatory sediment.





The information and recommendations provided are based on the images presented by the referring veterinarian. No evaluation can be communicated regarding pathology that was not visible in the image/video clips provided.

Thank you for this referral. If the clinical or image interpretation does not parallel your findings or if I can be of any further assistance please contact me.

**Eric Lindquist**, DMV, DABVP, Cert. IVUSS, CEO of SonoPath.com  
 Eric.Lindquist@SonoPath.com