

PATIENT

Daisy Anderson

SPECIES

Canine

BREED

Pomeranian X

SEX

Spayed Female

AGE

12 Years

WEIGHT

15 Pounds

INTERPRETED BY

Eric Lindquist, DMV

DABVP, Cert. IVUSS

IMAGING PERFORMED BY

Dr. Louise Mandeville

HOSPITAL NAME

BetterVet

REFERRING VET

Dr. Louise Mandeville

PRESENTING CLINICAL SIGNS

recurrent UTI. Hx of recurrent UTI due to 1cm bladder polyp cranioventral aspect: removed surgically 2018.

Abnormal PE/Chem/CBC/UA Results: Awaiting UA C&S. Plan to rescan bladder when full and post atbx

LIMITED ULTRASONOGRAPHIC EXAMINATION

The **urinary bladder** presented minor apical dorsal polyps, anechoic urine, and suspended debris. Most consistent with chronic cystitis. Minor micropolypoid changes noted throughout the apex of the bladder. The urethra was not visualized.

ULTRASONOGRAPHIC FINDINGS

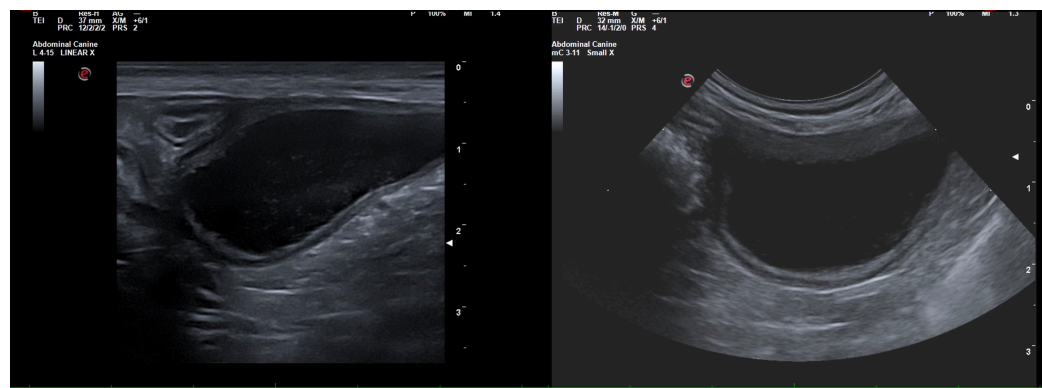
- Chronic cystitis bladder pattern – minimal potential for underlying neoplasia.

INTERPRETATION OF THE FINDINGS & FURTHER RECOMMENDATIONS

Examination of the vaginal vestibule for recessed vulva or urine pooling recommended, which may predisposing to UTI. Cytospin of free catch urine sample could be considered with immediate slide preparation to assess for underlying abnormal transitional cells.

Chronic UTI Protocol

I recommend **Enrofloxacin** (5-10 mg/kg SID PO) (In patients > 1 year of age) in late pm after urination to maximize urinary concentrations overnight. This assumes that culture supports this use. Repeat **culture** at 3-4 weeks and continue treatment at least 7-10 days post negative urinary sediment and negative culture. *Note: Negative culture does not necessarily mean lack of UTI.* Other favorite antibiotics for chronic UTI include third generation Cefa (Ceftiafur or similar s.i.d. injectable) or Clavamox. If suspicion of occult urinary incontinence is present then **phenylpropanolamine (PPA)** (1-2 mg/kg BID) can be employed long term to enhance urethral tone.

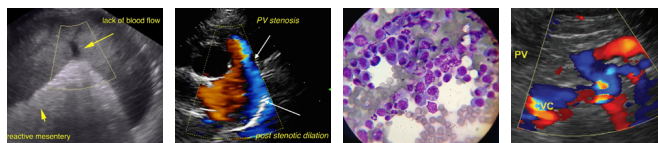


INVOICE

36947

DATE

4/15/22



PATIENT

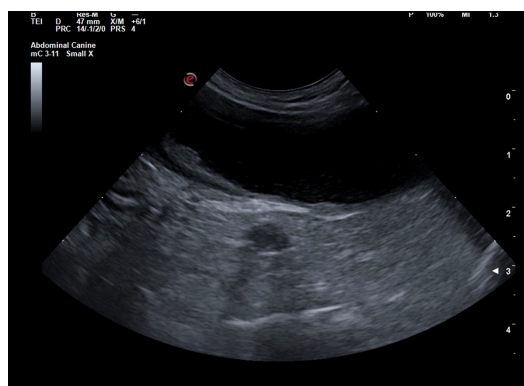
Daisy Anderson

SPECIES

Canine

BREED

Pomeranian X



SEX

Spayed Female

AGE

12 Years

WEIGHT

15 Pounds

INTERPRETED BY

Eric Lindquist, DMV

DABVP, Cert. IVUSS

IMAGING PERFORMED BY

Dr. Louise Mandeville

HOSPITAL NAME

BetterVet

REFERRING VET

Dr. Louise Mandeville

INVOICE

36947

DATE

4/15/22

The information and recommendations provided are based on the images presented by the referring veterinarian/sonographer. No evaluation can be communicated regarding pathology that was not visible in the image/video clips provided.

Thank you for this referral. If the clinical or image interpretation does not parallel your findings or if I can be of any further assistance please contact me.

Eric Lindquist, DMV, DABVP, Cert. IVUSS, CEO of SonoPath.com

info@SonoPath.com