



PATIENT

Lil Bitty Nicolosi

SPECIES

Feline

BREED

DSH

SEX

Spayed Female

AGE

1 Year 10 Months

WEIGHT

7.9 pounds

INTERPRETED BY

Eric Lindquist, DMV,
DABVP(CFM), Cert.
IVUSS

IMAGING PERFORMED BY

Chloe Lowe CVT

HOSPITAL NAME

Rondout Valley
Veterinary Associates

REFERRING VET

Dr. Laux

INVOICE

15109

DATE

04/14/26

PRESENTING CLINICAL SIGNS

VPE's during anesthesia for spay. No arrhythmia or murmur heard at pre op appt. Many VPCs during anesthesia. Had Buprenex, midazolam, and ketamine. Want to make sure no underlying heart disease.

Abnormal PE/Chem/CBC/UA Results: BP 160, 158 Lab work WLN

ULTRASONOGRAPHIC EXAMINATION OF THE HEART

FELINE CARDIAC PARAMETERS	BODY WEIGHT (lbs)	HR (BPM)	IVSd (cm)	LVIDd (cm)	LVWd (cm)	FS (%)	EF (%)
NORMAL PARAMETER	-----	150-240	0.3-0.6	1.0-2.1	0.25-0.6	35-67	80-100
PATIENT	7.9	NM	0.5	1.4	0.5	50	--
FELINE CARDIAC PARAMETERS	LA/AO (M-mode)	LA/AO HEART BASE (Sisson)	LAD LA MAX 4 Chamber	LVOT VEL. (m/s)	RVOT VEL. (m/s)	IVRT (m/)	
NORMAL PARAMETER	<1.5	1.6	0.7-1.7	<1.6	<1.3	40-60	
PATIENT	--	1.38	1.35	1.2	1.0	NM	
Adapted from June Boon, Veterinary Echocardiography, 1998 Sisson D et al. JVIM 1991; 5: 232, Jacobs et al. Am J Vet Res 1985; 46:1705							

E-wave Velocity: 0.9 // EPSS: 0.1

Cardiac Presentation

The echocardiogram in this patient demonstrated normal **left atrial** size based on 3 separate LA measurements. The cranial and caudal **mitral** valve leaflets presented normal linear structure and kinetics. The **left ventricle** presented normal thicknesses with linear contour and was not dilated nor restricted. The **myocardium** presented normal echogenicity without subjective evidence of significant fibrotic or ischemic disease. **Contractility** of the ventricular walls was adequate and in normal range for this patient evidenced by the fractional shortening measurement and subjective evaluation of the different regions and angles of the myocardium. The **left ventricular outflow** tract demonstrated normal laminar flow and subjective structural integrity. The **right atrium** and auricle revealed normal size, structure and content. No evidence of masses was noted or chamber overload. **Tricuspid** valvular assessment demonstrated adequate linear morphology and kinetics. The **right ventricle** was of normal size (1/3 diameter of LV), chordae structure, myocardial echogenicity and thickness. **Pulmonic** tract assessment revealed normal valve structure, laminar flow, and diameter (approx.1:1 pa/ao ratio). No visible **pericardial** or free pleura fluid was noted or extra cardiac pathology in the visible planes. The cranial **mediastinum and pericardial regions** were free of masses in the visible window. The patient was tachycardic at 220.

ULTRASONOGRAPHIC FINDINGS

- Normal echocardiogram with tachycardia.



PATIENT

Lil Bitty Nicolosi

SPECIES

Feline

BREED

DSH

SEX

Spayed Female

AGE

1 Year 10 Months

WEIGHT

7.9 pounds

INTERPRETED BY

Eric Lindquist, DMV,
 DABVP(CFM), Cert.
 IVUSS

IMAGING PERFORMED BY

Chloe Lowe CVT

HOSPITAL NAME

Rondout Valley
 Veterinary Associates

REFERRING VET

Dr. Laux

INVOICE

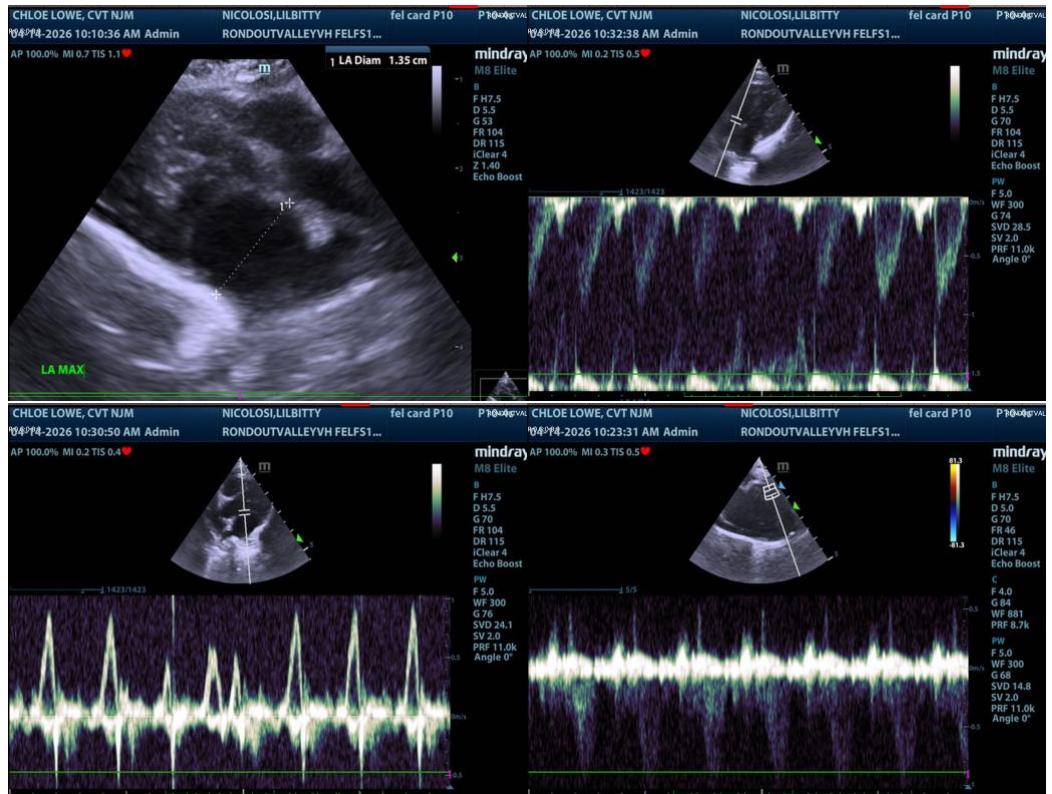
15109

DATE

04/14/26

INTERPRETATION OF THE FINDINGS & FURTHER RECOMMENDATIONS

No structural or functional disease was noted, however, EKG management based on EKG results. Infectious agents should be ruled out as potential underlying issues such as Bartonella, yet structurally and functionally the heart is normal.





PATIENT

Lil Bitty Nicolosi

SPECIES

Feline

BREED

DSH

SEX

Spayed Female

AGE

1 Year 10 Months

WEIGHT

7.9 pounds

INTERPRETED BY

Eric Lindquist, DMV,
 DABVP(CFM), Cert.
 IVUSS

IMAGING PERFORMED BY

Chloe Lowe CVT

HOSPITAL NAME

Rondout Valley
 Veterinary Associates

REFERRING VET

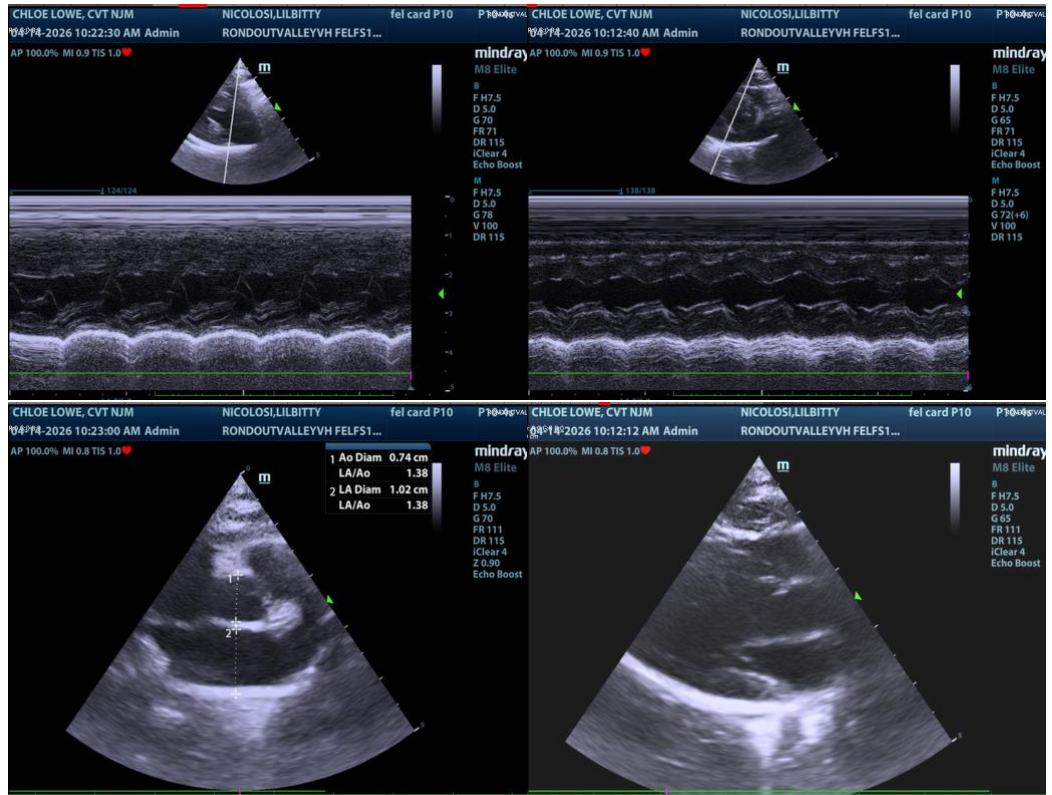
Dr. Laux

INVOICE

15109

DATE

04/14/26



The information and recommendations provided are based on the images presented by the referring veterinarian/sonographer. No evaluation can be communicated regarding pathology that was not visible in the image/video clips provided.

Thank you for this referral. If the clinical or image interpretation does not parallel your findings or if I can be of any further assistance, please contact me.

Eric Lindquist, DMV, DABVP(CFM), Cert. IVUSS,

CEO, Owner, Founder -- SonoPath.com

info@SonoPath.com