



PATIENT

Finn Whitney

SPECIES

Canine

BREED

Terrier Mix

SEX

Neutered Male

AGE

11 Years

WEIGHT

16.4 Pounds

INTERPRETED BY

Eric Lindquist, DMV,
 DABVP (Canine &
 Feline), Cert. IVUSS

IMAGING PERFORMED BY

Ginny Dodd, DVM, D,
 ABVP-CFP

HOSPITAL NAME

Monroe Road AH

REFERRING VET

Dr. Jennifer Jones

INVOICE

36614

DATE

4/14/26

PRESENTING CLINICAL SIGNS

History: Routine yearly exam showed ^ calcium and low USG

Abnormal PE/Chem/CBC/UA Results: BCS 4/9, mm pink, CRT <2 sec, no palpable masses CBC WNL
 CHEM Calcium 13.6, creatine kinase 738 Ionized Ca 1.54 (N< 1.50) TT4 2.3 wnl UA- 1.013, pH 6.0,
 benign sediment.

ULTRASONOGRAPHIC EXAMINATION OF THE ABDOMEN

Urinary System

The **bladder** in this patient was mildly thickened with slight echogenic mural changes. No calculi or masses were noted. A minimal amount of urine was present at the time of the sonogram. Slight micropolypoid changes were noted. This is a frequent finding in older animals and may be linked to a history of chronic urinary tract infection or active urinary tract infection. Urinalysis would be recommended with culture if any evidence of inflammatory sediment is present. The region of the trigone and visible pelvic urethra were normal. This is a mild change. The pelvic urethra was imaged 2.0 cm beyond the cystourethral junction. The residual prostate measured 6.0 mm.

The **kidneys** revealed largely normal size and structure, corticomedullary definition and ratio (cortex 1/3 of medulla) were essentially maintained with some moderate age-related loss of curvilinear patterns regarding the capsule and C/M junction. The cortices presented largely uniform texture with some increased echogenicity expected for this age patient. Medullary structure differed distinctly from that of the cortex, and no evidence of pelvic dilation was present. Slight pinpoint mineralizations were noted. The right kidney measured 4.34 cm. The left kidney measured 4.21 cm.

Adrenal Glands

Both **adrenal glands** were visualized and recognized as having largely normal shape, size, position and acceptable echogenicity for this age group and breed. Some mild heterogeneity was noted within the adrenal parenchyma without concerning capsular distortion. These changes are likely age related but should be monitored by sonogram should the patient be suspected of having adrenal disease. The right adrenal gland measured 2.14 cm x 0.64 cm at the cranial pole and 0.81 cm at the caudal pole. The left adrenal gland measured 2.24 cm x 0.46 cm at the cranial pole and 0.6 cm at the caudal pole.

Spleen

The **spleen** presented a smooth homogeneous parenchyma hyperechoic to liver and renal cortical parenchyma. The capsule was smooth without noticeable expansion or deviation from within the spleen or adjacent pathology. The splenic vasculature demonstrated normal volume without signs of congestion or thrombosis. No sonographic evidence of acute or chronic inflammatory, neoplastic, or infarctual changes were noted.

Liver

The **liver** images from right and left intercostal as well as subcostal views revealed subjectively normal liver size, contour, and structure. Some mild age-related parenchymal remodeling was noted but likely not clinically significant at this time. Vascular and biliary tracts were of normal volume and no evidence of congestion was noted. The gallbladder presented some dependent debris with essentially normal contour. The cystic and common bile ducts were normal. No overt evidence of active inflammatory, infiltrative or regenerative pathology was noted but should be paired with current or past LE



PATIENT

Finn Whitney

SPECIES

Canine

BREED

Terrier Mix

SEX

Neutered Male

AGE

11 Years

WEIGHT

16.4 Pounds

INTERPRETED BY

Eric Lindquist, DMV,
 DABVP (Canine &
 Feline), Cert. IVUSS

IMAGING PERFORMED BY

Ginny Dodd, DVM, D,
 ABVP-CFP

HOSPITAL NAME

Monroe Road AH

REFERRING VET

Dr. Jennifer Jones

INVOICE

36614

DATE

4/14/26

elevations regarding any clinical significance to this presentation. The hepatic lymph nodes were unremarkable.

Gastrointestinal

Examination of the **gastrointestinal tract** revealed a stomach and intestine free of stasis, of normal wall thickness, acceptable curvilinear mural detail, and peristaltic activity. Small and large intestine demonstrated normal luminal chyme and stool consistency respectively. No obstructive or overt infiltrative disease was noted. No associated abnormal lymphatic activity was noted.

Pancreas

The base and limbs of the **pancreas** were observed to be largely isoechoic to surrounding omental fat. Pancreatic duct and capsular contour were acceptably normal and parenchyma respected normal curvilinear patterns. No overt evidence of active inflammatory or neoplastic disease was noted.

Other

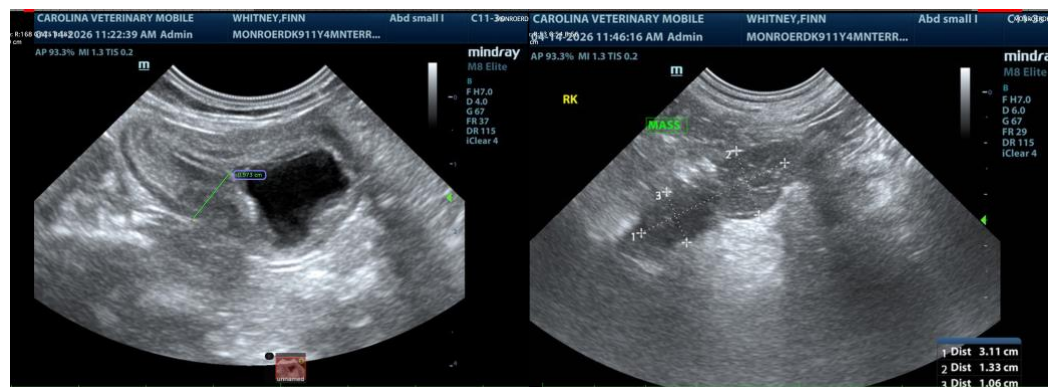
Caudal to the right kidney, a hypoechoic irregular **tissue density** was noted, which appears to be potentially deriving from the lumbar vertebrae. The lesion measured 5.0 cm x 2.6 cm.

ULTRASONOGRAPHIC FINDINGS

- Geriatric abdomen
- Undefined lesion caudal to the right kidney, possible deriving from vertebrae
- Age-related renal changes with slight pinpoint mineralizations

INTERPRETATION OF THE FINDINGS & FURTHER RECOMMENDATIONS

Abdominal radiographs or CT may be better able to visualize the extent of this lesion. Ultrasound guided FNA maybe possible, however, may be difficult to access. Assessment for any vertebral lesion particularly lytic lesions recommended on radiographs.





PATIENT

Finn Whitney

SPECIES

Canine

BREED

Terrier Mix

SEX

Neutered Male

AGE

11 Years

WEIGHT

16.4 Pounds

INTERPRETED BY

Eric Lindquist, DMV,
 DABVP (Canine &
 Feline), Cert. IVUSS

IMAGING PERFORMED BY

Ginny Dodd, DVM, D,
 ABVP-CFP

HOSPITAL NAME

Monroe Road AH

REFERRING VET

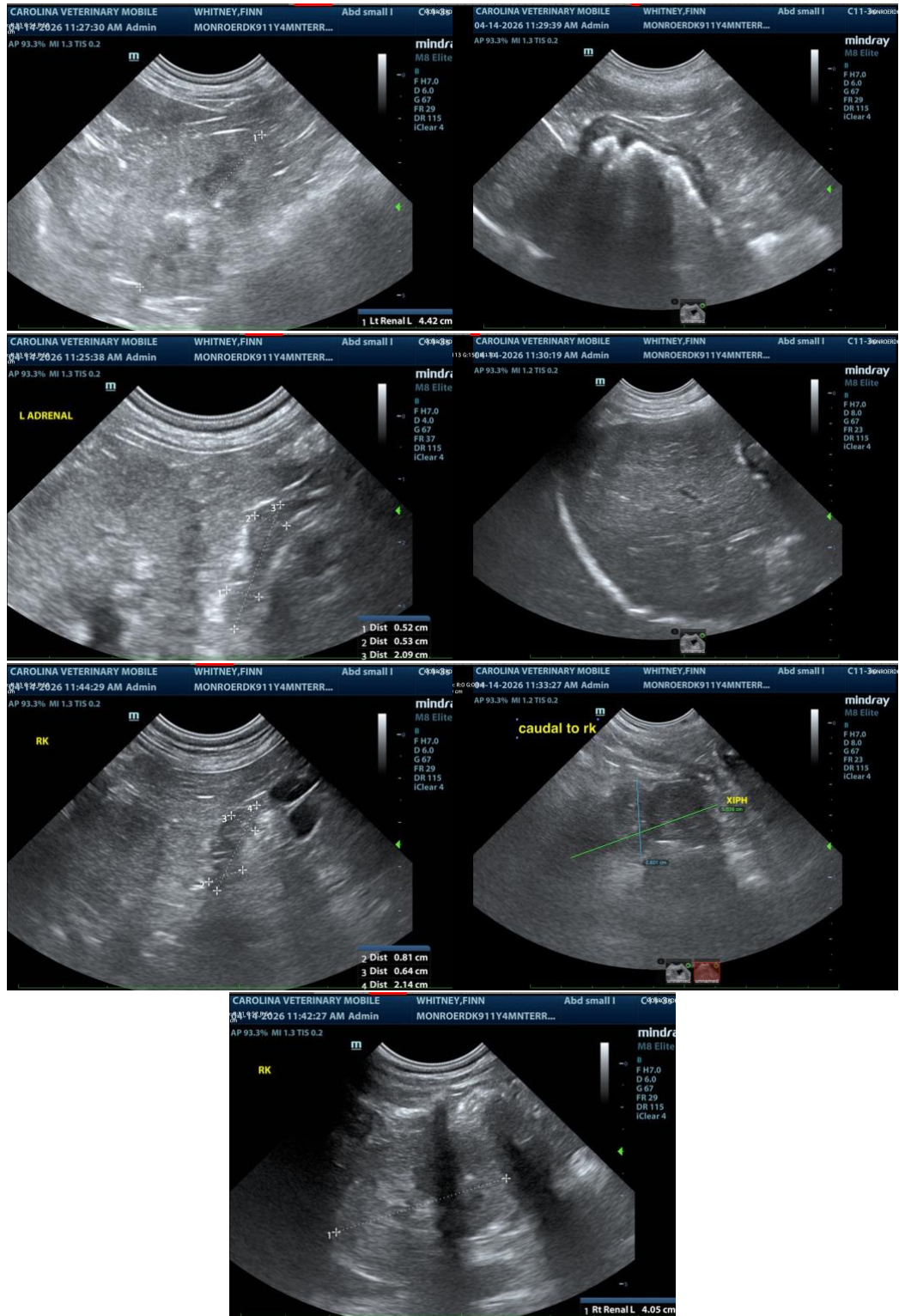
Dr. Jennifer Jones

INVOICE

36614

DATE

4/14/26





PATIENT

Finn Whitney

The information and recommendations provided are based on the images presented by the referring veterinarian/sonographer. No evaluation can be communicated regarding pathology that was not visible in the image/video clips provided.

SPECIES

Canine

Thank you for this referral. If the clinical or image interpretation does not parallel your findings or if I can be of any further assistance please contact me.

Eric Lindquist, DMV, DABVP, Cert. IVUSS, CEO of SonoPath.com

BREED

Terrier Mix

info@SonoPath.com

CANINE HYPERCALCEMIA

SEX

Neutered Male

<http://www.sonopath.com/CanineHypercalcemia>

AGE

11 Years

Description: Hypercalcemia is defined as either a persistently elevated total calcium serum (> 12 mg/dl) or ionized calcium (> 1.45 mmol/l) concentration. Clinical signs are often absent with mild hypercalcemia (< 13 mg/dl). In fact, hypercalcemia is often only discovered when serum biochemistry is done for unrelated reasons. Clinical signs are usually mild when the serum calcium concentration is less than 14 mg/dl; however, signs become more readily apparent when the concentration exceeds 15 mg/dl. Life-threatening cardiac arrhythmias can develop when the serum calcium exceeds 18 mg/dl.

WEIGHT

16.4 Pounds

INTERPRETED BY

Eric Lindquist, DMV,
DABVP (Canine &
Feline), Cert. IVUSS

Common etiologies of hypercalcemia include humoral hypercalcemia of malignancy (HHM), hypoadrenocorticism, chronic kidney disease (CKD), hypervitaminosis D, and primary hyperparathyroidism. Less common etiologies include bone neoplasia, osteomyelitis, hypertrophic osteodystrophy, granulomatous disease, calcium supplementation, and oral phosphate binders.

IMAGING PERFORMED BY

Ginny Dodd, DVM, D,
ABVP-CFP

Clinical Signs: Common clinical signs include polyuria, polydipsia, lethargy, inappetence, and weakness. With chronic hypercalcemia, calcium oxalate and calcium phosphate uroliths can form, resulting in clinical signs suggestive of lower urinary tract disease. Systemic signs of illness are suggestive of HHM.

HOSPITAL NAME

Monroe Road AH

REFERRING VET

Dr. Jennifer Jones

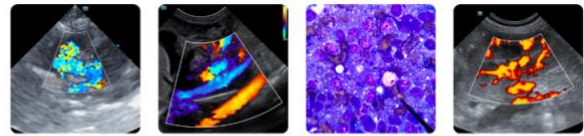
Diagnostics: One important etiology of hypercalcemia is laboratory error; therefore, hypercalcemia should always be confirmed before embarking on any further diagnostic evaluation. Results of a CBC, serum biochemistry panel, and urinalysis, in conjunction with a patient history and findings from a physical examination, can often provide enough information to arrive at a diagnosis. The appendicular skeleton, peripheral lymph nodes, abdominal cavity, and rectum should all be carefully palpated for masses, lymphadenopathy, hepatomegaly, splenomegaly, and/or pain in the long bones. The following diagnostic tests are helpful for identifying an underlying malignancy: thoracic and abdominal radiographs; abdominal ultrasound; cytological evaluation of aspirates of the liver, spleen, lymph nodes, and bone marrow; determination of serum ionized calcium, parathyroid hormone (PTH), and parathyroid hormone-related

INVOICE

36614

DATE

4/14/26



PATIENT

Finn Whitney

SPECIES

Canine

BREED

Terrier Mix

SEX

Neutered Male

AGE

11 Years

WEIGHT

16.4 Pounds

INTERPRETED BY

Eric Lindquist, DMV,
 DABVP (Canine &
 Feline), Cert. IVUSS

IMAGING PERFORMED BY

Ginny Dodd, DVM, D,
 ABVP-CFP

HOSPITAL NAME

Monroe Road AH

REFERRING VET

Dr. Jennifer Jones

INVOICE

36614

DATE

4/14/26

protein concentration (PTHrP); and ultrasound of the neck. Ascertaining the concentrations of serum ionized calcium, PTH, and PTHrP helps differentiate primary hyperparathyroidism from HHM. The finding of one or more enlarged parathyroid glands upon conducting an ultrasound of the neck supports a diagnosis of primary hyperparathyroidism.

Hypoadrenocorticism-induced hypercalcemia usually occurs in conjunction with hyponatremia, hyperkalemia, and prerenal azotemia. With HHM and primary hyperparathyroidism, serum phosphorus concentration is often in the low to low-normal reference range. If the serum phosphorus concentration is high but kidney function is normal, hypervitaminosis D or osteolysis should be suspected.

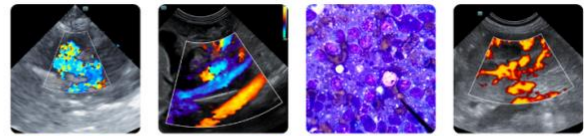
It can be difficult to determine whether kidney failure is primary or secondary to hypercalcemia when hyperphosphatemia and hypercalcemia coexist with azotemia. Serum ionized calcium concentrations are typically normal or decreased in cases of renal failure and increased in cases of hypercalcemia caused by other disorders.

Sternal and hilar lymphadenopathy is common with lymphoma-induced hypercalcemia and can be readily identified on thoracic radiographs. In cases of multiple myeloma, discrete lytic lesions in the vertebrae or long bones, hyperproteinemia, proteinuria, and plasma cell infiltration in the bone marrow may be present. Cytological evaluation of the peripheral lymph nodes, bone marrow, and spleen can be helpful in identifying lymphoma.

Increased serum ionized calcium concentrations, detectable serum PTHrP concentrations, and non-detectable serum PTH concentrations are all diagnostic for HHM. Lymphoma is the most common etiology of HHM, but other tumors, such as apocrine gland adenocarcinoma and various carcinomas (e.g. mammary gland, squamous cell, bronchogenic), can all give rise to hypercalcemia. Increased serum ionized calcium, normal to increased serum PTH, and non-detectable PTHrP concentrations are diagnostic of primary hyperparathyroidism.

Differentials for Hypercalcemia: "HARD IONS"

- Hyperparathyroid
- Addison's
- Renal
- D-toxicity



PATIENT

Idiopathic

Finn Whitney

Osteolytic

SPECIES

Neoplastic

Canine

Spurious

BREED

Terrier Mix

PTH tumor: Elevated total and ionized Ca, low PTHrP, and normal/high PTH. Keeshonds, German Shepherds, and Golden Retrievers are all predisposed.

SEX

Neutered Male

Addison's disease: Elevated total and normal ionized Ca, elevated BUN, hypoalbuminemia and hyperkalemia.

AGE

11 Years

Renal failure: Elevated to normal total Ca, low ionized Ca, low PTHrP, elevated PTH, azotemia, and low urine specific gravity.

Vitamin D toxicity: Elevated total and ionized Ca, low PTHrP, and normal/low PTH.

WEIGHT

16.4 Pounds

Hypercalcemia of malignancy (HHM): Elevated total and ionized Ca, high PTHrP, and low PTH.

Granulomatous disease: Elevated total and ionized Ca, low PTHrP, and low PTH.

INTERPRETED BY

Eric Lindquist, DMV,
 DABVP (Canine &
 Feline), Cert. IVUSS

Renal failure: Elevated to normal total Ca, low ionized Ca, low PTHrP, elevated PTH, azotemia, and low urine specific gravity.

IMAGING PERFORMED BY

Ginny Dodd, DVM, D,
 ABVP-CFP

Treatment: Therapies for hypercalcemia are aimed at correcting the underlying etiology; however, because prolonged hypercalcemia can result in kidney damage, the use of fluid therapy, furosemide, and possibly prednisone is indicated in all cases to reduce serum calcium levels. Suggested dosages include saline (0.9% 120-180 ml/kg day IV), furosemide (1-4 mg/kg PO TID), and prednisone (0.25 mg/kg PO Q24hr).

HOSPITAL NAME

Monroe Road AH

References:

REFERRING VET

Dr. Jennifer Jones

Chew DJ, Schenck PA, Jaege JQ. Clinical disorders of hypercalcemia and hypocalcemia in dogs and cats. Proceedings from the American College of Veterinary Internal Medicine, Charlotte, NC, June 4-7, 2003.

Feldman EC. Disorders of the parathyroid glands. In: Ettinger SJ, Feldman EC, ed. *Textbook of Veterinary Internal Medicine, 7th ed.* St. Louis, MO: Saunders Elsevier; 2010:1722-50.

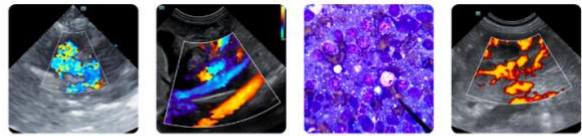
INVOICE

36614

DATE

4/14/26

Peterson ME. Hypercalcemia in dogs & cats: differential diagnosis & treatment. Proceedings from the Western Veterinary Conference, Las Vegas, NV, February 19-23, 2012.



PATIENT

Finn Whitney

SPECIES

Canine

BREED

Terrier Mix

SEX

Neutered Male

AGE

11 Years

WEIGHT

16.4 Pounds

INTERPRETED BY

Eric Lindquist, DMV,
DABVP (Canine &
Feline), Cert. IVUSS

**IMAGING
PERFORMED BY**

Ginny Dodd, DVM, D,
ABVP-CFP

HOSPITAL NAME

Monroe Road AH

REFERRING VET

Dr. Jennifer Jones

INVOICE

36614

DATE

4/14/26