



PATIENT

Cali Benson

SPECIES

Canine

BREED

Boxer

SEX

Spayed Female

AGE

10 Years 8 Months

WEIGHT

72.4 pounds

INTERPRETED BY

Eric Lindquist, DMV,
DABVP(CFM), Cert.
IVUSS

IMAGING PERFORMED BY

Dr. Cecelia Fisher

HOSPITAL NAME

Cape Coral Pet Vet

REFERRING VET

Dr. Cecelia Fisher

INVOICE

15097

DATE

04/14/26

PRESENTING CLINICAL SIGNS

Not eating.

ULTRASONOGRAPHIC EXAMINATION OF THE ABDOMEN

Urinary System

The **urinary bladder**, trigone, and pelvic urethra presented normal thicknesses and normal tone. The ureters were not visible which is normal. No uroliths or sediment were visualized, and anechoic urine was present. No evidence of inflammatory or neoplastic changes were noted. Ureteral papillae were normal.

The **kidneys** revealed normal size and structure, corticomedullary definition and ratio for this age. The cortices presented largely uniform texture with normal echogenic relationship to liver and spleen. Medullary structure differed distinctly from the cortex and no evidence of pelvic dilation was present. The capsules were acceptably uniform without significant irregularities. The left kidney measured 5.5 cm in length. The right kidney measured 6.8 cm in length.

Adrenal Glands

The **left adrenal gland** was slightly subnormal in size measuring 0.34 cm width, The **right adrenal gland** was at the low end of normal in size measuring 0.60 cm width. Both adrenal glands were visualized obliquely.

Spleen

The **spleen** presented a smooth homogeneous parenchyma hyperechoic to liver and renal cortical parenchyma. The capsule was smooth without noticeable expansion or deviation from within the spleen or adjacent pathology. The splenic vasculature demonstrated normal volume without signs of congestion or thrombosis. No sonographic evidence of acute or chronic inflammatory, neoplastic, or infarctual changes were noted. The spleen was folded upon itself.

Liver

The **liver** images submitted revealed subjectively normal liver size, contour, and structure. Parenchymal echogenicity was naturally coarse and hypoechoic to the spleen. Vascular and biliary tracts were of normal volume with no evidence of congestion. The gallbladder presented acceptably thin walls with primarily anechoic content. The cystic and common bile ducts were normal. No pathological hepatic lymphadenopathy was evident. No overt structural evidence of inflammatory, infiltrative or regenerative pathology was evident.

Gastrointestinal

Examination of the **gastrointestinal tract** revealed a stomach and intestine free of stasis, of normal wall thickness, acceptable curvilinear mural detail, and peristaltic activity. Small and large intestine demonstrated normal luminal chyme and stool consistency respectively. No obstructive or overt infiltrative disease was noted. No associated abnormal lymphatic activity was noted.

Pancreas



PATIENT

Cali Benson

SPECIES

Canine

BREED

Boxer

SEX

Spayed Female

AGE

10 Years 8 Months

WEIGHT

72.4 pounds

INTERPRETED BY

Eric Lindquist, DMV,
DABVP(CFM), Cert.
IVUSS

IMAGING PERFORMED BY

Dr. Cecelia Fisher

HOSPITAL NAME

Cape Coral Pet Vet

REFERRING VET

Dr. Cecelia Fisher

INVOICE

15097

DATE

04/14/26

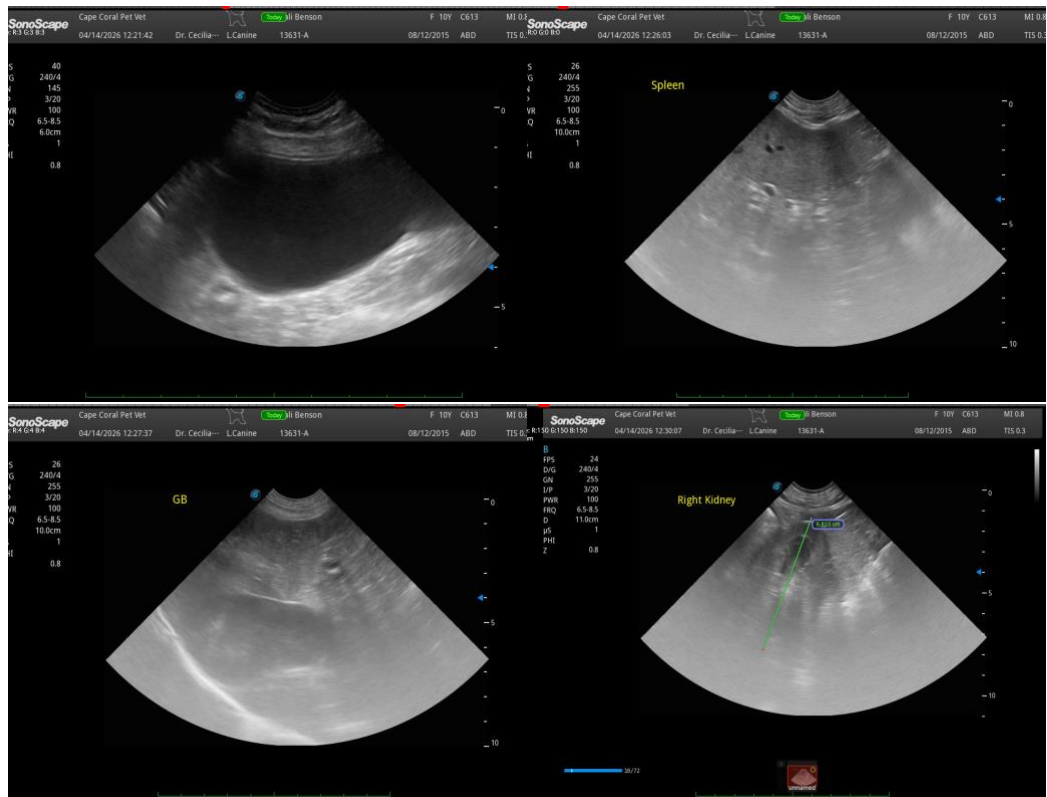
The base and limbs of the **pancreas** were observed to be largely isoechoic to surrounding omental fat. Pancreatic duct and capsular contour were acceptably normal and parenchyma respected normal curvilinear patterns. No overt evidence of active inflammatory or neoplastic disease was noted.

ULTRASONOGRAPHIC FINDINGS

- Structurally unremarkable abdomen.

INTERPRETATION OF THE FINDINGS & FURTHER RECOMMENDATIONS

No evidence of gross pathology. Other causes of anorexia such as thoracic/cardiac disease, arrhythmogenic disease, orthopedic pain, CNS disease should all be ruled out. Screening for Addison's is indicated given the subjectively subnormal adrenal gland size.





PATIENT

Cali Benson

SPECIES

Canine

BREED

Boxer

SEX

Spayed Female

AGE

10 Years 8 Months

WEIGHT

72.4 pounds

INTERPRETED BY

Eric Lindquist, DMV,
DABVP(CFM), Cert.
IVUSS

IMAGING PERFORMED BY

Dr. Cecelia Fisher

HOSPITAL NAME

Cape Coral Pet Vet

REFERRING VET

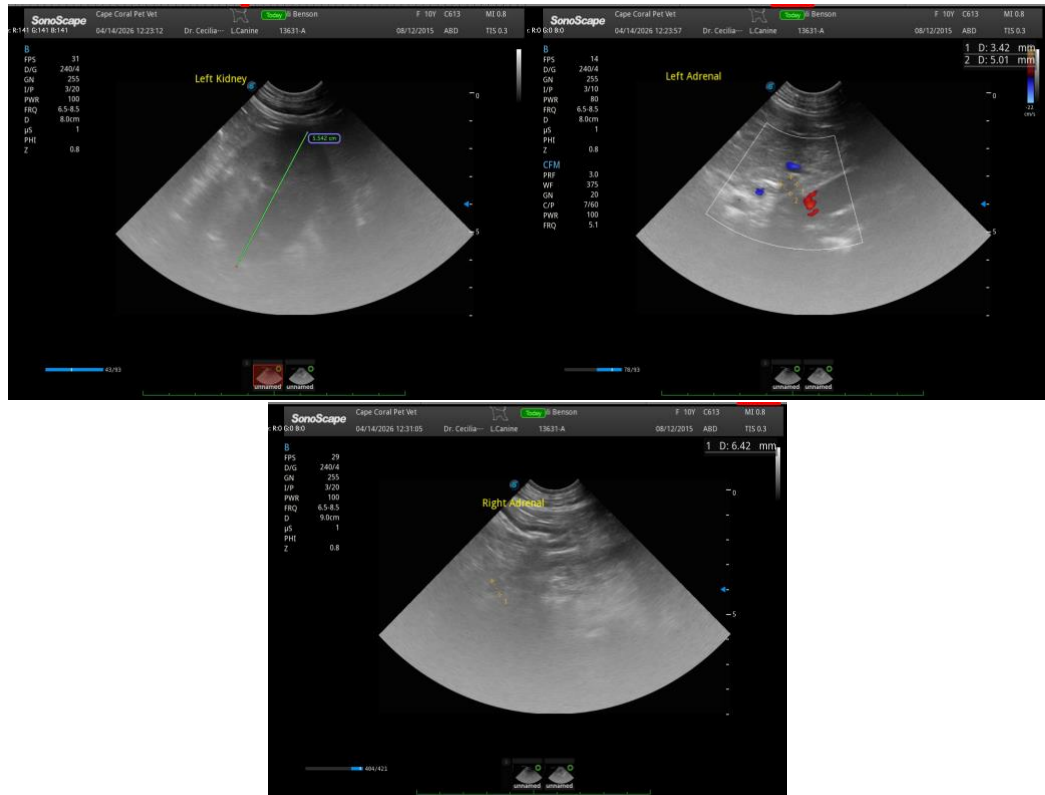Dr. Cecelia Fisher

INVOICE

15097

DATE

04/14/26



The information and recommendations provided are based on the images presented by the referring veterinarian/sonographer. No evaluation can be communicated regarding pathology that was not visible in the image/video clips provided.

Thank you for this referral. If the clinical or image interpretation does not parallel your findings or if I can be of any further assistance, please contact me.

Eric Lindquist, DMV, DABVP(CFM), Cert. IVUSS,

CEO, Owner, Founder -- SonoPath.com

info@SonoPath.com