



DATE	PRESENTING CLINICAL SIGNS
4/14/23	History: 1.5 weeks ago - Monday ADR- odd, stared off into space then improved. Wednesday vomited once. Intermittently standing painful then wnl. --> Improved with rDVM treatment. Then last night acutely vomited, off, concern flare up of pancreatitis. On presentation started to have some trouble breathing History: - 2 yrs ago alopecia X- Cushings negative, T4, Other testing--> Put on melatonin - Recently changed to wellactin - Small liver; no shunt ever found, bile acids fluxuate 40 to 90 (unsure if biopsy) - On denamarin, lactulose (recently increased dose) - 3-4 weeks ago had full labs, liver values little high (hx of this) - 1 week ago Chadwell- no repeat labwork, xrays concern for pancreatitis- Treated cerenia, Rx cerenia + proviable.
PATIENT	
Tucker Anderson	
SPECIES	
Canine	Current Medications: Cerenia, Buprenorphine.
BREED	Lab Results: See attached.
Papillon	Radiographs: Hypovolemia, no visible mets. Hazy cranial abdomen, no distinct masses.
SEX	Date of Previous IntraPet Ultrasound: No previous.
Neutered Male	Sedation: Not required to complete full diagnostic ultrasound.
AGE	Stat Report: STAT requested.
8/1/14	Imaging Performed By: Rachel Brillhart, RDMS.
WEIGHT	
14.2 Pounds	
INTERPRETED BY	
Eric Lindquist, DMV DABVP, Cert. IVUSS	
HOSPITAL NAME	
Animal Emergency Hospital	
REFERRING VET	
Dr. King	
INVOICE	
21971	

ULTRASONOGRAPHIC EXAMINATION OF THE ABDOMEN

Urinary System

The **urinary bladder**, trigone, and pelvic urethra presented normal thicknesses and normal tone. The ureters were not visible which is normal. No uroliths or sediment were visualized and anechoic urine was present. No evidence of inflammatory or neoplastic changes were noted. Ureteral papillae were normal.

The **kidneys** revealed largely normal size and structure, corticomedullary definition and ratio (cortex 1/3 of medulla) were essentially maintained with some mild age-related loss of curvilinear patterns regarding the capsule and C/M junction. The cortices presented largely uniform texture with some increased echogenicity expected for his age patient. Medullary structure differed distinctly from that of the cortex and no evidence of pelvic dilation was present. Mineralization (up to 0.26 cm) was present in the kidneys. The right kidney measured 4.4 cm. The left kidney measured 4.02 cm. Pinpoint mineralizations were noted.

Adrenal Glands

Both **adrenal glands** were visualized and recognized as having normal shape, size, position and echogenicity for this breed. The phrenic vasculature, glandular echogenicity and detail were unremarkable. Capsule, cortex, and medullary definition were normal for this age patient. The right adrenal gland measured 2.05 cm x 0.68 cm at the cranial pole and 0.59 cm at the caudal pole. The left adrenal gland measured 2.18 cm x 0.77 cm at the caudal pole and 0.58 cm at the cranial pole.

Spleen

The **spleen** revealed a 1.8 cm mass.

Liver

The **liver** was swollen with increased portal markings. Nodular changes were noted throughout the liver. The gallbladder and common bile duct were unremarkable.

Gastrointestinal

The **gastrointestinal tract** was largely unremarkable yet surrounded by reactive omentum.

Pancreas

The base and limbs of the **pancreas** were observed to be largely isoechoic to surrounding omental fat. Pancreatic duct and capsular contour were acceptably normal and parenchyma respected normal curvilinear patterns. No overt evidence of active inflammatory or neoplastic disease was noted.

Free Abdomen

Free fluid was noted throughout the abdomen, suggestive for hemorrhage or paraneoplastic effusion. A second mass was noted in the left cranial abdomen, presumed to be splenic or pancreatic origin.

Other

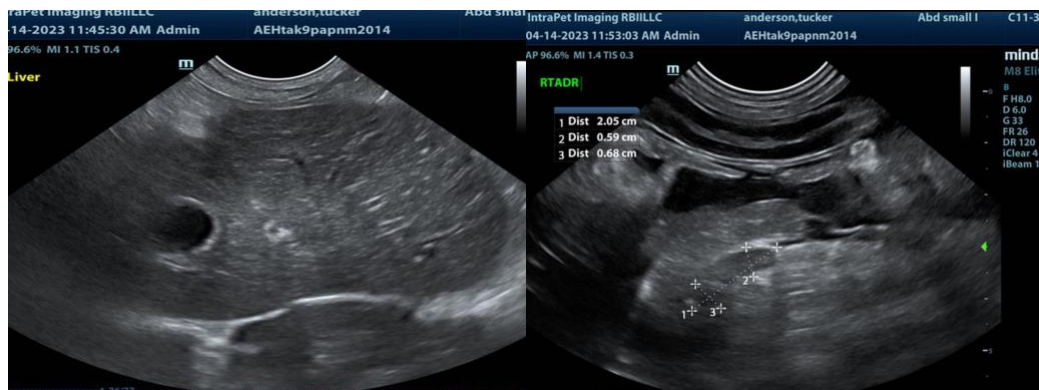
A rapid view of the **heart** revealed no evident pathology other than volume contraction. The right auricle was free of evident pathology.

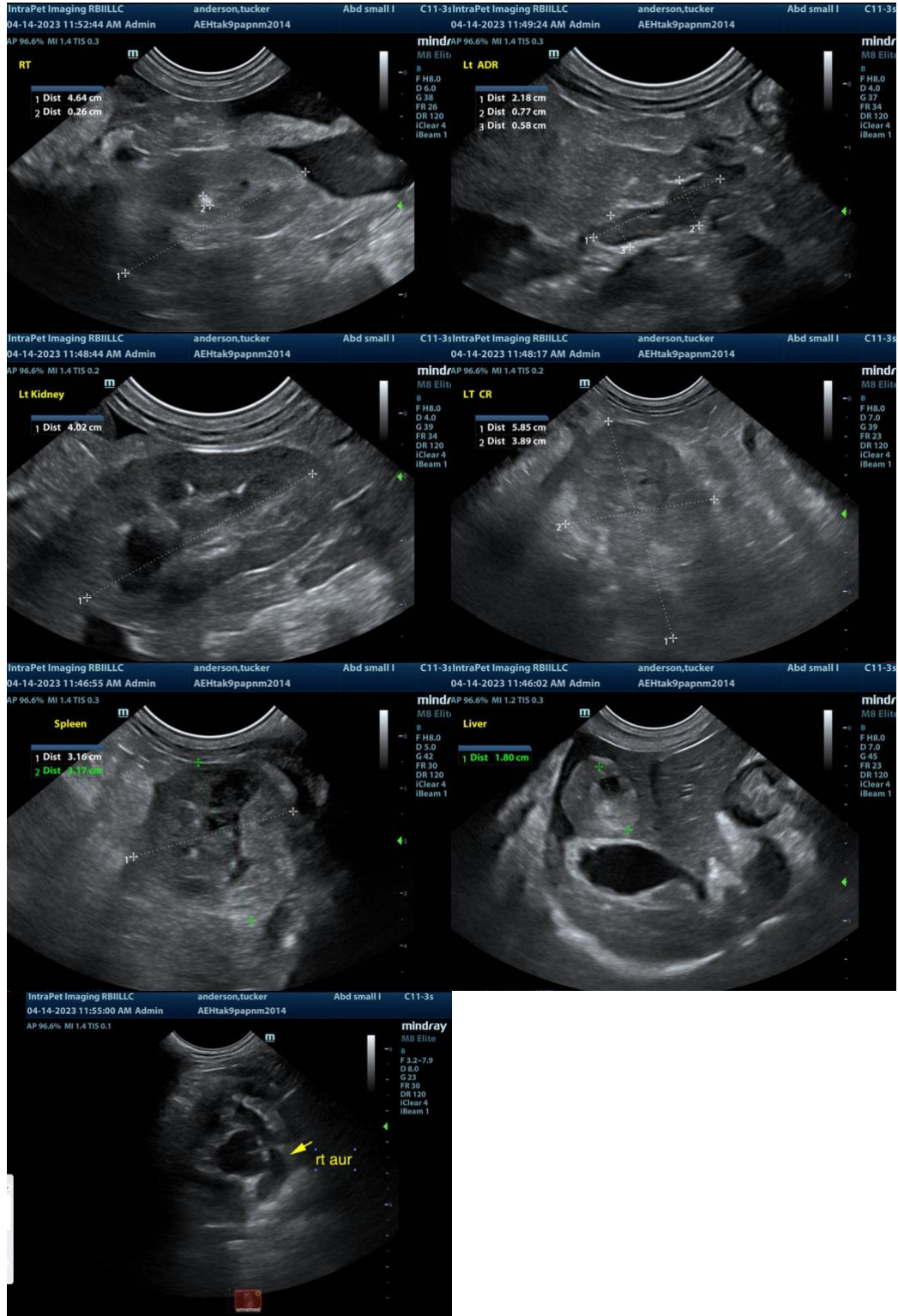
ULTRASONOGRAPHIC FINDINGS

- Multicentric neoplasia of the spleen, probable pancreas and liver with paraneoplastic effusion or hemorrhage
- Volume contracted heart
- Age-related renal changes with mineralization
- GI tract was surrounded by reactive omentum

INTERPRETATION OF THE FINDINGS & FURTHER RECOMMENDATIONS

Abdominocentesis, 25-gauge FNA of the splenic and cranial abdominal mass, as well as liver lesions are all indicated.





The information and recommendations provided are based on the images presented by the

referring veterinarian. No evaluation can be communicated regarding pathology that was not visible in the image/video clips provided.

Thank you for this referral. If the clinical or image interpretation does not parallel your findings or if I can be of any further assistance please contact me.

Eric Lindquist, DMV, DABVP, Cert. IVUSS, CEO of SonoPath.com
info@SonoPath.com