SonoPath
Clinical Sonography & Telecytology
EDUCATIONAL TELECONSULTATION SERVICES™

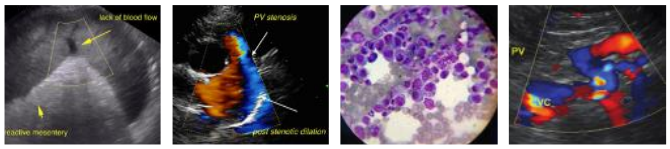

SonoPath.com
1-800-838-4268 info@sonopath.com

PATIENT
Sophie Windsor

SPECIES
Canine

BREED
Chihuahua

SEX
Spayed Female

AGE
12 Years

WEIGHT
4.38 kg

INTERPRETED BY
Eric Lindquist, DMV
DABVP, Cert. IVUSS

IMAGING PERFORMED BY
Dr. Colborne

HOSPITAL NAME
Neighbourhood VH

REFERRING VET
Dr. Colborne

INVOICE
21989

DATE
4/14/23

PRESENTING CLINICAL SIGNS

Chronic intermittent vomiting and decreased appetite for the last month. Vomiting seems to happen early morning and is just bile. Tried to feed smaller more frequent meals on suspicion of bilious vomiting syndrome which was unsuccessful due to intermittently decreased appetite. Usually a ravenous appetite. Has responded well to cerenia with normal appetite and energy and no vomiting.

Abnormal PE/Chem/CBC/UA Results: Mild hypokalemia and mild elevation in ALT. No other abnormal findings on bloodwork and UA. Abdominal x-rays unremarkable.

ULTRASONOGRAPHIC EXAMINATION OF THE ABDOMEN

Urinary System

The **urinary bladder**, trigone, and pelvic urethra presented normal thicknesses and normal tone. The ureters were not visible which is normal. No uroliths or sediment were visualized and anechoic urine was present. No evidence of inflammatory or neoplastic changes were noted. Ureteral papillae were normal.

The **kidneys** revealed largely normal size and structure, corticomedullary definition and ratio (cortex 1/3 of medulla) were essentially maintained with some moderate age-related loss of curvilinear patterns regarding the capsule and C/M junction. The cortices presented largely uniform texture with some increased echogenicity expected for his age patient. Medullary structure differed distinctly from that of the cortex and no evidence of pelvic dilation was present. The right kidney measured 3.61 cm. Pinpoint mineralizations were noted. The left kidney measured 3.54 cm.

Adrenal Glands

Both **adrenal glands** were visualized and recognized as having largely normal shape, size, position and acceptable echogenicity for this age group and breed. Some heterogeneity was noted within the adrenal parenchyma without concerning capsular distortion. These changes are likely age related but should be monitored by sonogram should the patient be suspected of having adrenal disease. The right adrenal gland measured 0.6 cm at the cranial pole and 0.56 cm at the caudal pole. The left adrenal gland measured 0.51 cm at the caudal pole and 0.42 cm at the cranial pole.

Spleen

The **spleen** presented a smooth homogeneous parenchyma hyperechoic to liver and renal cortical parenchyma. The capsule was smooth without noticeable expansion or deviation from within the spleen or adjacent pathology. The splenic vasculature demonstrated normal volume without signs of congestion or thrombosis. No sonographic evidence of acute or chronic inflammatory, neoplastic, or infarctual changes were noted.

Liver

The **liver** images from right and left intercostal as well as subcostal views revealed subjectively normal liver size, contour, and structure. Some mild age-related parenchymal remodeling was noted but likely not clinically significant at this time. Vascular and biliary tracts were of normal volume and no evidence of congestion was noted. The gallbladder presented some dependent debris with essentially normal contour. The cystic and common bile ducts were normal. No overt evidence of active inflammatory, infiltrative or regenerative pathology was noted but should be paired with current or

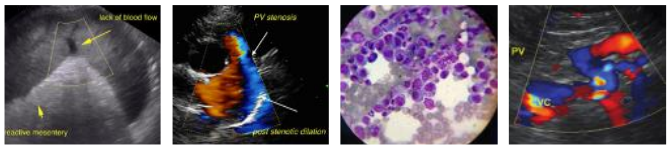

SonoPath.com
1-800-838-4268 info@sonopath.com

PATIENT

Sophie Windsor

SPECIES

Canine

BREED

Chihuahua

SEX

Spayed Female

AGE

12 Years

WEIGHT

4.38 kg

INTERPRETED BY

Eric Lindquist, DMV

DABVP, Cert. IVUSS

IMAGING PERFORMED BY

Dr. Colborne

HOSPITAL NAME

Neighbourhood VH

REFERRING VET

Dr. Colborne

INVOICE

21989

DATE

4/14/23

past LE elevations regarding any clinical significance to this presentation. The hepatic lymph nodes were unremarkable.

Gastrointestinal

Examination of the **gastrointestinal tract** revealed a stomach and intestine free of stasis, of normal wall thickness, acceptable curvilinear mural detail, and peristaltic activity. Small and large intestine demonstrated normal luminal chyme and stool consistency respectively. No obstructive or overt infiltrative disease was noted. No associated abnormal lymphatic activity was noted.

Pancreas

The **pancreas** revealed mild heterogenous parenchymal changes consistent with remodeling and likely a past history of pancreatitis.

ULTRASONOGRAPHIC FINDINGS

- Minor pancreatic remodeling with overt evidence of inflammation. Low-grade inflammation is possible, however, would be subtle.
- Age-related renal changes with slight pinpoint mineralization
- Age-related hepatic changes

INTERPRETATION OF THE FINDINGS & FURTHER RECOMMENDATIONS

No evidence of significant disease. Underlying food intolerance, dietary indiscretion, occult parasitism, helicobacter are all potentials in this patient. Diet change to hydrolyzed diet may be effective. A clinical trial for helicobacter could also be considered if nonresponsive.

Helicobacter/Gastritis protocol

A clinical trial of **Zithromax (*Dogs:*** 5-10 mg/kg p.o. q24h. May increase dosing interval to q48h after 3-5 days of treatment)**, Metronidazole** (10-20 mg/kg p.o. b.i.d.), **Pepcid** (0.5-1 mg/kg s.i.d.) and **Sucralfate** (0.5-2 g/dog PO) or **Omeprazole** (1 mg/kg p.o. s.i.d.) over the next 3 weeks along with a **novel-protein or hydrolyzed diet** with slurry feeding b.i.d./t.i.d. over the next 2-4 days and then increase to canned diet bid. Dry food should be avoided over the next 4 weeks. A recheck sonogram to assess GI improvement or progression would be ideal in 4 weeks.

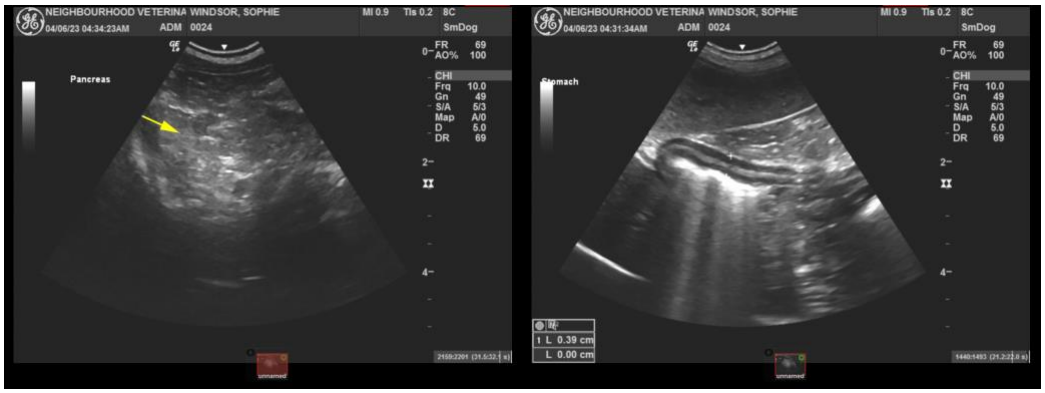

SonoPath

Clinical Sonography & Telecytology

EDUCATIONAL TELECONSULTATION SERVICES™

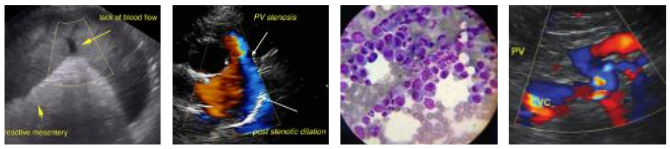

SonoPath.com™
1-800-838-4268 info@sonopath.com

PATIENT

Sophie Windsor

SPECIES

Canine

BREED

Chihuahua

SEX

Spayed Female

AGE

12 Years

WEIGHT

4.38 kg

INTERPRETED BY

Eric Lindquist, DMV

DABVP, Cert. IVUSS

IMAGING PERFORMED BY

Dr. Colborne

HOSPITAL NAME

Neighbourhood VH

REFERRING VET

Dr. Colborne

INVOICE

21989

DATE

4/14/23

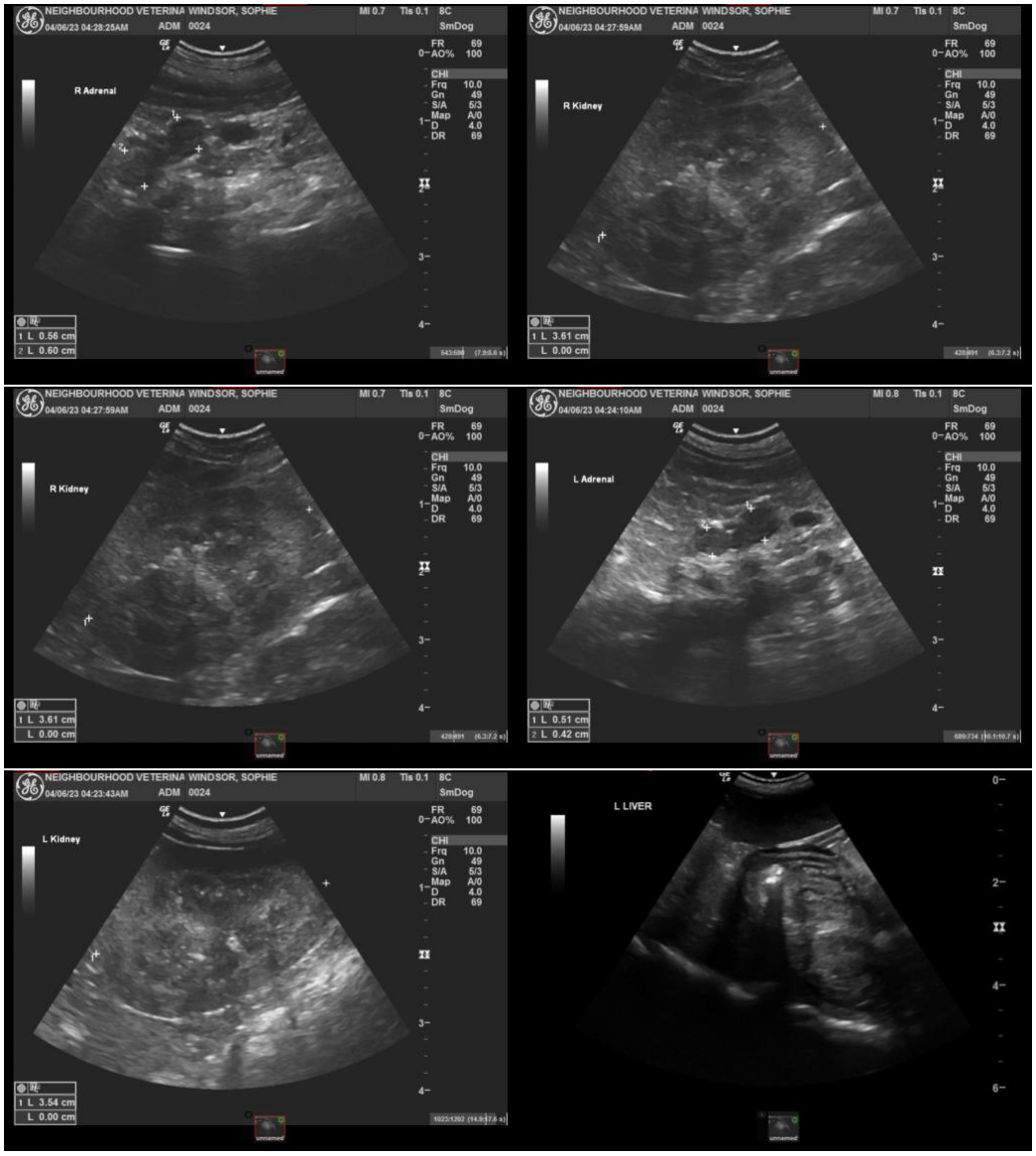

The information and recommendations provided are based on the images presented by the referring veterinarian/sonographer. No evaluation can be communicated regarding pathology that was not visible in the image/video clips provided.

Thank you for this referral. If the clinical or image interpretation does not parallel your findings or if I can be of any further assistance please contact me.

Eric Lindquist, DMV, DABVP, Cert. IVUSS, CEO of SonoPath.com

info@SonoPath.com