



PATIENT

Millie Bittinger

SPECIES

Canine

BREED

Dachshund

SEX

Spayed Female

AGE

9 Years 7 Months

WEIGHT

17.6 Pounds

INTERPRETED BY

Eric Lindquist, DMV

DABVP, Cert. IVUSS

IMAGING PERFORMED BY

Dr. Alex McFeely

HOSPITAL NAME

Straley Vet Associates

REFERRING VET

Dr. Alex McFeely

INVOICE

46709

DATE

4/14/23

PRESENTING CLINICAL SIGNS

Mille's cardiac murmur was found during an exam 2 weeks ago. The intensity was graded 4/6. She has no history of cough or dyspnea but may have had a syncopal episode during administration of an enema at the ER vet clinic. She is currently taking prednisolone and metronidazole for a GI issue. She was given 1.6mg butorphanol IV to lightly sedate for her cardiac u/s today. Her BP was normal, ranging from 148/72 (128) to 150/89 (104) mmHg systolic/ diastolic (MAP).

ULTRASONOGRAPHIC EXAMINATION OF THE HEART

CANINE CARDIAC PARAMETERS	MR VMAX (m/s)	TR VMAX (m/s)	LA/AO (Boon method)	LA/AO (Heart Base; Swe)	FS (%)	EF (%)	EPSS (cm)
NORMAL PARAMETER	4.5-5.5	<2.7	1.3	<1.6	28-40	40-100	<0.6
PATIENT			1.1	1.5	45	90	0.1
CANINE CARDIAC PARAMETERS	HR (BPM)	AV VMAX (m/s)	PV MAX (m/s)	BODY WEIGHT (kg)	LA 2D short axis Base view (cm)	LVIDd Avg; 2D and m-mode short axis (cm)	LVIDs Avg; 2D and m-mode short axis (cm)
NORMAL PARAMETER	50-100	0.7-1.7	0.7-1.6	BELOW	BELOW	BELOW	BELOW
PATIENT	--	1.5	0.7		3.38	3.5	

Cardiac Presentation

The echocardiogram in this patient demonstrated normal **left atrial** size based on 3 different LA measurement methods. Chamber volumes and echogenicity were normal. The cranial and caudal **mitral** valve leaflets presented vegetative thickening consistent with endocardiosis. Doppler indicated measurable insufficiency. The **left ventricle** presented thicknesses with linear contour and was not dilated nor restricted. The **myocardium** presented normal echogenicity without subjective evidence of significant fibrotic or ischemic disease. **Contractility** of the ventricular walls was adequate and in normal range for this patient evidenced by the fractional shortening measurement and subjective evaluation of the different regions of the myocardium. The **left ventricular outflow** tract demonstrated normal laminar flow and subjective structural integrity. The **right atrium** and auricle revealed normal size, structure and content. No evidence of masses was noted or chamber overload. **Tricuspid** valvular assessment demonstrated adequate linear morphology. The **right ventricle** was of normal size (1/3 diameter of LV), chordae structure, myocardial echogenicity and thickness. **Pulmonic** tract assessment revealed normal valve structure, laminar flow, and diameter (approx. 1:1 pa/ao ratio). No visible **pericardial** or free pleura fluid was noted. No echographically detectable evidence of infiltrative disease was visible. The cranial **mediastinum** and **pericardial** regions were free of masses in the visible window. Periodic arrhythmia noted during the exam.

ULTRASONOGRAPHIC FINDINGS

- Stage B1 valvular disease



PATIENT

Millie Bittinger

SPECIES

Canine

BREED

Dachshund

SEX

Spayed Female

AGE

9 Years 7 Months

WEIGHT

17.6 Pounds

INTERPRETED BY

Eric Lindquist, DMV

DABVP, Cert. IVUSS

IMAGING PERFORMED BY

Dr. Alex McFeely

HOSPITAL NAME

Straley Vet Associates

REFERRING VET

Dr. Alex McFeely

INVOICE

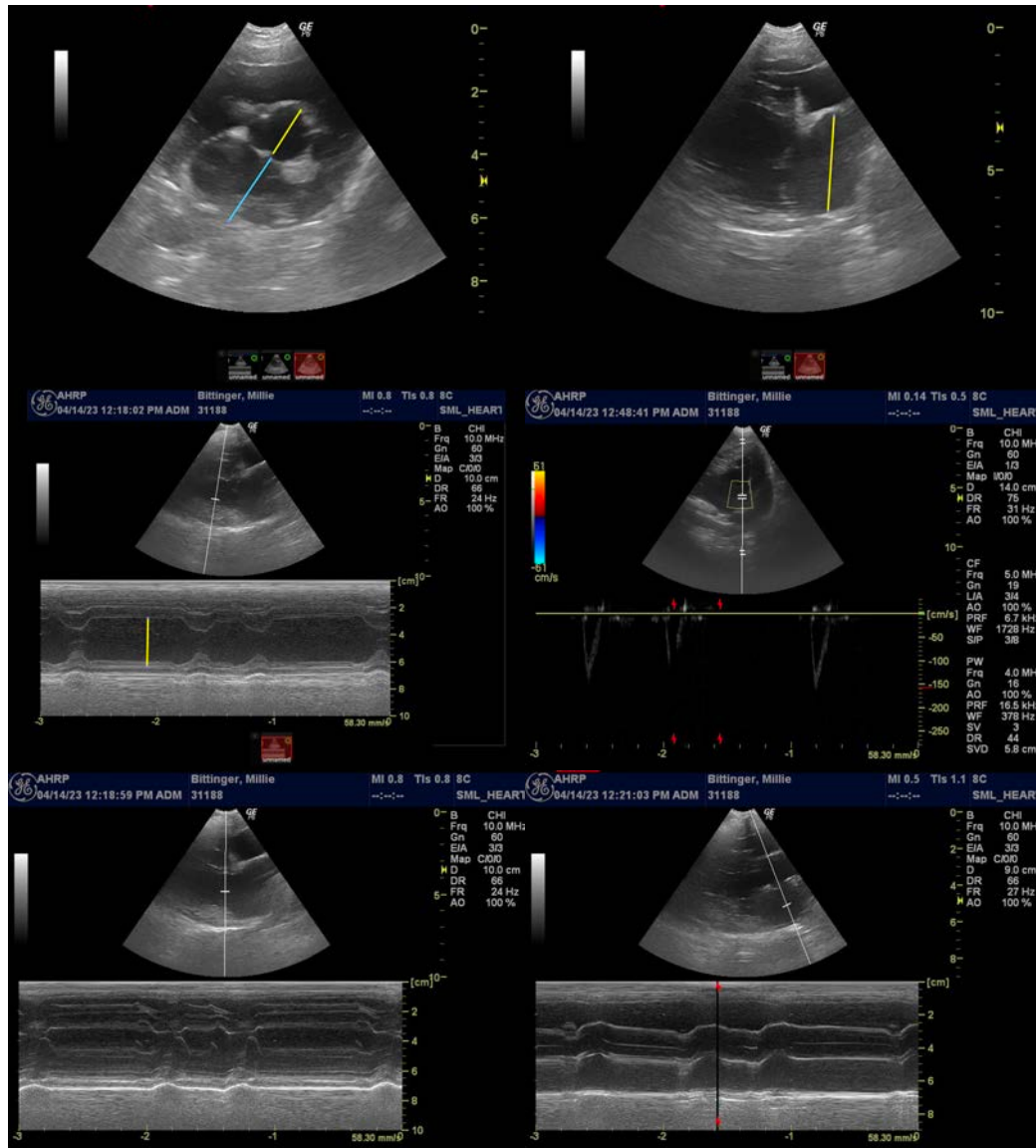
46709

DATE

4/14/23

INTERPRETATION OF THE FINDINGS & FURTHER RECOMMENDATIONS

No evidence of volume overload. The heart is stable without clinical disease. No overt contraindication for anesthesia of brief to moderate duration. I suggest Torbutrol premed, Propofol induction, Isoflor maintenance or similar protocol if anesthesia is desired. Blood pressure recommended if not already performed and target white coat negative systolic pressure of < 160 mmHg. If higher than this ACE-inhibitor is suggested to reach this level. Recheck echocardiogram is recommended in 6 months, earlier if murmur grade increases or clinical signs initiate.





PATIENT

Millie Bittinger

SPECIES

Canine

BREED

Dachshund

SEX

Spayed Female

AGE

9 Years 7 Months

WEIGHT

17.6 Pounds

INTERPRETED BY

Eric Lindquist, DMV

DABVP, Cert. IVUSS

IMAGING PERFORMED BY

Dr. Alex McFeely

HOSPITAL NAME

Straley Vet Associates

REFERRING VET

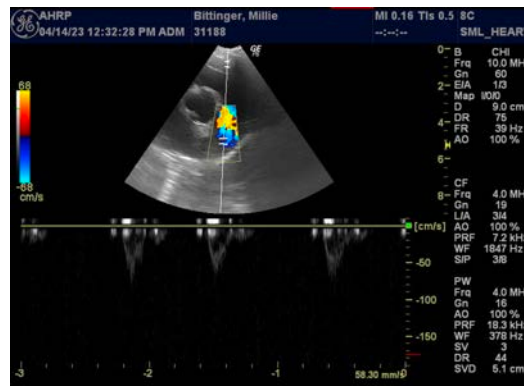
Dr. Alex McFeely

INVOICE

46709

DATE

4/14/23



The information and recommendations provided are based on the images presented by the referring veterinarian/sonographer. No evaluation can be communicated regarding pathology that was not visible in the image/video clips provided.

Thank you for this referral. If the clinical or image interpretation does not parallel your findings or if I can be of any further assistance please contact me.

Eric Lindquist, DMV, DABVP, Cert. IVUSS, CEO of SonoPath.com

info@SonoPath.com