



PATIENT

Leo Stevens

PRESENTING CLINICAL SIGNS

History: Vomiting, lethargy, suspicious of fb on xray

SPECIES

Feline

ULTRASONOGRAPHIC EXAMINATION OF THE ABDOMEN

Urinary System

The **urinary bladder**, trigone, and pelvic urethra presented normal thicknesses and normal tone. The ureters were not visible which is normal. No uroliths or sediment were visualized and anechoic urine was present. No evidence of inflammatory or neoplastic changes were noted. Ureteral papillae were normal.

BREED

Bengal

SEX

Neutered Male

The **kidneys** revealed normal size and structure, corticomedullary definition and ratio for this age. The cortices presented largely uniform texture with normal echogenic relationship to liver and spleen. Medullary structure differed distinctly from the cortex and no evidence of pelvic dilation was present. The capsules were acceptably uniform without significant irregularities. The left kidney measured 4.5 cm. The right kidney measured 4.78 cm.

AGE

5 Years

Adrenal Glands

Both **adrenal glands** were visualized and recognized as having normal shape, size, position and echogenicity for this breed. The phrenic vasculature, glandular echogenicity and detail were unremarkable. Capsule, cortex, and medullary definition were normal for this age patient. The left adrenal gland measured 0.45 cm. The right adrenal gland measured 0.27 cm.

WEIGHT

16.85

Spleen

The **spleen** presented a smooth homogeneous parenchyma hyperechoic to liver and renal cortical parenchyma. The capsule was smooth without noticeable expansion or deviation from within the spleen or adjacent pathology. The splenic vasculature demonstrated normal volume without signs of congestion or thrombosis. No sonographic evidence of acute or chronic inflammatory, neoplastic, or infarctual changes were noted.

INTERPRETED BY

Eric Lindquist, DMV
DABVP, Cert. IVUSS

IMAGING PERFORMED BY

Val Shumskaya

Liver

The **liver** images submitted revealed subjectively normal liver size, contour, and structure. Parenchymal echogenicity was naturally coarse and hypoechoic to the spleen. Vascular and biliary tracts were of normal volume with no evidence of congestion. The gallbladder presented acceptably thin walls with primarily anechoic content. The cystic and common bile ducts were normal. No pathological hepatic lymphadenopathy was evident. No overt structural evidence of inflammatory, infiltrative or regenerative pathology was evident.

HOSPITAL NAME

Vet Wellness Center

REFERRING VET

Dr. Sepulveda

Gastrointestinal

The **stomach** revealed progressively shadowing material, consistent with hairball-type density. The small intestine revealed minor fluid filled bowel and hyperperistalsis without evidence of obstruction. The cecum was mildly dilated with fluid. The descending colon was unremarkable with normal stool consistency.

INVOICE

21977

Pancreas

DATE

4/14/23



PATIENT

Leo Stevens

The base and limbs of the **pancreas** were observed to be largely isoechoic to surrounding omental fat. Pancreatic duct and capsular contour were acceptably normal and parenchyma respected normal curvilinear patterns. No overt evidence of active inflammatory or neoplastic disease was noted.

SPECIES

Feline

ULTRASONOGRAPHIC FINDINGS

- Hairball density in the stomach and enteritis pattern- no overt foreign matter or obstruction, however, the patient may be passing portions of hairball periodically.

BREED

Bengal

INTERPRETATION OF THE FINDINGS & FURTHER RECOMMENDATIONS

Medical management for hairballs and consideration for parasitic disease, enterotoxins, dietary intolerance are all indicated. A combination of likely hairball accumulation and enteritis would most likely justify this presentation. Recheck sonogram in 2-3 weeks as long as the patient is improving on medical management, or early if clinical signs exacerbate.

SEX

Neutered Male

AGE

5 Years

WEIGHT

16.85

INTERPRETED BY

Eric Lindquist, DMV
DABVP, Cert. IVUSS

IMAGING PERFORMED BY

Val Shumskaya

HOSPITAL NAME

Vet Wellness Center

REFERRING VET

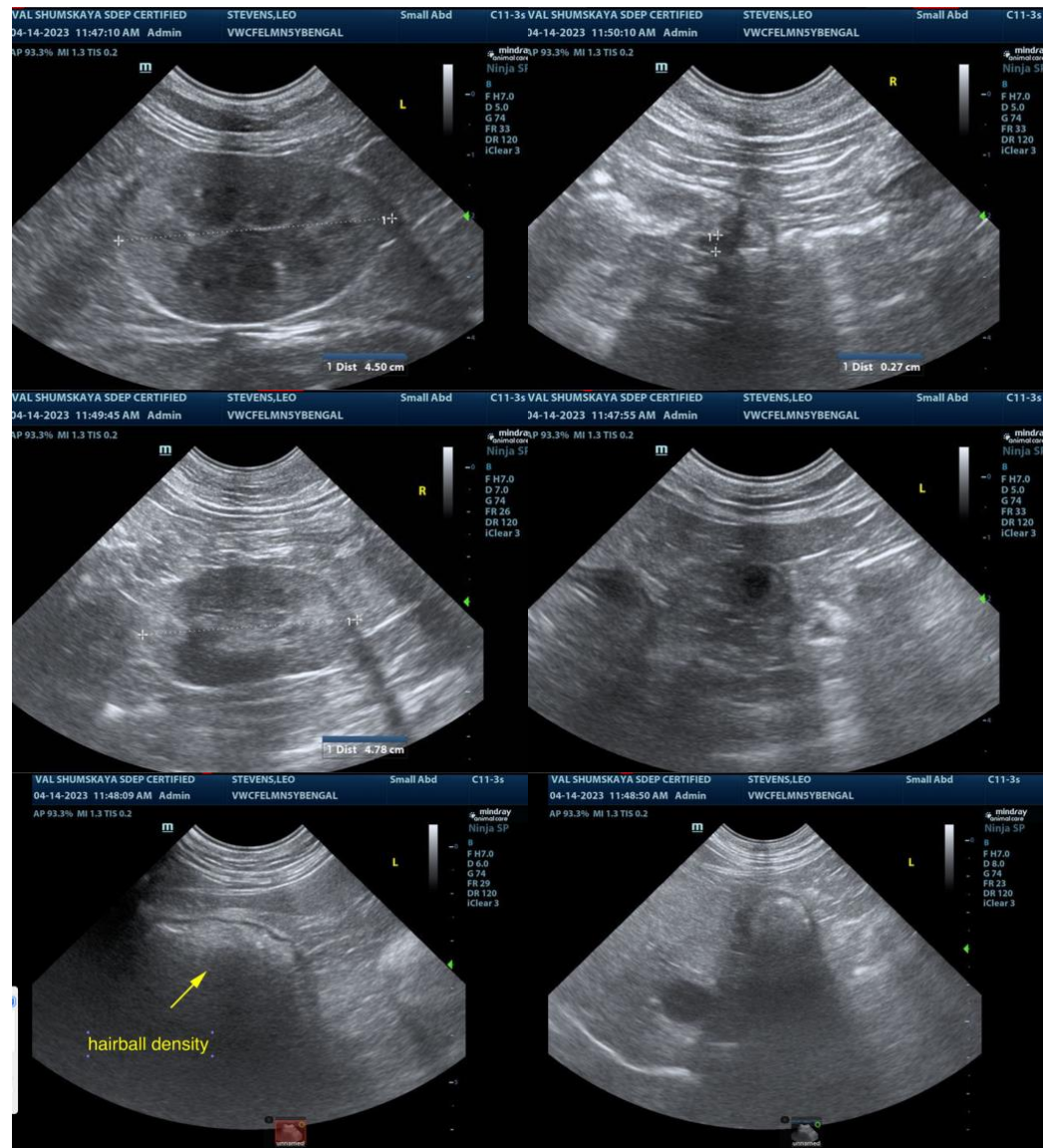
Dr. Sepulveda

INVOICE

21977

DATE

4/14/23





PATIENT

Leo Stevens

SPECIES

Feline

BREED

Bengal

SEX

Neutered Male

AGE

5 Years

WEIGHT

16.85

INTERPRETED BY

Eric Lindquist, DMV
DABVP, Cert. IVUSS

IMAGING PERFORMED BY

Val Shumskaya

HOSPITAL NAME

Vet Wellness Center

REFERRING VET

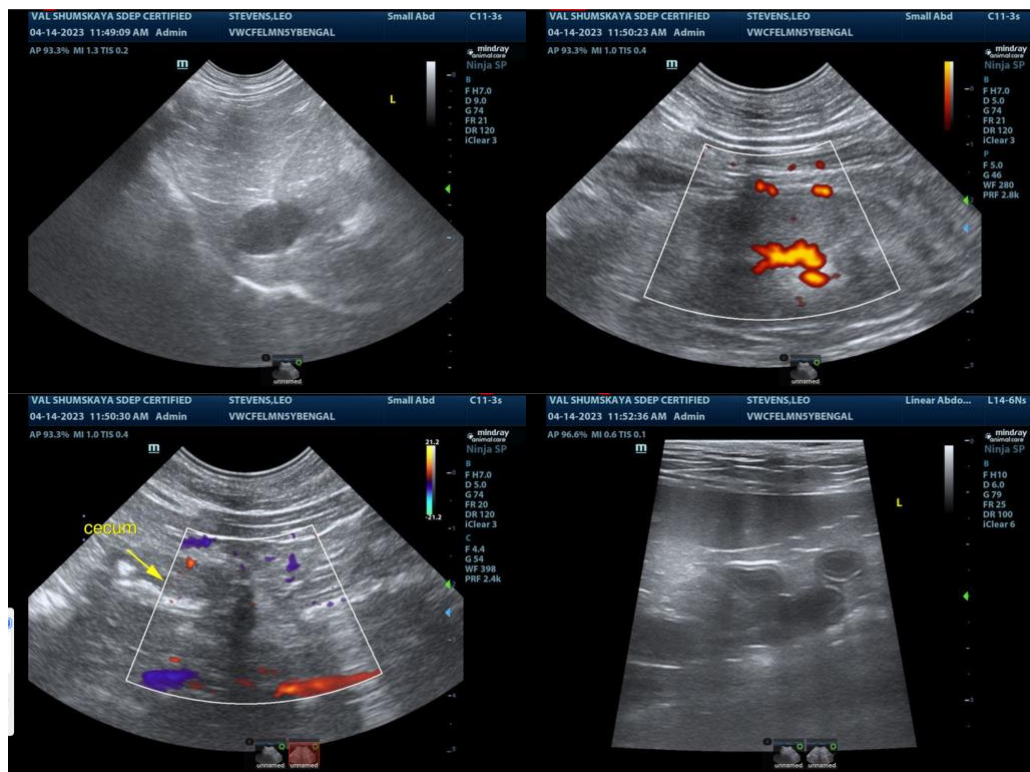
Dr. Sepulveda

INVOICE

21977

DATE

4/14/23



The information and recommendations provided are based on the images presented by the referring veterinarian. No evaluation can be communicated regarding pathology that was not visible in the image/video clips provided.

Thank you for this referral. If the clinical or image interpretation does not parallel your findings or if I can be of any further assistance please contact me.

Eric Lindquist, DMV, DABVP, Cert. IVUSS, CEO of SonoPath.com
info@SonoPath.com